



**UNIVERSITY**  
*of*  
**GLASGOW**

**James Ireland  
Memorial Library**



30114011945485

Dent BL  
Archives

Glasgow University Library


ALL ITEMS ARE ISSUED SUBJECT TO RECALL

GUL 96.18







# A PRACTICAL TREATISE

ON

## ARTIFICIAL CROWN- AND BRIDGE-WORK.

BY

GEORGE EVANS,

LECTURER ON CROWN- AND BRIDGE-WORK IN THE BALTIMORE COLLEGE OF DENTAL SURGERY ;  
MEMBER OF THE AMERICAN DENTAL ASSOCIATION ; OF THE SOUTHERN DENTAL ASSO-  
CIATION ; OF THE DENTAL SOCIETY OF THE STATE OF NEW YORK ; OF THE FIRST  
DISTRICT DENTAL SOCIETY OF THE STATE OF NEW YORK ; HONORARY  
MEMBER OF THE MARYLAND STATE DENTAL ASSOCIATION, ETC.

FIFTH EDITION, REVISED.

---

WITH 625 ILLUSTRATIONS.

---

PHILADELPHIA :  
THE S. S. WHITE DENTAL MFG. CO.  
1896.

---

Copyright, 1888, by GEORGE EVANS.  
Copyright, 1889, by GEORGE EVANS.  
Copyright, 1893, by GEORGE EVANS.  
Copyright, 1893, by GEORGE EVANS.  
Copyright, 1896, by GEORGE EVANS.

---



*To the Members  
of the  
First District Dental Society of the State of New York,  
this Book is respectfully dedicated  
by  
THE AUTHOR.*



## PREFACE TO THE FIFTH EDITION.

---

IN the present edition of "Artificial Crown- and Bridge-Work," as in those which have preceded it, the aim of the author has been to supply, first of all, a practical treatise, which should serve as a text-book for college and post-graduate study and as a reference book for the practitioner. The endeavor, therefore, has been to make it comprehensive in its scope, liberal and impartial in its treatment of the various subjects presented, concise in its statement of the principles involved, clear in its description of methods of practice.

Crown- and bridge-work has been accorded high rank as a specialty of dentistry. It affords extraordinary prosthetic advantages over other methods in its application to special cases. The results achieved through the correct practice of crown- and bridge-work have demonstrated its practical utility, which, with its esthetic possibilities, has gradually forced its recognition by practical men. Its failures are now seen to be largely due, as in other branches, to lack of judgment in the application of principles or to unskillfulness in their adaptation to the case in hand.

With the passing of the years the principles which underlie the correct practice of crown- and bridge-work have become more clearly established, the methods for their practical demonstration more sharply defined. Much that played its part in the formative stage of the art has been superseded; crude methods have been replaced by more refined, more direct, more effective means for attaining the end. In revising this work every effort has been made to bring it abreast of the advances

made. In order that the presentation may be comprehensive without being bulky, obsolete matters have been omitted, descriptions of unimportant variations have been curtailed, repetitions avoided as far as possible, and an endeavor made to treat the various phases of crown- and bridge-work concisely, but never sacrificing clearness for brevity.

The author hopes that his present effort to advance and elevate this branch of dentistry may meet with a continuation of the generous acknowledgment accorded to previous editions.

GEORGE EVANS.

49 W. 39TH ST., NEW YORK,  
December, 1896.

# CONTENTS.

	PAGE
INTRODUCTION.....	1
ARTIFICIAL CROWN- AND BRIDGE-WORK.....	5

## PART I.

### PREPARATORY TREATMENT OF TEETH AND ROOTS FOR CROWN-WORK.

#### CHAPTER I.

THE PULPS OF TEETH—THEIR PRESERVATION OR DEVITALIZATION—PULP-CAPPING.....	10
---	----

#### CHAPTER II.

DEVITALIZATION OF THE PULP.....	16
---------------------------------	----

#### CHAPTER III.

PULPLESS TEETH—PREPARATION OF ROOT-CANALS—THEIR TREATMENT, DISINFECTION, AND FILLING.....	21
---	----

#### CHAPTER IV.

CHRONIC ALVEOLAR ABSCESS.....	31
-------------------------------	----

#### CHAPTER V.

SHAPING TEETH AND ROOTS FOR CROWN-WORK.....	36
---	----

## PART II.

### ARTIFICIAL CROWN-WORK.

#### THE PORCELAIN SYSTEM.

#### CHAPTER I.

PORCELAIN CROWNS.....	44
The Gates-Bonwill Crown.....	45
The Foster Crown.....	49
The Howland-Perry Crown.....	50
The Logan and Brown Crowns.....	50
Remarks on the Use of Porcelain Crowns and Crowns without Collars...	58

## CHAPTER II.

	PAGE
PORCELAIN CROWNS WITH GOLD COLLAR ATTACHMENT.....	59
Method of Mounting a Logan Crown with a Band and Cap.....	60

## CHAPTER III.

PORCELAIN CROWNS WITH RUBBER OR VULCANITE ATTACHMENT.....	66
---	----

## THE GOLD SYSTEM.

## CHAPTER IV.

GOLD COLLAR CROWNS.....	67
The Construction and Adaptation of Collars.....	67

## CHAPTER V.

GOLD COLLAR CROWNS WITH PORCELAIN FRONTS.....	74
Incisors and Cuspids.....	74
Bicuspid and Molars.....	77

## CHAPTER VI.

ALL-GOLD COLLAR CROWNS FOR BICUSPIDS AND MOLARS CONSTRUCTED IN SECTIONS.....	81
---	----

## CHAPTER VII.

THE GOLD SEAMLESS CAP CROWN.....	90
Incisors, Cuspids, and Bicuspid, with Porcelain Fronts.....	90
All-Gold Seamless Bicuspid and Molars.....	92

## CHAPTER VIII.

GOLD SEAMLESS CONTOUR CROWNS.....	96
Adjustment of Seamless Contour Crowns.....	99

## CHAPTER IX.

GOLD CROWNS WITH PORCELAIN FRONTS FOR TEETH WITH LIVING PULPS	107
Collar Crowns Hygienically Considered.....	111

## CHAPTER X.

SPECIAL FORMS OF GOLD CROWNS WITH PORCELAIN FRONTS.....	112
Porcelain and Gold Crown without a Collar.....	112
Mounting the Porcelain Front.....	115
The Parr Crown.....	117
The Leech Crown.....	118
The Perry Crown.....	119

CHAPTER XI.

	PAGE
CROWNING FRACTURED TEETH AND ROOTS—CROWNING MOLAR ROOTS DECAYED APART AT BIFURCATION—CROWNING IN CASES OF IRREGU- LARITY.....	120
Longitudinal Fracture of the Crown and Root.....	120
Fracture of the Crown with Slanting Fracture of the Root.....	121
Perforation of a Side-Wall of a Root-canal or of the Dentine at the Bifurcation of the Roots.....	122
Crowning Molar Roots decayed apart at the Bifurcation.....	123
Dr Farrar's Cantilever Crown.....	123
Methods of Crowning in Cases of Irregularity.....	124

CHAPTER XII.

PARTIAL CROWNS.....	125
---------------------	-----

CHAPTER XIII.

FINISHING AND POLISHING—PROCESS OF CEMENTATION.....	133
Finishing and Polishing Crown-Work.....	133
Insertion and Cementation.....	133
Oxyphosphate of Zinc.....	133
Gutta-Percha.....	137
Amalgam.....	139

PART III.

BRIDGE-WORK.

CHAPTER I.

CONSTRUCTION OF BRIDGE-WORK.....	148
----------------------------------	-----

CHAPTER II.

SPECIAL PROCESSES AND APPLIANCES IN BRIDGE-WORK.....	162
--	-----

CHAPTER III.

EXTENSION BRIDGES.....	170
------------------------	-----

CHAPTER IV.

BAR BRIDGES.....	175
------------------	-----

CHAPTER V.

PARTIAL CAP AND PIN BRIDGE.....	180
---------------------------------	-----

CHAPTER VI.

REMOVABLE AND REPLACEABLE PORCELAIN FRONTS.....	183
---	-----

CHAPTER VII.

	PAGE
GENERAL APPLICATION OF CROWN- AND BRIDGE-WORK.....	187
Extensive Applications of Crown- and Bridge-Work.....	197

CHAPTER VIII.

REPAIR OF CROWN- OR BRIDGE-WORK.....	205
--------------------------------------	-----

CHAPTER IX.

THE HYGIENIC CONDITION OF THE MOUTH AS AFFECTED BY BRIDGE-WORK	210
--	-----

CHAPTER X.

REMOVABLE AND DETACHABLE BRIDGE-WORK.....	212
Removable Ineisor or Cuspid Crown.....	213
Removable Bieuspid and Molar Attachments.....	216

CHAPTER XI.

REMOVABLE PLATE BRIDGES.....	230
------------------------------	-----

CHAPTER XII.

SPECIAL FORMS OF DETACHABLE AND REMOVABLE BRIDGE-WORK.....	243
Dr. Winder's Sectional Crown Method.....	243
Dr. Litch's Method.....	246
Dr. R. W. Starr's Methods.....	248
Dr. Parr's Methods.....	254
Dr. Waters's Methods.....	260
Dr. Bonwill's Method.....	264

CHAPTER XIII.

REMOVABLE BAR-BRIDGES.....	267
----------------------------	-----

CHAPTER XIV.

DR. KNAPP'S METHODS.....	273
--------------------------	-----

CHAPTER XV.

THE MANDREL SYSTEM.....	278
-------------------------	-----

CHAPTER XVI.

THE HOLLINGSWORTH SYSTEM.....	285
To Make a Gold Crown (Bieuspid or Molar).....	285
To Make Solid Gold Cusps.....	288
To Make Gold Crowns (Centrals, Laterals, and Cuspids).....	289
To Insert a Poreelain Facing.....	291
To Make the Grinding-Surface of a Bridge in One Continuous Piece.....	292
Faeings for Making All-Gold Bridge.....	294



CHAPTER XVII.

	PAGE
PORCELAIN BRIDGE-WORK.....	295
Dr. E. Parmly Brown's Method.....	295

CHAPTER XVIII.

CROWN- AND BRIDGE-WORK COMBINED WITH OPERATIVE DENTISTRY IN DENTAL PROSTHESIS.....	305
---	-----

PART IV.

MATERIALS AND PROCESSES USED IN CROWN- AND BRIDGE-WORK.

CHAPTER I.

PLATES AND SOLDERS.....	319
-------------------------	-----

CHAPTER II.

PORCELAIN TEETH.....	323
----------------------	-----

CHAPTER III.

MOLDS AND DIES.....	324
How to Quickly Make a Tube and Fusible Metal Die.....	324

CHAPTER IV.

SOLDERING.....	326
----------------	-----

CHAPTER V.

INSTRUMENTS AND APPLIANCES.....	328
---------------------------------	-----

INDEX.....	331
------------	-----



## INTRODUCTION.

---

OF the origin of the art of dentistry no one can speak with certainty, as its early history is shrouded in the mists of antiquity; but dental operations are recorded in very remote times.

References are made to the art in the writings of Hippocrates, in the fifth century B.C. Martial, the Latin poet, in the first century B.C., says that a Roman dentist "Cascellius is in the habit of fastening as well as extracting the teeth." To Lelius he says, "You are not ashamed to purchase teeth and hair;" and adds that "the toothless mouth of Egle was repaired with bone and ivory;" also, that "Galla, more refined, removed her artificial teeth during the night."

Horace, in the same century, cites the case of the "sorceresses Canidia and Sagana running through the city and losing the one her false hair, the other her false teeth."

Galen, the celebrated physician, in the second century A.D., also speaks of the art of dentistry as being then practiced.

These early operations were limited to the extraction of offending teeth and the replacement of those which had been lost with substitutes which were retained in position by means of narrow bands or ligatures attaching them to the adjoining natural teeth, and without the use of plates. Crude as they were, they formed the first expression of the art of dentistry, a beneficent art from the beginning, in that it sought to restore pathological or accidental defects. Confined to the simplest operations, it existed for centuries, and then was apparently

lost during the Dark Ages, to reappear when the more general diffusion of knowledge ushered in the modern era of science and invention.

After its revival, dentistry, so much of it as was known, was in a measure a secret art, the practice of which even within the memory of men now living, and they not the oldest, was involved in mystery; but recent progress has lifted the veil, and dentistry, in the treatment of the teeth on correct, scientific, rational principles, has developed an art and a science which have given it honorable rank among the professions. In its twofold evolution it has absorbed from every available source whatever would broaden its science or perfect its art. It calls to its aid anatomy, physiology, pathology, chemistry, therapeutics, metallurgy, sculpture, and mechanics, with each of which it stands in closer or more remote relation; and the practitioners of dentistry who have become the most eminent and useful have been men of broad attainments and great versatility of talent.

In the history of all progress, movements apparently of a more or less reactionary character are recorded. In the useful arts especially it is not uncommon to find a return to forms and methods formerly used, but long since discarded and forgotten. So in dentistry we find methods of treatment and modes of practice once in vogue but long fallen into disuse, revived with improvements and modifications that stamp them as practically rediscoveries.

These movements are not to be regarded as retrogressive, because the modifications which accompany the reintroduction of practical ideas and inventions attest them as real advances, and indicate clearly that the cycle of knowledge is ever widening with experience. This volume demonstrates how modern dentistry has utilized the principles of some of the simplest original operations, and by "proving all things, holding fast that

which is good," has attained its present honorable position in both its scientific and artistic departments.

The history of dentistry of later years is, in brief, a recital of progress and improvement. The medical profession has officially recognized it as closely allied to medicine by inviting its representatives to take part in the International Medical Congresses on the footing of professional equality.

Such is the position which dentistry has attained. Much of the progress which has made its present elevation possible must be credited to the dental profession of the United States, which has been justly termed the cradle of modern dentistry. Here the validity of the idea that scientific knowledge should form the basis of training for practice was first demonstrated by the successful establishment of dental schools; here the first journal for the interchange among dentists of thought and experience was founded; here the first association having for its object the uplifting and upholding of dentistry by the mutual helpfulness of its practitioners had its origin; here, in a word, dentistry was first divorced from mystery, here it first passed the narrow confines of a mere handicraft and earned for itself the right to be classed among the learned and liberal professions.



*J. Campbell McBrindle*  
*1897.*

## ARTIFICIAL CROWN- AND BRIDGE-WORK.

---

MODERN artificial crown- and bridge-work belongs to the department of dentistry until recently termed "mechanical;" but the judgment, skill, and scientific information required place it far above ordinary mechanical dentistry, which has sunk to a low estate since the introduction of vulcanite. To such an extent has vulcanite, by reason of its cheapness and ease of manipulation, superseded other materials demanding greater knowledge and skill in their manipulation, as to retard the higher development of prosthetic dentistry, and indeed to divest it, in the hands of those who depend upon vulcanite, of the dignity which should belong to dentistry as a profession.

But modern crown- and bridge-work, properly understood and properly performed, takes high rank in dental art, and offers wide scope for versatility of talent and inventive genius. The varied and complicated cases presenting for treatment frequently suggest to the expert novel contrivances and methods of construction and application. Successful practice of crown- and bridge-work depends upon a thorough mastery of the underlying principles, and expertness in the processes involved, governed by sound judgment and perfect candor. The interests of the patient should be paramount to every other consideration, and after a careful examination he should be given an accurate statement of the applicability of the system to his case, in respect to usefulness, appearance, durability, and comfort, as compared with other processes and appliances in use.

Surgical and mechanical operations of the most delicate nature are required. Nothing, indeed, in dentistry demands finer manipulation. A practical consideration of the subject will show that a knowledge of anatomy, pathology, and therapeutics, and as well mechanical and artistic skill, are necessary to the correct treatment of cases and the proper performance of the operations indicated. Among the principal steps in an operation may be named, first, the preparatory treatment of the natural roots and teeth for the final process, involving the diagnosis of present or probable lesions and the prescription of whatever remedial or prophylactic measures may be needful; second, in crown-work, the adaptation of the artificial crowns to the cervical portion of the natural roots and the contiguous membranes, and the restoration of the articulation and the anatomical contour; and, in bridge-work, the selection of suitable teeth or roots for foundation piers or abutments, and the choice and adaptation in constructive practice of the forms which will insure the highest degree of stability and best sustain the force of occlusion, thereby avoiding abnormal positions and conditions.

The practice of crown- and bridge-work by dentists possessing the requisite attainments and governed by correct ethical principles gives results which are gradually establishing its value, removing erroneous impressions, and insuring a wide professional and public indorsement of this important branch of prosthetic dentistry. Its extraordinary facilities for preserving and replacing teeth are making for it the position in dental art which it merits.



PART I.

---

PREPARATORY TREATMENT OF TEETH AND ROOTS FOR  
CROWN-WORK.



## PREPARATORY TREATMENT OF TEETH AND ROOTS FOR CROWN-WORK.

PREPARATORY treatment of teeth and roots for crown-work includes, in addition to the shaping required to fit them for the reception of the crowns, the bringing about of the healthiest possible condition in the teeth and roots and the adjacent parts, as the cure of existing lesions, the removal of calculus where necessary, and the adoption of such measures as shall prevent the recurrence of old troubles or the inception of new.

Notwithstanding all that advanced knowledge of therapeutical agents and skill in their use permit, there are many teeth and roots which cannot be rendered suitable for the successful application of crown- or bridge-work. Roots which are permeated and softened by decay, exposed or loosened from absorption of the gums and alveoli, or affected with irremediable disease of the investing membranes, should be thus classed. Cases in which abscess with necrosis has extensively impaired the walls of the alveoli are equally intractable.

Experience shows that the results in this department of dentistry depend largely upon diathesis or constitutional tendency and upon the attention given to the preservation of the health of the mouth; and these conditions should be carefully estimated in the selection of a system of treatment and the method of its application.

## CHAPTER I.

### THE PULPS OF TEETH—THEIR PRESERVATION OR DEVITALIZATION—PULP-CAPPING.

THE preservation of the vitality of the pulps of the teeth is a matter of as much importance in connection with crown- and bridge-work as in any other class of operations, though the excision of natural crowns for the purpose of utilizing the roots as abutments for bridge-work is extensively practiced, and is defended by some on the theory that the vitality of the dentine is to some extent maintained by the cementum after the extirpation of the pulp, and by others on the plea that the pulp is of little value when root-canal treatment is properly conducted.<sup>1</sup>

Dr. C. F. W. Bödecker, discussing the subject of the "Distribution of Living Matter in Human Dentine," says,<sup>2</sup>—

---

<sup>1</sup> Dr. J. L. Williams says, "The life and vitality of the cementum remain intact and uninjured, and even the dentine may, and undoubtedly does, retain a certain amount of vitality, for something analogous to a healing process takes place at the ends of the broken fibrillæ next to the pulp-chamber, and by one of those wonderful provisional conditions which we so often meet with in the economy of the animal kingdom nature reverses or changes the origin of nutritive supply, and the material for maintaining the continued vitality of the dentine comes through the cementum."

He further says, "Every practicing dentist has observed that a tooth which is removed from contact with the fluids of the mouth changes color. This change in color is largely the result of the evaporation of the water from the organic portion of the tooth. Now, if the apical foramen of such a tooth be closed, and the tooth be then placed in water, or preferably, glycerin and water, in a short time it will regain nearly its original color, and at the same time it will be found that it has increased in weight. This means, of course, that the entire tooth has absorbed from the surface a certain quantity of the fluid, and this fluid has penetrated every part of the solid structure of the tooth. Will any one doubt, with these facts in view, that when the tooth is in position in the jaw, and surrounded by all the delicate adjustments furnished by nature, there may be a circulation of nutrient fluids throughout the entire root after the removal of the pulp?"

It is difficult to understand how a saturation can be compared to an infiltration controlled by vital circulation.—G. E.

<sup>2</sup> *Dental Cosmos*, vol. xx, page 656.



PLATE I.




PLATE II.

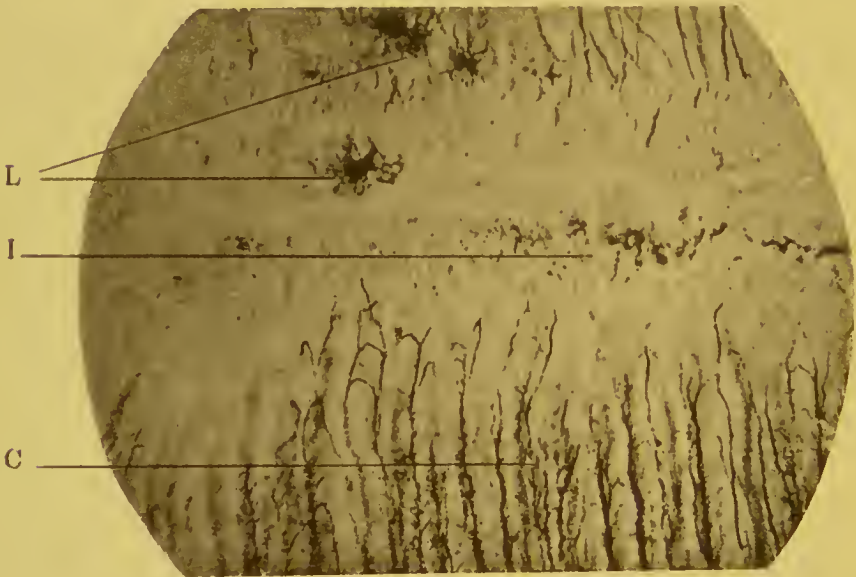



PLATE III.



FROM SPECIMENS MADE BY M. H. FLETCHER, M. D., DENTIST. CINCINNATI, OHIO.

“1st. The dentinal canaliculi are excavations in the basis-substance of the dentine, each containing in its center *a fiber of living matter*. Besides the dentinal canaliculi, there exists an extremely delicate net-work within the basis-substance of the dentine, into which innumerable offshoots of the dentinal fibers pass. Although we cannot trace the living matter throughout the whole net-work in the basis-substance, evidently owing to its delicacy, we are justified in assuming that not only the dentinal canaliculi, but the whole basis-substance of the dentine is also pierced by a delicate net-work of living matter. The living matter of the dentine is in direct union with that of the protoplasmic bodies of the pulp, of the cementum, and of the enamel.

“2d. The cementum, as well as ordinary bone, is provided with lacunæ and canaliculi. The lacunæ contain nucleated protoplasmic bodies, and the canaliculi hold offshoots of the living matter of the protoplasm. The whole basis-substance of the cementum is traversed by a delicate net-work, which in all probability contains living matter, though this is traceable only in its thorn-like projections from the periphery of the protoplasm and its larger offshoots. The living matter of the *cementum is uninterruptedly connected with that of the periosteum, and continuous with that of the dentine, either through intervening protoplasmic bodies in the interzonal layer, or directly with the dentinal fibers.*”

This distribution and relative connection of living matter as described refers to an existing state of perfect vitality of all the parts. When the pulp loses its vitality, an entirely different condition results. The tubuli are then deprived of vital circulation, except along the line of the outer portion of the dentine, where, in the interzonal layer, the fibrillæ anastomose with the living matter of the cementum, the vitality of the latter being maintained through the pericementum. The vitality supported by this anastomosis is almost entirely confined to this part, the nutrient supply being insufficient to assume the functions of the pulp and maintain circulation in the main body of the dentine. (See Plates I, II, III.)<sup>1</sup>

<sup>1</sup> PLATE I.—Longitudinal section of the root of a superior bicuspid, at junction of dentine with cementum. C, cementum; D, dentine; I, interzonal layer; L, lacunæ of cementum. × 175.

Chemical analysis of the dentine shows that the organic matter, consisting principally of the fibrillæ, exists in the proportion of nearly 25 per cent. to 64 per cent. of lime-salts.<sup>1</sup>

When the pulp has been removed, the devitalized fibrillæ still remain, and, unless antiseptic root-canal treatment has been thoroughly carried out, they are capable of generating septic gases which will exert an influence in producing irritation of the cementum and pericementum. An examination of the investing membranes of pulpless teeth generally shows the existence of abnormal conditions, by which their firmness is to some extent impaired, their susceptibility to acute inflammation increased, and their reliability as foundations for crown- or bridge-work greatly lessened when compared with teeth which have living pulps.

In cap crown-work, facilities are afforded for the preservation of pulps in the posterior teeth. Thus, in a case verging on exposure, only partial removal of the decay is usually necessary, as, when the operation is completed, the natural crown will be hermetically inclosed by the artificial one. In bridge-work, proper methods of practice in a large percentage of cases will also permit the anterior teeth to be used as abutments without the extirpation of their pulps or the excision of their crowns.

Extirpation is demanded for those pulps whose permanent preservation cannot be placed beyond doubt, as failure involves more serious consequences in crown- and bridge-work than in filling-operations. The lesions of the pulp which seem to require its extirpation, according to the generally expressed opinion

---

PLATE II.—A field taken from Plate I in position marked A. L, lacunæ of cementum; C, canaliculi of dentine; I, interzonal layer.  $\times 210$ .

PLATE III.—A field taken from Plate I in position marked B. L, L, L, lacunæ of cementum; I, interzonal layer; D, dentinal tubes and their nearest approach to the lacunæ.  $\times 210$ .

A study of these plates demonstrates the limited nature of the anastomosis of the fibers of living matter of the dentine and cementum.

<sup>1</sup> The analysis of dentine by Dr. G. V. Black gives an average of—

Lime-salts . . . . .	63.54
Organic matter . . . . .	25.36
Water . . . . .	11.06

Age slightly lessens the proportion of living matter and increases the percentage of lime-salts.



on the subject, are exposure with hypertrophy or rupture of the pulp-sac, congestion, and pulpitis which does not yield promptly to remedial treatment. Pulps actually exposed by decay are seldom found in a normal condition otherwise, and they are only rarely proper or hopeful subjects for remedial treatment. Atrophy of the *membrana eboris*, or investing membrane, which comprises the layer of odontoblasts, usually exists at the part exposed, and, as any subsequent calcification must depend on the activity of the odontoblasts, it is evident that the existence of the condition referred to affords a strong argument against the advisability of capping pulps in cases of extensive or even slight exposure. The difficulty of securing a condition of asepsis of the exposed and diseased parts so perfect as to assure them against the invasion of micro-organisms subsequent to capping is an additional argument against the operation.

Pulps which are in a normal condition, still protected by a layer of even decomposed or partly decomposed dentine, usually admit of successful treatment. In such cases, the decayed dentine may be excavated from the side walls of the cavity, but that in the region of the pulp should be only superficially removed; in some cases, this portion may be allowed to remain undisturbed.

*Pulp-Capping.*—The operation of capping a pulp should include, as a necessary precaution against subsequent irritation, the thorough disinfection of any remaining decomposed dentine. An excellent method of securing disinfection is by first thoroughly washing the cavity several times with tepid water thrown gently from the large point of a syringe around the sides of the cavity; then, taking measures to prevent the entrance of saliva, wiping the cavity with absorbent cotton and passing over its surface a light current of hot air from a hot-air syringe. The heat should be sufficient to cause some discomfort to the patient, but not enough to produce irritation of the pulp. The dried cavity is then immediately saturated with carbolic acid previously warmed<sup>1</sup> to the normal temperature of the body by holding the pellet of cotton on which it is applied over the flame of a lamp for a moment. The carbolic

---

<sup>1</sup> Thermal shock to the pulp is as unwarranted from the application of cold carbolic acid as if produced in any other manner.

acid relieves any pain caused by the evaporation of moisture, and disinfects and sterilizes any decomposed matter in proximity to the pulp. The object of the application of the carbolic acid having been accomplished, it may then be removed in a measure from the surface. To this end the cavity should first be wiped with absorbent cotton, and hot air again introduced to evaporate the carbolic acid sufficiently to give a dry appearance to the surface. This second application of hot air, owing to the effect of the drug, will cause very little or no pain.

This method, if practiced early in the preparation of the cavity, will be found to considerably obtund sensation, and, through the dryness secured, to materially facilitate the removal of the decomposed dentine. A reasonable amount of the decayed portion should be cut away, as it lessens the difficulty of proper disinfection. For excavating in the region of the pulp-chamber, spoon-shaped excavators should be used invariably.

The disinfected dentine over the pulp is then capped with oxyphosphate. For this purpose the cement should be mixed soft. The proper quantity is then applied to one side of the cavity and brought over against the bottom in such a way as not to inclose air between the cement and the surface, or cause the slightest pressure upon the pulp. This is an operation requiring careful and delicate manipulation. Properly performed, it is preferable, in most cases, to protecting the part with a plate or cap, either metallic or non-metallic, fitted to the bottom of the cavity to avoid pressure of the cement; or to the use of concave caps filled with the cement; as, owing to the adhesive character of oxyphosphate of zinc, pressure from encompassed air is apt to occur frequently when the cap is adjusted in position.

If there is any apprehension of acid reaction from the oxyphosphate affecting the pulp, the bottom of the cavity can be first covered with a little chloro-gutta-percha, the chloroform being evaporated in the latter case with the hot-air syringe.<sup>1</sup> The carbolic acid by its presence and action on the surface of the dentine forms the only really necessary barrier to acid reac-

---

<sup>1</sup> Acidity of oxyphosphate cement arises from the use of too much acid in proportion to the oxid, from lack of thorough manipulation, or from unsuitable oxid of zinc. (See article on "Cementation.")

tion, if the oxyphosphate of zinc is suitably constituted, correctly compounded, and properly used.

Some preference is given to oxychlorid of zinc as a pulp-capping over the oxyphosphate, because of its antiseptic properties; but its use invariably requires the application of chlorogutta-percha to thin areas of dentine over the pulp.

Pulp-capping, when necessary, should precede any other operation, and no subsequent procedure is admissible until the success of that operation is assured, the time allowed for this purpose being governed by the diagnosis of each case. A non-vital condition of the pulp in one root of a tooth contraindicates any attempt to preserve it in any of the other roots, in connection with crown- and bridge-work. The rubber-dam, when its use is practicable, will be found a material aid in difficult pulp-capping operations.

## CHAPTER II.

### DEVITALIZATION OF THE PULP.

IN preparation for crown-work two methods of devitalization are practiced: the heroic,—instantaneous devitalization, or extirpation,—and gradual devitalization by arsenical treatment.

*Instantaneous devitalization* can be accomplished by first administering to the patient sufficient nitrous oxid to produce partial anesthesia, then with a drill quickly opening into the pulp-chamber, and *lacerating* the pulp well up the canal with a probe or smooth broach. Instantly afterward a pellet of cotton, saturated with carbolic acid, is forced up the canal, and, if possible, left until the next day, when the pulp will be found in a coagulated mass that is easily removed entire.

Devitalization of the pulp as just described is practicable only in teeth in normal condition. In acute inflammation, after laceration of the pulp, warm water should be gently injected into the pulp-chamber, and sedative agents then applied. Subsequent treatment should be such as will complete the devitalization and extirpation of the pulp.

*Cataphoresis.*—In cases of actual exposure of the pulp, the rubber-dam can be applied, the exposed pulp obtunded with hydrochlorate of cocain, applied in saturated solution; the diffusion may be hastened with electrolysis. As soon as the action of the cocain is manifest, the pulp may be extirpated.

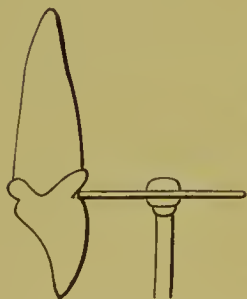


FIG. 1.

*Excision of the crown and instantaneous extirpation of the pulp* is practiced by many as follows: Two parallel grooves are cut opposite to each other, through the enamel, deep into the dentine, one on the labial portion of the tooth and the other on the palatal wall, close to the gum, with a rapidly revolving corundum or rubber and corundum disk (Fig. 1). Then

with excising forceps, the cutting-edges of which are inserted in these grooves, the crown is quickly severed from the root (Fig. 2). The pulp either adheres to the excised crown, leaving the canal empty, or remains in the root, fully exposed. In the latter case, a pointed piece of orange-wood, previously cut to fit the canal, and saturated with carbolic acid, is quickly driven with a blow into the pulp toward the apex of the root (Fig. 3). When the wood is withdrawn, the pulp usually adheres to it; if not, the wood is instantly reinserted, cut off and drilled out with the

pulp, using Gates-Glidden drills in the upper portion of the canal. In this operation only trifling pain is experienced by the patient, as the pulp is paralyzed by shock in the excision of the crown, or by being forced upward toward the foramen and against the walls of the canal.

The objections to this operation are, that if the pulp is not successfully extracted entire with the wood the canal becomes filled with clotted blood, which is difficult to remove from the extreme end; also that the root and socket are *jarred* by the forceps in excising the

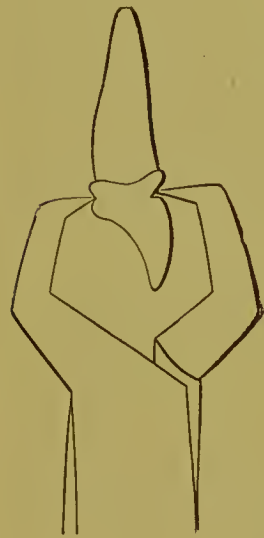

FIG. 2.

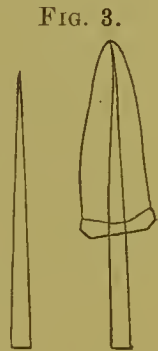

FIG. 3.

crown; but, expertly performed, it is advantageous in many cases, though it should be confined to cases where the pulps are in *normal* condition.

In cases of actual exposure in which excision of the crown cannot be safely practiced, as, for instance, in a bicuspid, a portion of the walls and grinding-surface may be removed to the line of the root-canal, the pulp obtunded with carbolic acid, and the wood point then forced up the root-canal in the same manner as in excising the crown.

*Devitalization with Arsenious Acid.*—The methods of devitalizing previously described are applicable principally to the pulps of incisors and enspids. In the posterior teeth, which do not so well permit the heroic treatment, recourse is had to arsenious

acid, notwithstanding the numerous objections to its use. Two theories as to the mode of its action in devitalizing are widely entertained; First, that by producing irritation of the pulp it causes its expansion, which stops circulation by strangulation at the foramen; the other is thrombosis.<sup>1</sup>

This theory of thrombosis accounts for the gradual devitalization of the pulp toward the foramen, and is very likely the true explanation.

Whatever the action of arsenic on the pulp may be, it always causes an infiltration of the tubuli of the dentine with certain constituents of the blood, probably the liquor sanguinis. The residue of the infiltration, after the devitalization of the pulp, to some extent remains in the tubuli, and increases the difficulty of producing an aseptic condition of the dentine. It is asserted that in some cases arsenic affects the vitality of the cementum, while after instantaneous extirpation of the pulp, when arsenic is not used, vitality is assured.

Practical experience shows that usually instant devitalization or extirpation is the most satisfactory in general and final results. Arsenic, when used, should be applied directly to the pulp in the smallest quantity possible to effect its devitalization, and securely sealed in the cavity.

In cases of non-exposure, requiring its application, a small opening into the pulp-chamber should be made. This can be accomplished with but little pain to the patient with a very small, sharp, spear-headed drill, rapidly revolved by the engine. The drill should be held steadily under gentle pressure at one point in the line of the intended exposure, until the pulp is slowly and gradually reached, and not suddenly punctured with the drill-point. The drill should be occasionally removed and the cavity flooded with carbolic acid during the operation. Cataphoresis may also be practiced.

The use of arsenic, combined with agents which are non-coagulants of albumen, is recommended in preference to combining it with creasote or carbolic acid. Dr. Harlan's method is to apply an anodyne, such as wine of opium, for a minute or two, and then the following paste:

---

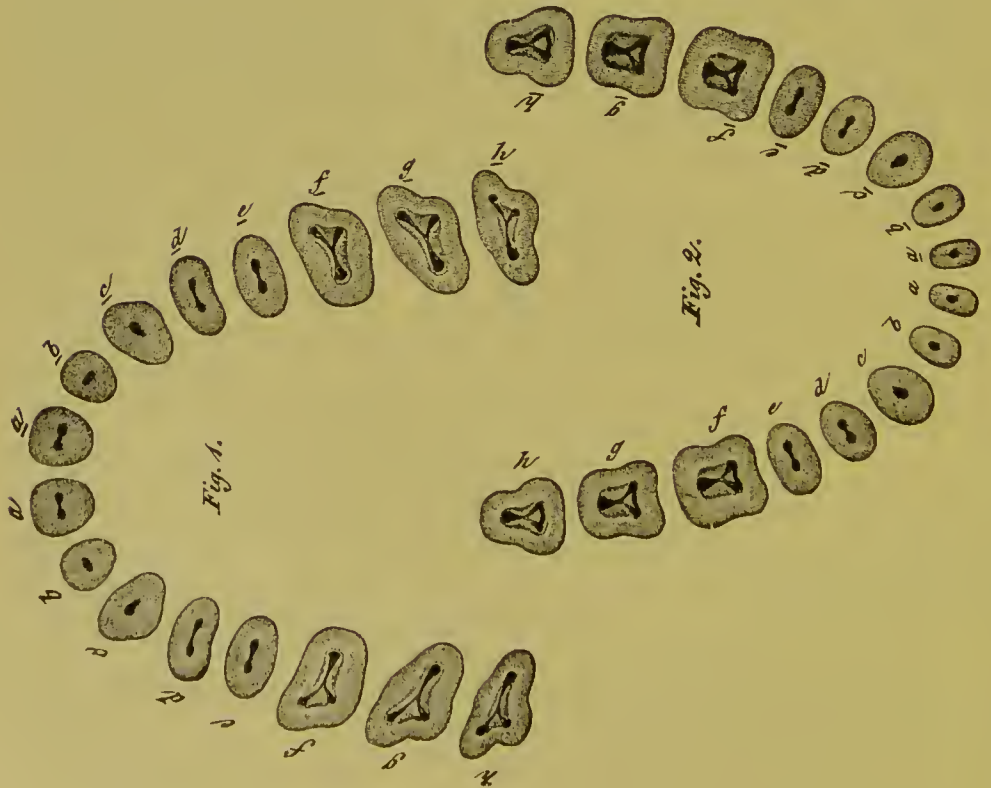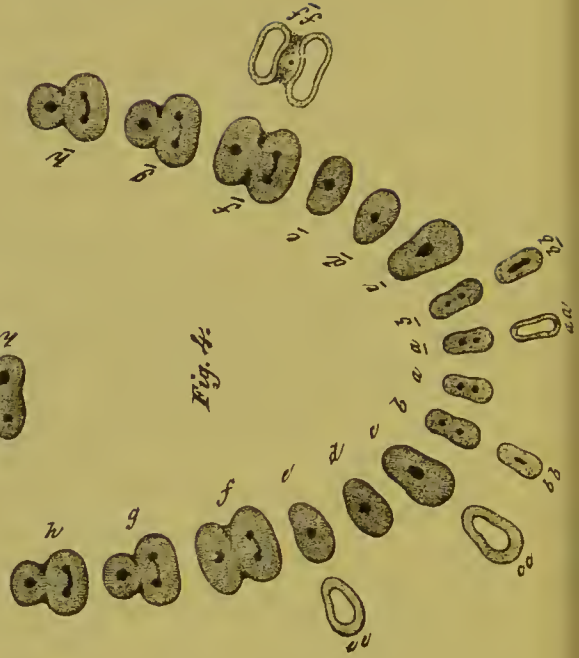
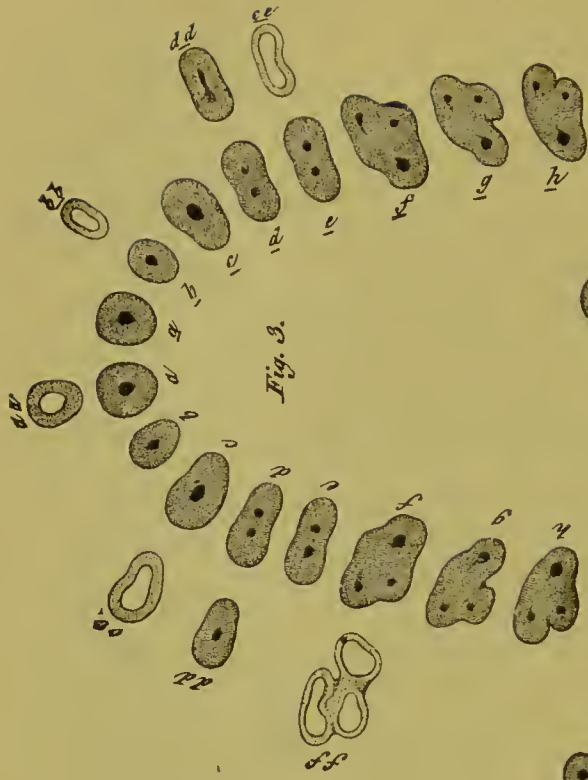<sup>1</sup> See Dr. L. C. Ingersoll's "Dental Science, Questions and Answers," page 96.

R—Arsenious acid, ℥ i;  
Muriate of cocain, ℥ ii;  
Lanolin in quantity sufficient to make a stiff paste.

The application should be kept in position no longer than is necessary to effect the devitalization of the pulp, twelve to forty-eight hours being sufficient for the purpose. The pulp is then punctured, a saturated solution of tannin in glycerol applied and securely sealed in the cavity, and the patient dismissed for several days. At the end of that time the pulp can, as a rule, be removed entire. The saliva should be entirely excluded, the rubber-dam being applied when practical, and peroxid of hydrogen or absolute alcohol instead of water used in the treatment.<sup>1</sup> When creasote or carbolic acid is used in combination with arsenic, the same method of subsequent treatment may be practiced. When the position of the tooth or root makes the application of the rubber-dam extremely difficult or impracticable, the operation can be successfully conducted without its aid. In such a case, after instrumental procedure, the pulp-cavity should be thoroughly syringed with peroxid of hydrogen, and the entrance of the saliva at once excluded by the insertion of a pellet of cotton saturated with the peroxid, oil of cloves, or some other antiseptic. The tooth can then be protected from the saliva by any of the usual methods practiced, and the treatment proceeded with.

---

<sup>1</sup> See *Dental Cosmos*, vol. xxxiii, page 138.





## CHAPTER III.

### PULPLESS TEETH—PREPARATION OF ROOT-CANALS—THEIR TREATMENT, DISINFECTION, AND FILLING.

THE treatment of pulpless teeth or roots consists in as thorough a performance as possible of the following operations :

1st. Removal of the contents of the canals.

2d. Disinfection of the root-canals and the dentine, and the establishment of permanent aseptic conditions by mummification of the contents of the tubuli.

3d. Closure of the apical foramen.

*Preparation of Root-Canals.*—A knowledge of the usual positions of the root-canals in the different teeth is essential for a generally successful performance of this operation, which is greatly facilitated by the ease with which direct access to the root-canals is obtained in crown-work. (See Plate IV.)<sup>1</sup> In the anterior teeth, the removal of the coronal section directly exposes the pulp-cavity. In bicusps and molars, for all-gold crowns, the leveling of the occluding surface (see Fig. 4) and removal of a portion of the side most involved by decay should be preliminary. An opening is first made into the center of the pulp-chamber in a line with the root-canals sufficient to give free and direct access to them, and any remaining portion of the pulp removed with broaches. A few fibers of cotton twisted around the serrated portions of the broach will admit of its easy removal in case of breakage. The canals are then, guided by

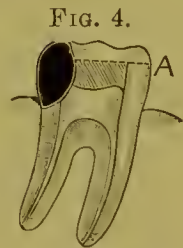


FIG. 4.  
Sectional view of an inferior molar decayed on the posterior approximal side. A, the line to which the crown should be removed to facilitate entrance to the pulp-chamber.


<sup>1</sup> PLATE IV.—Figs. 1 and 2 represent the superior and inferior teeth in transverse section through the base of the pulp-chamber in the crown, showing the entrance to the root-canals.

Figs. 3 and 4 represent the superior and inferior teeth in transverse section through the root-canals as they diverge from the pulp-chamber.

*aa, bb, cc, dd, ff, dd, and ee*, Figs. 3 and 4, show the relative shapes, whether circular, oval, or flattened, of the root-canals in the teeth they severally represent.

frequent explorations with a fine probe, carefully enlarged with Gates-Glidden drills (Fig. 5). At least three sizes—large, medium, and small—of drills each for the right-angle and the direct hand-piece are required. Very little, if any, pressure should be put upon them when in motion, as they will move

FIG. 5.



forward of themselves. Under pressure the formation of a false passage in a curved root is possible, or the small drill might be broken off or forced through the apical foramen with disastrous consequences, where alveolar abscess did not exist. Neither should drills be forced into canals closed by calcification, nor into the canal beyond the line of the zone of cementum at the end of the root, nor through a constriction which a fine, flexible probe cannot enter, nor around a curve sharp

enough to be unsafe to pass. A slight pain is usually experienced when they enter the zone of sensibility formed by the cementum which composes the end of the root, on the slightest symptom of which the patient should be instructed to instantly inform the operator. The probe-like points of these drills do not cut, but simply guide the drills and confine them to the line of the canal. They should be gently given a slight forward and backward motion in the canal, and treated more as reamers than drills. The occasional quick withdrawal of the drill from the canal during the process of drilling will aid removal of the *débris*. The depth to which a canal may be enlarged or reamed is regulated by its actual length and the above-mentioned conditions, and the diameter of the enlargement by the shape and dimensions of the root. The use of these drills is condemned by some for reasons attributable to their careless or improper employment, but they are indorsed, in experienced hands, for their adaptability to the work under consideration. They should be frequently sharpened with a suitably shaped piece of Arkansas stone. The Palmer root-canal excavators also will be found serviceable to open up a canal and enlarge it in accordance with its original shape. Donaldson pulp-canal instruments are also useful in the upper portion of canals or in those of very

small caliber. A fifty per cent. aqueous solution of sulfuric acid pumped into the orifices of root-canals with cotton wound on a broach is useful to open up very small canals or those partly closed by calcification.

The reaming of a root-canal not only simplifies the operation of filling, but also opens up the ends of the tubuli and facilitates the permeation of antiseptic agents.

*Treatment and Disinfection.*—Pulpless teeth are presented for treatment in one of the four following conditions:

1. Where a healthy or non-putrescent pulp has just been extirpated from the canals.

2. Where on opening into the pulp-chamber it is found empty and dry, with the pulp mummified or calcified in the root-canals, and the root externally in a healthy condition.

3. Where the pulp is found diseased or in a putrescent condition.

4. Where alveolar abscess is present and a septic condition of the canals and dentine exists.

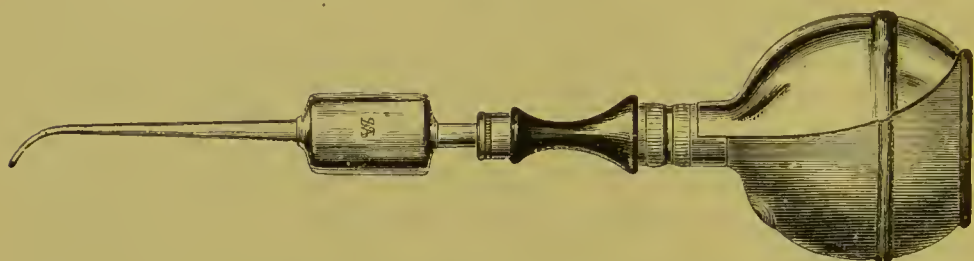In the first and second classes the treatment should be directed to assuring a continuance of the existing aseptic condition, and as immediately as possible the filling of the canal; in the third and fourth classes, to bringing about an aseptic condition by disinfection and sterilization, and making certain of its future maintenance, including incidentally the cure of any existing disease of the external membrane or of the alveolus.

In cases of the first and second classes, water and saliva should be excluded from the pulp-chamber and canals during their entire preparation and filling. The instruments should be sterilized, and the broaches, if serrated, had better be new. In the third and fourth classes, exclusion of saliva or water is not necessary in the preliminary work on the canal; water may be freely used until the process of disinfection and sterilization is commenced. Then and thereafter its entrance must be prevented. To this end the rubber-dam should be applied if practicable. When it is not, as frequently occurs with roots and teeth badly affected with cervical decay, other means of keeping out moisture should be resorted to. In such cases, during each interruption in the operation the entrance to the canal should

be filled with absorbent cotton saturated with a suitable essential oil or antiseptic fluid, the saliva being thus excluded.

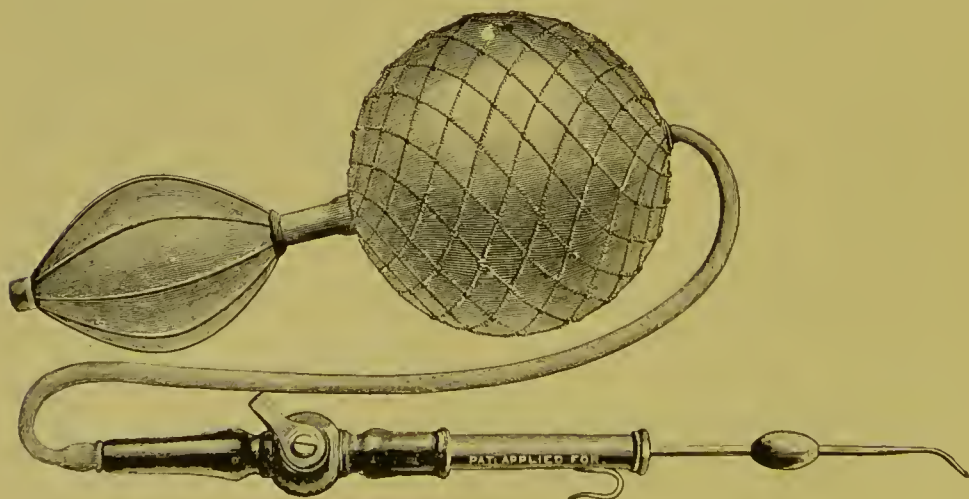
After the canal has been properly opened up and its contents removed, it may be washed out with peroxid of hydrogen, and wiped out with absorbent cotton. The use of sodium peroxid

FIG. 6.



is recommended by Dr. Kirk at this stage to open up the ends of the tubuli. The next point in the conduct of the operation is to secure as thorough a state of dryness in the pulp-chamber by an ordinary (Fig. 6) or an A. S. Richmond (Fig. 7) hot-air syringe, at a temperature higher—as it leaves the nozzle—than is comfortable for the finger. A root-canal dryer, with the end

FIG. 7.



tapered as fine as a broach at the point, is then introduced into the canal. The writer prefers the form in which the point is made of silver and the bulb portion of copper (Fig. 8). As silver possesses remarkable properties as a thermal conductor, the heat is transmitted to the point of the probe very rapidly. The probe


being inserted as far as possible up the canal (Fig. 9), the patient is directed to raise the hand as a signal should the heat cause pain, when the probe must be moved up and down or withdrawn

FIG. 8.



for a moment. This procedure, following the previous application of the hot air with the syringe, evaporates the moisture and aids the escape of any gases present in the root-canals and the open ends of the tubuli. The point of the root-canal dryer acts as a sterilizer, and may be applied so hot as to carbonize any organic matter which it reaches in the end of the canal, and a portion of this can be removed each time on its point. As the silver point can be tapered as small as the finest broach, canal-contents impossible to remove may be reached or rendered inert.

FIG. 9.



In cases of the third or fourth class, sepsis being present, the heat is very serviceable, as it aids the escape of gases from the canal and dentine and acts as a germicide. When in this dry and heated condition, the dentine is in the best possible state for the application of antiseptic agents.

*Antiseptic Treatment.*—The suitability of various antiseptics to the needs in treating tooth-structure, their effectiveness and permanency when so used, singly or in combination, are subjects on which great diversity of opinion exists, and which have of late been made the object of clinical study and scientific investigation and discussion. Many antiseptics in common use being coagulants of albumen obstruct the dentinal tubuli, and consequently limit or retard diffusibility throughout the dentine. This is the objection to the use of carbolic acid, creasote, and like agents, additionally to which may be named their inefficiency to accomplish in certain conditions the end sought, and as well their eventual absorption from the dentine. Recent investigations seem to give preference to such antiseptics as are non-coagulative in their action. Of this character are the essen-

tial oils, many of which, according to Miller, Harlan, and others, possess antiseptic power much greater than has been commonly attributed to them. Acidulated solutions of bichlorid of mercury, peroxid of hydrogen, sodium peroxid, especially in preliminary treatment, and various preparations of iodin, which exert chemical action and retain their antiseptic properties for a great length of time.

The selection of antiseptic agents is important, and is indicated by the conditions presented in a pulpless tooth. Cases in which a healthy pulp has just been extracted, or the canal is aseptic, are different from those with sepsis of dentine or diseased or putrescent pulps. In the first-mentioned condition, with or without antiseptic treatment, favorable results usually follow root-filling, the advantage of a reliable antiseptic agent in the canal being only to better insure the continuance of a state of asepsis. In the second condition the state of the dentine, and consequently the treatment to be effected, are entirely different. We need the intervention of agents that will not only destroy ptomaines, but exert a chemical action on sulfuretted hydrogen and ethereal ammoniacal gases, the products of putrefaction, and entirely eliminate them. On this depends the successful treatment of such cases, as the pressure and expansion of these gases are a certain cause for constant peridental inflammation, and so long as they are present in the slightest degree in a canal it is in an unsuitable condition to be closed. Carbolic acid, creasote, or the essential oils, in such a condition exert no chemical action on these gases, merely disguising their odor, though by repeated dressings of cotton saturated with one of these agents the gases are absorbed by the cotton, and to an extent slowly eliminated. What is required is the action of agents whose elements possess an affinity for the gases, and so will immediately decompose them, forming new combinations and entirely changing their character.

In accordance with these principles, the use of iodin is indicated and preference is given to its use in practice to that of the other agents mentioned. Its effects are best obtained from some one of the preparations now in use,—aristol, for instance, whose odor is entirely unobjectionable, in a strong solution in one

of the essential oils. In the writer's practice he favors the oils of cloves, cassia, and eucalyptus, considering the oil of cloves more sedative in action than the others. He makes it a point to flood the canal with the solution, thereby to some extent saturating the heated dried dentine as well as the cementum at the apex. A more effective saturation can be accomplished by again drying and heating the dentine and applying the solution, or by filling the canal with cotton saturated with the solution, hermetically inclosing it and letting it so remain for a day or two.

Coagulants, such as creasote or carbolic acid, are not entirely non-diffusible in devitalized dentine or cementum, as decomposition or putrefaction effects elementary changes in the contents of the tubuli, but their action is slow and limited compared with that of the essential oils. They have also the objectionable feature of being irritants, and unsuitable where acute or chronic inflammation of the peridental membranes is present. When a healthy pulp has just been extirpated, and immediate root-filling is practiced, the use of carbolic acid, creasote, or solution of chlorid of zinc is best indicated, the condition then presented being entirely different from that where the pulp is diseased or putrescent, or the canal is in a septic state. When a healthy pulp has been removed, its minute fibrous connections with the walls of the canal and the vessels at the apical foramen are severed, and the action of an escharotic antiseptic agent, such as carbolic acid, is in fact then indicated, as it acts as a coagulant and instantly seals up the ends of the tubuli. If immediate root-filling is not to be practiced, then the prescription of such agents as the essential oils, with aristol or iodoform, seems more suitable, as by their action a sort of mummification of the non-vital organic matter follows. Moreover, the oils possess advantages over the coagulants mentioned as they are not miscible in water, and are easily eliminated. Their use consequently will better tend to perpetuate an antiseptic condition.

The disadvantage of immediate root-filling is that, should some fragment of the pulp remain in the extremity of the canal, it fails to receive the benefit accruing from the reapplication of antiseptics, which would better assure inertness by mummification.

There is such a thing as over-treatment,—an unnecessarily frequent renewal of antiseptic dressing in root-canals, thereby aggravating or producing irritation of the pericementum at the apex of the root. Such cases may be relieved by washing out the canal with alcohol and applying the alcohol on the dressing, instead of the agents previously employed.

The dressing of root-canals is best performed with the aid of a flexible rectangular probe, such as the How. The form of this instrument permits fibers of cotton to be easily wound around it lengthwise and over its point in one connected mass. When the cotton is introduced in the canal, it is retained on and carried forward by the instrument, which, when withdrawn, leaves the cotton in position in the canal in the form of a cone or tampon that will favor the escape of gases, and it may still be easily removed at any time. After one or more treatments in the manner described, in which, if interspersed by intervals of time, the antiseptic agents must be hermetically sealed in the cavity with gutta-percha, the canal is dried and the foramen closed.

*Closure of the Apical Foramen and Filling of the Canal.*—The object of root-canal filling is to prevent the entrance of the fluids through the foramen, and to avert, in case of the formation of gases, irritation of the peridental membranes by their pressure or presence. Gutta-percha and oxychlorid of zinc are generally accepted as most suitable for the purpose. Either gutta-percha in the form of chloro-gutta-percha, or the oxychlorid of zinc mixed thin, can be pumped or placed in the extreme end of the canal with the aid of a broach or fine-pointed probe. This is one of the advantages that commend the use of these materials. When the chloro-gutta-percha has been placed in the apex, the remainder of the canal can be filled with the prepared cones of solid gutta-percha until no more can be inserted. A current of hot air should then be thrown on the protruding ends of the cones at a temperature sufficient to soften them and warm the dentine, when they should be gently pressed, but not suddenly pushed, up in the canal. A slight twinge of pain to the patient will usually be the signal of their complete impactment in the canal. The solid gutta-percha absorbs what little chloroform was



present in the chloro-gutta-percha, and the heat also aids its evaporation, so that the shrinkage so often urged as an objection against the use of chloro-gutta-percha is reduced to a minimum.

An advantage possessed by oxychlorid of zinc over other materials is its antiseptic qualities; its disadvantage, the difficulty attending its removal from the extremity of the canal should supervening conditions require it. For this reason the apex and extremity of the canal may be filled with gutta-percha, and then the orifice and pulp-chamber with oxychlorid. Wood and metal shaped to fit the canal are also much used to fill root-canals, but unless a small quantity of chloro-gutta-percha or oxychlorid of zinc is placed in the extremity or on the point used, the entire closure of the canal is doubtful. The use of cotton as a filling in root-canals is to be condemned, unless it is sterilized<sup>1</sup> or iodoformized and saturated with chloro-gutta-percha or oxychlorid of zinc previous to insertion. Asbestos is given preference to cotton by some. Tin or gold foil is difficult to insert without vacuoles. Paraffin in combination with a small quantity of aristol, as a material to fill root-canals, has been suggested by Dr. Kirk, especially after the use of sodium peroxid; sodium peroxid being a most active solvent of albuminous matter, in a measure frees the ends of the tubuli or a canal of their organic contents, a condition favorable for the use of paraffin. Paraffin is aseptic and melts at a low temperature, and can with a heated root-canal dryer be flowed into the ends of the tubuli or a minute canal that was not considered safe to open up. Ordinary gutta-percha should be used to close a foramen when an abscess has just been treated by injecting through it. The length of the canal should be measured with a probe, and gauged with a small perforated disk of rubber-dam slipped upon the instrument. The gutta-percha should then be carried to position on the point, allowance being made for the displacement of the instrument. As oil of eucalyptus is a solvent of gutta-percha, the application of this oil, alone or in combination

---

<sup>1</sup>Cotton or wood points may be sterilized by immersing them for a time in a solution of bichlorid of mercury or a saturated solution of iodoform in ether, and then drying. The prepared points should be kept in a tightly-corked bottle. When this plan is followed, the odor of iodoform is avoided in the operating-room.

with iodoform or aristol, is recommended in the final treatment when chloro-gutta-percha is not used, as better adhesion of the gutta-percha to the walls of the canal is thus obtained.

Ample room should be left in any root-canal which is to receive the post of a crown, as any part of the canal not occupied by the post will be filled by the retaining material.

A pulpless tooth presented for crowning, the roots of which have been treated and filled in some previous operation, should be carefully examined, and if any doubt is entertained as to its hygienic condition it should receive the antiseptic treatment above described, as the ultimate success of crown-work depends largely upon the thoroughness of these preliminary operations.

## CHAPTER IV.

### CHRONIC ALVEOLAR ABSCESS.

MANY teeth and roots presented for crown-work are affected with chronic alveolar abscess. A general description of an effective method of treatment is therefore properly associated with a discussion of the subject.

The cause of chronic alveolar abscess will be found in a continuation of those conditions which originally produced the acute form. The tooth or root being pulpless, septic gases, generated by the decomposition of organic matter in the root-canal and in the tubuli of the dentine, find an outlet through the open foramen into the apical space, causing pericementitis and formation of pus. The general treatment consists in the removal of all septic matter and gases from the root-canal and dentinal tubuli, the destruction of the pus-sac, the application of suitable therapeutic agents, and the adoption of measures to prevent further formation of pus.

Chronic alveolar abscess is usually found in the following forms: 1st. Abscess with a fistulous opening in the gum, and accessible through the root-canal and foramen of the root. 2d. Abscess with fistulous opening, but not accessible through the apical foramen. 3d. Abscess from which pus discharges through the apical foramen and root-canal, with no opening through the gum.

In the treatment of abscess of the first form, the canal should be enlarged as described in the treatment of pulpless teeth, and the foramen opened, if possible, with a smooth broach without the use of a drill. Aromatic sulfuric acid, on cotton, placed in the end of the canal for a day, will usually open up the finest foramen. A small quantity of fifty per cent. aqueous solution of sulfuric acid pumped into the extremity of the canal with cotton on the end of a broach will often instantly effect a passage.

Tepid water is then forced through the foramen with a fine-pointed syringe (Fig. 10) introduced well up the canal, and packed in with gutta-percha; or it may be pumped up with cotton on a broach until it passes into the abscess and out through the fistula. Peroxid of hydrogen is next used in the same manner, until it ceases to foam as it passes from the abscess. Aromatic sulfuric acid is then injected through the fistulous opening into the abscess.

In abscesses of the second form, where it is impracticable to treat through the foramen, the canal should be thoroughly disinfected, and a direct opening into the abscess effected by the track of the fistula, enlarging it if necessary. The abscess should then be thoroughly injected with peroxid of hydrogen, and afterward with aromatic sulfuric acid, by introducing the fine point of a syringe into its deepest parts. The fistula must be

FIG. 10.



kept open by inserting in it, at each injection, a strand of twisted cotton saturated with oil of cloves, the patient being directed to remove it in a few hours, or the next day, for which purpose the end should be left protruding. When the apical foramen is open, one injection is usually sufficient to cure an abscess; but when the foramen is closed and the abscess is treated through the gum, several injections are sometimes necessary.

In case of "blind abscess," the third form, first clean and disinfect the root-canal, then at intervals inject the abscess through the foramen with peroxid of hydrogen until the formation of pus ceases, placing cotton saturated with oil of cloves loosely in the canal to exclude foreign substances. Should this treatment fail, an opening through the gum into the abscess must be obtained, with a lance and drill, and the same course pursued as in the first form of abscess.

An entrance into the apical space can be made almost pain-

lessly in the following manner, as described by Dr. G. V. Black:<sup>1</sup> "The mucous membrane is first dried at the point at which it is desired to make the opening, and napkins are so placed as to keep it dry. Then a plugging-instrument with fairly sharp serrations and of convenient shape is selected. The point of this is dipped into a 95 per cent. solution of carbolic acid, and a drop conveyed to the mucous membrane; this will at once produce a white eschar. Then a slight scratching motion with the serrated point is begun, with the view of removing the tissue that is whitened. This is continued until the carbolic acid is thick with the *débris* of the tissue torn up, then it is dried out and another drop added, as before, and the process continued. This is repeated as often as may be necessary, going deeper and deeper into the tissue in the desired direction until the bone is laid bare. Then a fresh drop of the acid is placed on the bone, and the periosteum carefully raised over a sufficient space; then with a sharp chisel cut through to the peridental membrane. This will generally cause some pain and some bleeding, but after giving a little time for this to cease, and adding more of the acid, the apical space can usually be reached without difficulty. No blood should be drawn at any time during the operation, except in penetrating the wall of the alveolus. In doing this no tissue is removed until it is anesthetized by the carbolic acid. This is a little tedious, but it is almost painless, and the general effect is usually better than by other modes of penetrating the apical space. The carbolic acid has the effect of modifying the pain, and the opening left does not close so readily."

A period of entire cessation of discharge of pus is to be considered the most favorable indication of successful treatment.

Thorough disinfection and sterilization of the dentine and root-canals are included in the preliminary treatment of alveolar abscess. As soon as the treatment is followed by favorable indications, the foramen should be closed, any further treatment considered necessary being conducted externally through the fistula. This may be facilitated by enlarging the orifice with tents of cotton saturated with oil of cloves. Enlargement of

---

<sup>1</sup> "American System of Dentistry," vol. i, page 928.

the fistula tends to encourage the process of granulation in the region which has been occupied by the abscess.

After the abscess has been cured, the root-canals are filled as described on page 21.

Aromatic sulfuric acid is a powerful astringent and germicide. It will be found most useful in cases where a slightly necrosed state of the wall of the alveolus exists. Its use should, however, be limited, and in subsequent external treatment through the fistula some of the other therapeutic agents should be employed, as the peroxid of hydrogen, sublimate solution ( $\frac{1}{1000}$ ), or the essential oils or carboic acid, alone or combined with one of the preparations of iodine.<sup>1</sup>

Injections of sulfuric acid in the region of the mental foramen should be made cautiously, and it should not be applied to an abscess bordering on the antrum until the operator is positively assured that the abscess does not open into that cavity.

*Amputation of the Apex of a Root.*—In long-neglected alveolar abscess, the pus-cavity occasionally involves the alveolus in such a way as to destroy a considerable portion of the pericementum

FIG. 11.



of the end of the root. The cementum of that part is consequently devitalized, and the portion of the root affected becomes degenerated in structure, and saturated with septic matter. In this condition it acquires the character of a foreign substance, proves a constant source of irritation, and defies all efforts of the membranes to perfectly inclose or encyst it.

In such cases, amputation of the portion of the root which is denuded of pericementum is the best course to pursue. An opening is made in the soft tissues over the affected part in the manner described on page 33, and gradually enlarged with a tent of lint or cotton until the diseased territory is fully exposed (Fig. 11), when the devitalized end of the root and any necrosed bone in

<sup>1</sup> For an extended consideration of this subject the reader is referred to Dr. J. N. Farrar's articles on "Sulphuric Acid v. Creasote in Treatment of Alveolar Abscess," commencing in *Dental Cosmos*, vol. xx, No. 7, and Dr. G. V. Black's article in the "American System of Dentistry," vol. i, page 929.

the territory are removed, and the end of the root smoothed. The canal should be filled solidly with gutta-percha or oxychlorid of zinc previous to the amputation, so that when the end of the root is excised the stump will be left smoothly and snugly filled. Cocain can be used in this operation.

The orifice of the cavity in the gum should be kept open and daily injected with a mild antiseptic solution by the dentist or patient until the cavity is filled by granulation. In cases where extensive necrosis of the alveolar process has existed, in addition to the daily injection the cavity should be packed with a suitable antiseptic dressing. Balsam Peru has been found by the author to be a suitable agent for the purpose, as it assists the process of granulation. When the healing process is completed, crown-work can be proceeded with.

The amputation of roots requires skill and experience, and had better be confined to the front teeth or those with a single root.


## CHAPTER V.

### SHAPING TEETH AND ROOTS FOR CROWN-WORK.

THE principles governing the process of shaping the surface of a natural crown or root for any style of artificial crown with a collar attachment require that the cervical portion of the natural crown and root shall be given a form that has longitudinally parallel sides gauged to the line of the periphery of that part, and that any of the coronal section present below it shall be reduced at least sufficiently in size to come within this line. Such a form is necessary to admit of a perfect adaptation of the collar.

The coronal section of a natural crown to be prepared is usually first ground on the occluding surface with as large a corundum-wheel as the case will conveniently admit (Fig. 12).

FIG. 12.



Molars and bicuspid for all-gold crowns should have enough substance removed to make a small space between them and the antagonizing teeth. The approximal sides of the cervix should be reduced sufficiently to allow a free space between the gold collar when adjusted and the cervices of approximal natural teeth or artificial crowns, to make room for the gum septa. The approximal surfaces are removed straight from the cervical border to the occluding surface, using corundum or rubber and corundum disks (Fig. 13) and files, and last of all, as injury to the approximal teeth is then more easily avoided, the labial and palatal portions, for which small corundum-points (Fig. 14) and wheels are best adapted. The corners are then rounded. The cervical portion, which includes the junction of the dentine and enamel, is trimmed so that the sides as illustrated at A,



Fig. 15, are level and parallel with the line of the root, and as deep as the collar is to be placed (Fig. 16). For this work, small corundum-points, trimmers, and files can be used. Fig. 17 illustrates a trimmer, made in three sizes, which in the ordinary hand-piece or in the right-angle attachment will easily

FIG. 13.



FIG. 14.



and quickly accomplish this. Fig. 18 illustrates another style, in the form of a triangular pyramid, which can be used as a scraper in a hand-socket, bracing the hand by resting the thumb on the adjoining teeth. The points should be tempered very hard. Files shaped as shown in Fig. 19 are useful in rounding angular portions. A smooth surface should be given the cervix.

FIG. 15.

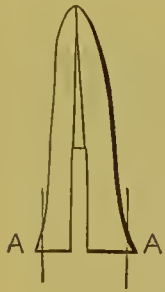

FIG. 16.



FIG. 17.



FIG. 18.



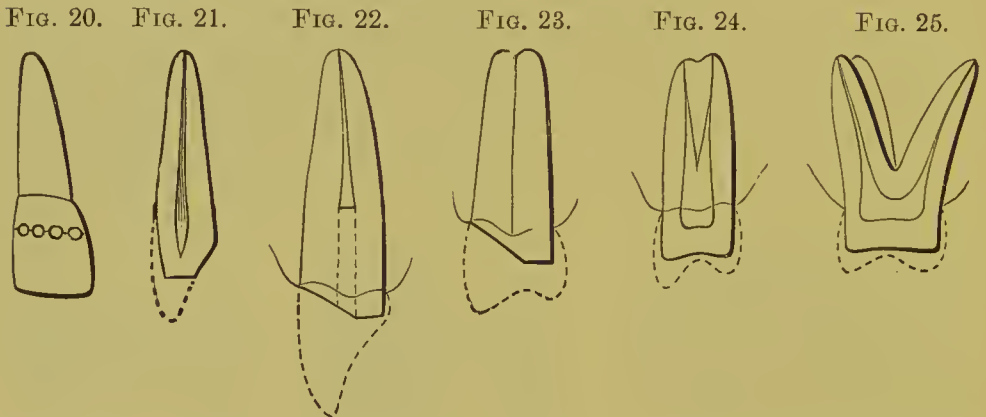
FIG. 19.



On approximal sides and the curves to the other sides, medium coarse corundum tape and wheels can be used for this purpose.

In pulpless teeth, the use of excising forceps should be avoided unless the parts admit of it without serious shock to the root. The best plan is to make a succession of holes with a spear-shaped drill across the portion to be removed, and then cut between the holes with a fissure-bur or corundum-disk, which will permit of easy removal of the part (Fig. 20).

In preparing incisors and cuspids for gold collar crowns with porcelain fronts, where the pulp is to be preserved, the labial surface and incisive edge should be ground down as much as possible without exposing the pulp or subjecting it to irritation; the palatal portion at an angle from the cervical border to the incisive edge, enough to level its prominences of contour and form a slight space between it and the antagonizing teeth (Fig. 21). Pulpless incisors and cuspids should be prepared by grinding the labial face to the gum-margin, with the palatal portion slightly projecting and squared off to the inner line of the root-canal. (See Fig. 22.) Bicuspids which are to have porcelain fronts are given the same general form (Fig. 23).



Bicuspids and molars with or without pulps, for all-gold crowns, should have as much of the natural crown left as possible, as it affords a more secure and more convenient attachment for the artificial crown than any other method (Figs. 24 and 25).

It should be borne in mind, however, that unnecessarily cutting away the enamel and dentine of teeth with living pulps leaves them in an extremely sensitive condition, and is likely to result subsequently in some serious lesion of the pulp. Slight sensitiveness, such as may be readily caused in excessive shaping, is relieved by drying the exposed dentine with hot air and applying carbolic acid two or three times as required.

*For the porcelain system,* roots are usually ground level with the margin of the gum. The palatal portion in some cases is left a trifle above the margin, and the labial aspect should be below, especially on the front teeth, if it is desirable to conceal the joint.

The root-canal is shaped to the form of the post or pin to fit it tightly. (See the articles on Gates-Bonwill and Logan crowns.)

The occluding edges or surfaces of antagonizing teeth should be removed sufficiently to allow ample space for the artificial crowns or to favor them in occlusion. This is especially necessary where the occluding tooth, in the absence of an antagonist, protrudes beyond the proper line of occlusion. When the approximal teeth crowd against and overhang the cervix of a root, so that the space for the artificial crown at the occluding surface is less than at the prepared cervix,—measured from mesial to distal side,—the sides of the root should be trimmed so as to give a free space between it and the sides of the approximal teeth. The approximal teeth may also be pressed away, or a small portion of their interfering surfaces removed. (See Figs. 26 and 27.)

Corundum or composition wheels or points should be kept wet and cool during all such operations in the mouth. A piece of sponge, held against the wheel with clamping pliers, answers the purpose admirably, and also protects the tongue and cheek from injury.

FIG. 26.

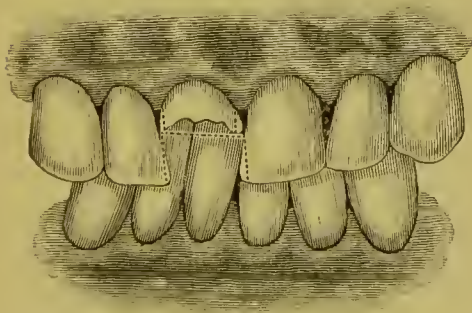
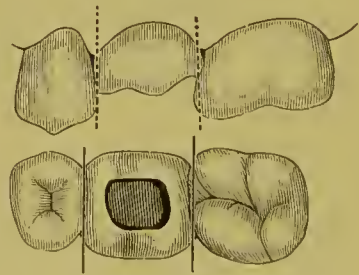


FIG. 27.



*Special Preparation of Badly Decayed Teeth or Roots.*—The temporary exposure of the end of a root or of the cervical portion of a crown for the purpose of facilitating or simplifying a crowning operation, especially in the adaptation of a collar or band, is effected by inserting in the pulp-chamber or the root-canal a piece of gutta-percha large enough to admit of a portion being brought over against the investing membranes, to compress them for a day or more. When necessary to secure attachment for the gutta-percha, a plug of wood should be inserted temporarily in

the root, and the gutta-percha packed around it. Roots can thus be exposed to the border of the alveolar process if desired. In bicusps and molars, when decay extends up on the cervix farther than will the edge of the artificial crown or the collar, the gums should be pressed up as described, the decay removed, retaining-pits made, and the cavity filled with amalgam shaped to the contour of the tooth (Fig. 28). In incisors and euspids, when decay has destroyed a portion of the side of the root, a tight-fitting tube of a metal to which amalgam will readily adhere, and of such size as to admit the pin of the crown, can be inserted up the root-canal and the upper end cemented in with oxyphosphate or oxychlorid, and the lower with the amalgam forming the filling on the side of the root. In such a case, the pin should be tapered at the end, and inserted in the canal as deeply as

FIG. 28.



FIG. 29.



FIG. 30.



FIG. 31.



FIG. 32.



possible beyond the end of the tube, to gain additional strength by distributing the leverage along the whole line of the root.

In setting a gold cap-crown on a badly broken-down tooth or root, a post of silver or iridio-platinum wire should be fitted to the root-canal (Figs. 29, 30, 31, and 32). The end can be bent or a piece of silver soldered to it. The post should then be barbed and the point first fastened in the root with a little oxyphosphate or oxychlorid of zinc, and the crown built down about two-thirds its length with a quick-setting amalgam, to be shaped when hard and then roughened to furnish a better attachment for the cement with which the crown is set. Screws may be used as posts to support the amalgam. In such cases, it is presumed that the gold cap will entirely cover the amalgam.

PART II.

---

ARTIFICIAL CROWN-WORK.



## ARTIFICIAL CROWN-WORK.

ARTIFICIAL crown-work affords extensive facilities for restoring the crowns of natural teeth, and furnishes means of support for bridge-work.

Two general systems are presented,—the porcelain and the gold. The porcelain system includes porcelain crowns with metallic attachments, with or without collars, and the gold system gold crowns with porcelain fronts.

# THE PORCELAIN SYSTEM.

---

## CHAPTER I.

### PORCELAIN CROWNS.

PORCELAIN crown-work is practiced by many dentists almost exclusively, excepting only the occasional insertion of a gold cap-crown on a posterior tooth. The reasons for this are, the intricate character of the construction of gold crowns, and objections to crowns with bands or collars.

The advocates of the porcelain system claim for it natural appearance, restoration of contour, strength, and cleanliness, together with simplicity of construction and easy adaptation and attachment to the root, to which the crown is hermetically sealed.

Porcelain crowns are made in two general styles. In one the crown is attached to the root by a pivot, post, or screw, one end of which is cemented in the root and the other in the crown. Such are the Gates-Bonwill, Foster, and Howland-Perry crowns. In the other style, one end of the pivot, or post, is baked in the porcelain when the crown is made, and the other end cemented into the root when the crown is adjusted. The Logan and Brown crowns are of this class.

Special advantages are claimed for each of these several forms of crowns. A general knowledge of the different methods is therefore essential to determine the adaptation of each to the requirements of a case.

The preparatory treatment of the roots respecting the process of grinding, trimming, and shaping is nearly the same for all porcelain crowns. A plaster model and "bite" of the case will aid in the selection of a suitable crown and in the pre-



liminary fitting to the root. A post of wood or metal placed in and left extending from the root-canal, and then withdrawn in the impression, will give the line of the canal in the plaster model. Exposing the end of the root, by pressing the gum away from it with gutta-percha preliminary to the operation, will greatly assist the operator, by enabling him to avoid accidental laceration of the adjoining membranes, and the annoyance attending their bleeding, besides permitting him to carefully study the adjustment and cementation of the crown. The obtaining of a close joint is much facilitated

in all forms of porcelain crowns by passing a disk of black marking-paper over the post or pin which is to retain the crown, and placing the crown in position on the root. (See Fig. 33.) Cut the paper in a strip, and, to admit the post, form holes with a punch as shown on margin of Fig. 33. The points which prevent perfect adjustment are marked on both root and crown, either of which can be dressed off accordingly as seems most desirable. Crowns in which the post is cemented will first be described.

#### THE GATES-BONWILL CROWN.<sup>1</sup>

The Gates-Bonwill crown is made entirely of porcelain. It is molded with a concave base and with a triangular perforation for the reception of the post. The perforation passes from the bottom of the base to the center of the palatal or lingual surface in incisors and cuspids (Fig. 34), and to the center of the grinding-surface in bicuspid (Figs. 35 and 36). The

FIG. 33.

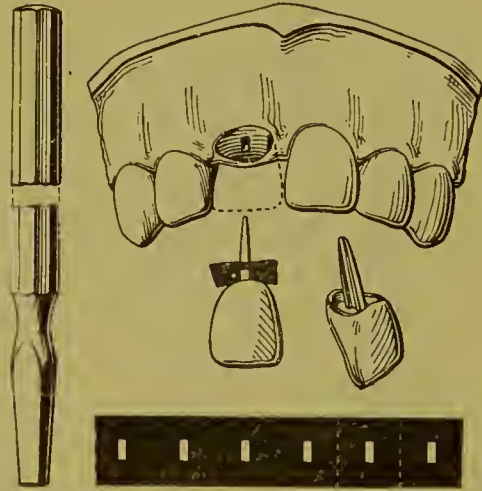
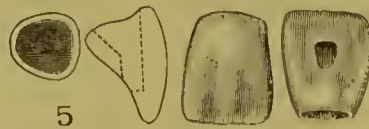
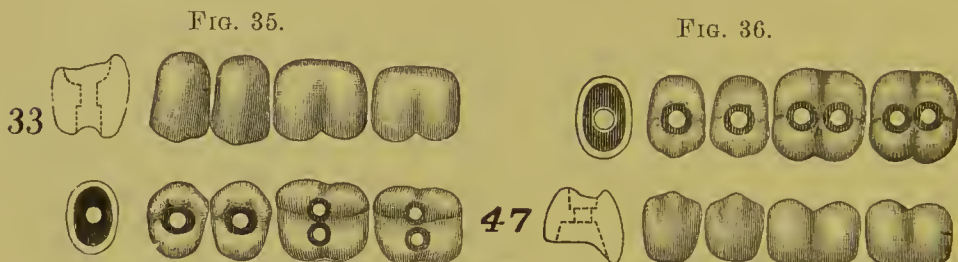

FIG. 34.



<sup>1</sup> Owing to their great similarity, the two crowns formerly known as the Bonwill and the Gates, from their respective inventors, have been merged in one, to which the name Gates-Bonwill has been applied.

molars have two perforations, placed in the uppers across the line of the arch (Fig. 35), and in the lowers in that line (Fig. 36). The openings of the perforations upon the exposed surfaces are very slightly countersunk.



The posts to secure this crown are first cemented or screwed into the root-canal. The crown is then fitted over the free end of the post and attached with cement, and in some cases, additionally, a screw-nut on post.

FIG. 37.



The incisors and cuspids, of course, require one post; the bicuspid usually one, sometimes two; the molars two posts. The form of post, the screw, most commonly used is illustrated in Fig. 37. They are usually made of an alloy of silver and platinum; gold and iridio-platinum are also used.

*The method of preparation* of the end of the root and canals to receive and retain one or more posts to mount the Gates-Bonwill crown is about the same as is used for all similar styles of crown. The end of the root is trimmed to the gum-margin in the front teeth, slightly below it at the labial side, to hide the intended union of porcelain with root. A slight concavity is also formed on the end of the root, as shown in Fig. 40. The length of the root-canal is measured with a root-canal plugger and its flexible gauge. A disk of rubber-dam can be placed on the plugger and used for the same purpose. By this means the proper length for the post is determined. The dimensions of the root determine the diameter. Fill that part of the end of the canal which will not be occupied by the post. Enlarge the canal with Gates-Gidden drill as deep as required to accommodate the post for the crown which is to be inserted. Next, with a gauge-plate, determine the size of the post, and

with smaller-sized fissure-burs gradually ream the canal to a dimension which the post will fit tightly. The screw-post is then cemented in position with oxyphosphate or oxychlorid of zinc.

FIG. 88. When the post is to be screwed in the canal, instead of being cemented, the How screw-posts and appliances, illustrated in Figs. 38 to 43, had best be used as here described.



FIG. 39.



FIG. 40.



FIG. 41.



FIG. 42.



FIG. 43.



"1. Set gauge on a Gates drill (Fig. 38) to one-half the gauged depth of the canal, and drill to that depth.

"2. Set the twist-drill in its chuck (Fig. 39) to project the same length as the Gates drill, and drill the root to exactly that depth.

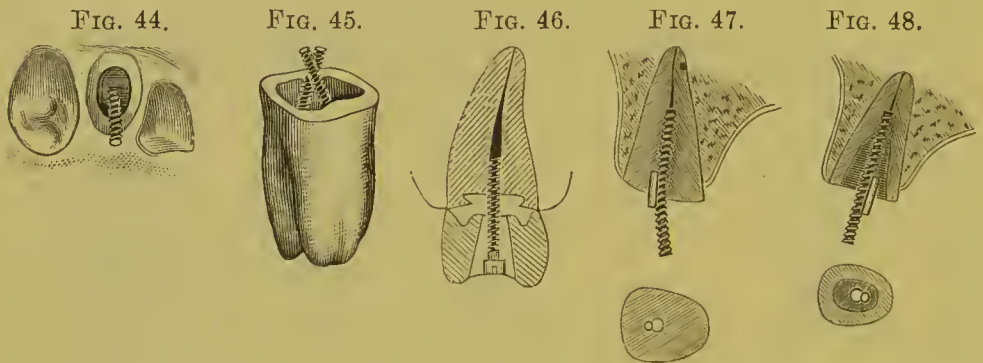
"3. Enlarge the mouth of the canal one-sixteenth of an inch deep all around to near the margin of the root, as shown in Fig. 40, using square-end fissure-bur No. 59, and then with oval, No. 94, undercut a groove lingually and at the sides.

"4. Set the tap in its chuck (Fig. 41) a trifle less in length than the drill, oil it, and carefully tap the root to the gauged depth.

"5. Insert the post (Fig. 42) in its chuck (Fig. 43) to the exact gauge of the tap, and turn the thumb-screw down hard on the end of the post, then screw the post into the root, release the thumb-screw, unscrew the chuck a half-turn, bend the post until the chuck stands in center line with the adjoining teeth, and unscrew the chuck from the post."

The appearance of posts in relation to roots and crowns is illustrated in Figs. 44, 45, and 46.

In single-rooted teeth, when desirous of locking the post in the root to prevent turning of either post or crown, Dr. How suggests to take a No. 2 round bur and drill less than an eighth of an inch into the root close to and cutting slightly into the post, and insert a quarter of an inch length of wire as shown in Fig. 47.



If a root is much wasted, leaving thin walls, the preceding gauging and locking process will result in the secure and safe setting of a screw-post to be packed around with amalgam, as shown in Fig. 48, and on this connection a suitable crown can be securely mounted.

When grinding the selected porcelain crown to position on the root, the end of the post should be bent or trimmed so as to allow the crown to assume any desired position. (Fig. 47.)

*Attachment of Crown to Root.*—Amalgam, oxyphosphate, or gutta-percha is used for the purpose.

*To attach with amalgam,* place the amalgam high enough up on the root and post to fill the base of the crown.

The crown should be tried on, and forced home with the aid of an adjuster, removing the surplus amalgam if too much, or adding to if not enough. Remove and dry the crown, and fill up simply the undercut cavity in the palatal face if an incisor, or the depressions in the crowns of bicuspid or molars, allowing a very little to extend into the cervical base, and force the crown home with the adjuster. It requires considerable force to set one of these crowns,—a force which cannot be applied with a

mallet without danger of loosening or displacing the crown. Steady pressure with slight rotation will carry the crown into place, if the amalgam is not too hard or there is not too much of it. Next hold the crown with the fingers and through the hole in the crown pack amalgam mixed stiff around the pin, assisted by cotton or bibulous paper to remove the surplus mercury. If a nut is used on the end of the post, remove enough amalgam to make room for the nut, screw the nut to position and cover with amalgam. A quick-setting amalgam should be used.

*Oxyphosphate cement* is preferred at present to attach all crowns of this style. The posts are carefully dried, the cement mixed to the consistence of a thick cream, the crown adjusted on the root, and the nut placed on the post and screwed to position in the crown.

When a nut is not used on the post, the crown must be held in position until the cement sets sufficiently hard to prevent displacement.

*Gutta-percha*, when used, is heated together with the crown, and applied the same as oxyphosphate.

When the cement is set, any space around or above the nut on the post should be filled with either amalgam or gold to the surface of the crown.

#### THE FOSTER CROWN.

The Foster crown (Fig. 49), which in general form is similar to a crown introduced by Dr. H. Lawrence, of Philadelphia, in

FIG. 49.

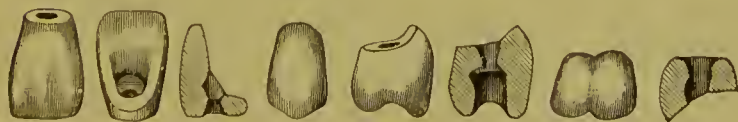

FIG. 50.

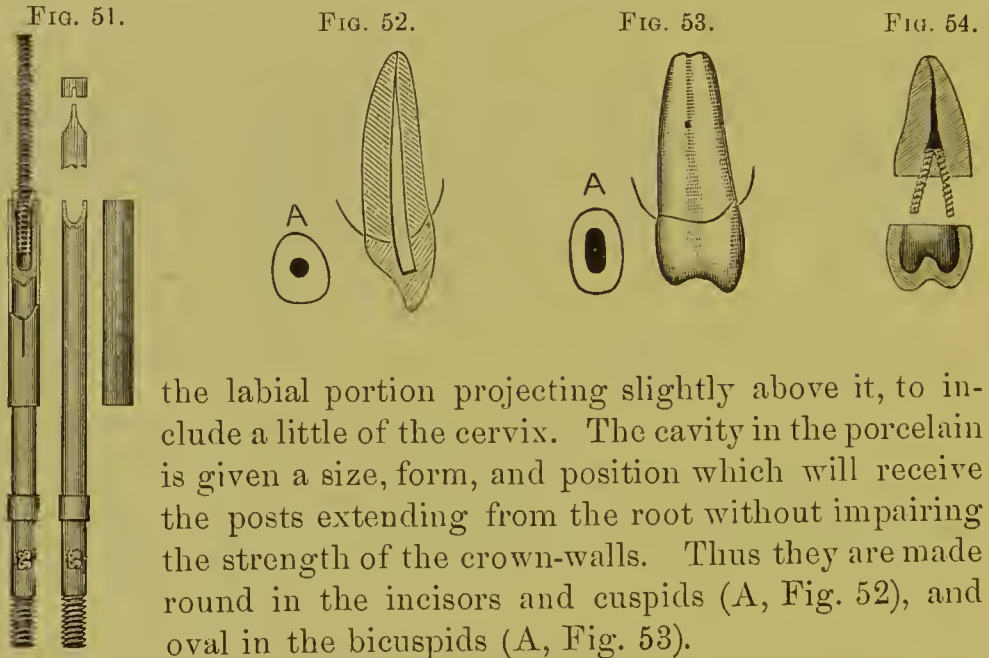


1849, also resembles the Gates-Bonwill, but has less concavity at the base. The crown is attached to the root by a headed screw (Fig. 50) or a screw with a nut.

The How screws and instruments (Fig. 51) are best adapted for use with these crowns.

## THE HOWLAND-PERRY CROWN.

This crown, which is similar in principle to one originally introduced by Dr. C. H. Mack, was devised by Dr. S. F. Howland and improved by Dr. S. G. Perry. It is attached like the Gates-Bonwill crown, with posts which are first cemented in the root and then in the crown. The base is given a curve approximating that of the line of the margin of the gum, with



the labial portion projecting slightly above it, to include a little of the cervix. The cavity in the porcelain is given a size, form, and position which will receive the posts extending from the root without impairing the strength of the crown-walls. Thus they are made round in the incisors and cuspids (A, Fig. 52), and oval in the bicuspid (A, Fig. 53).

The method of setting this crown is to first shape the end of the root approximately to correspond to the base of the porcelain crown, and then accurately fit the porcelain crown to the end of the root. Fit a post to the root-canal that will also fit the cavity in the porcelain. Partly fill the root-canal with oxyphosphate, and press the post in place with pliers. Fill the cavity in the crown with cement, press to place, and hold carefully in position until the cement sets (Fig. 54). Some prefer to cement the post first and the crown afterward.

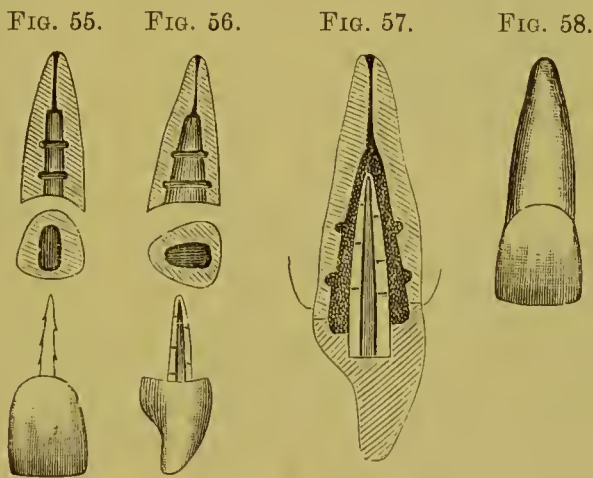
## THE LOGAN AND BROWN CROWNS.

These crowns have their platinum posts or pins baked in the body of the porcelain. In the Logan crown the base is made concave, to facilitate its adjustment to the end of the root, and

to give the cement a more reliable form. The base of the Brown crown is convex.

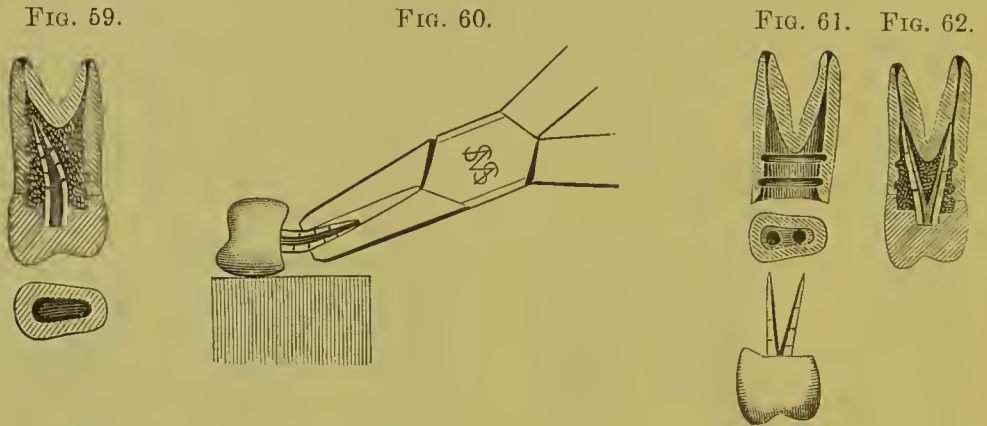
The preparation of a root for each of these crowns is, in general, similar to that for the Gates-Bonwill crown. The root-canal is enlarged, and shaped so that the post, if possible, at least at its point, will fit tightly. Gutta-percha or oxyphosphate is used for cementing in preference to amalgam.

*The Logan Crown.*—The Logan crown, now so extensively used, is the invention of Dr. M. L. Logan. The method of mounting is explained in all its details in the following article by Dr. W. S. How:



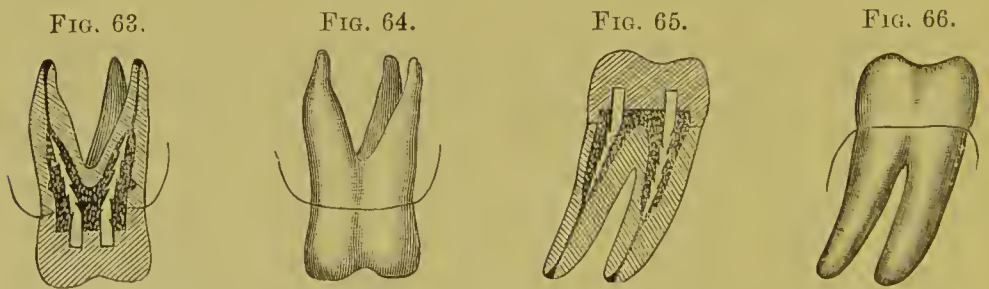
“Fig. 55 shows a superior right central root, an end appearance of the same, and a Logan crown, front view. Fig. 56 exhibits, at a right angle to the plane of the first figure, the same root, its end, and the Logan crown, side view. In both figures the root-canal is supposed to have been first drilled to a gauged depth with an engine twist-drill, No. 154, and then enlarged by means of a fissure-bur, No. 70, to the tapering form shown; the walls being subsequently grooved with an oval bur, No. 90. The enlarged section, Fig. 57, shows the crown adjusted on the root by means of cement or gutta-percha, which surrounds the post and fills all the spaces in the root and crown. Fig. 58 shows the completed crown. Fig. 59 exhibits a bifurcated bicuspid root, its end appearance, and a Logan crown adjusted to the root. Fig. 60 illustrates the best manner of bending the post. Fig.

61 shows a split post, and its adaptation to a bifurcated bicuspid root is seen in Fig. 62. Figs. 63 and 64 exhibit the mode of mounting the Logan crown on a superior molar root, and Figs. 65 and 66 the same crown in its relations to an inferior molar root.



“The preceding figures clearly present to the mind’s eye of the expert dentist the essential features of the Logan crown and the method of mounting it.

“The details are as follows: The root should first be measured through its canal from the cervical opening to the apical foramen. This may be accurately done with a gauge adjustable on a

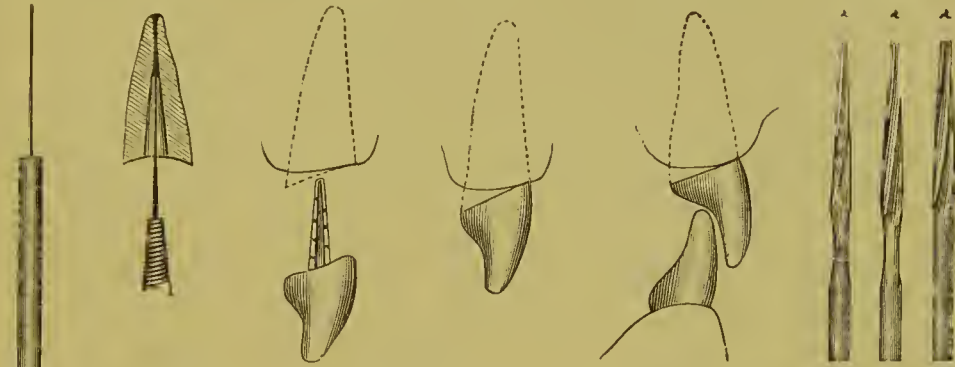


delicate canal-explorer (Fig. 67). The same device serves to measure the distance from the apex to which the canal should then be filled (Fig. 68). It also gauges the depth to which the drill may be carried. The proper degree of enlargement from the bottom of the drilled hole will, of course, depend on the observed size and character of the root. For preparing the roots, the Ottolengui root-reamers (Fig. 72) and facers (Fig. 73)



are very desirable instruments. The reamers are made in three sizes to correspond with the Logan pins. With a root-reamer

FIG. 67. FIG. 68. FIG. 69. FIG. 70. FIG. 71. FIG. 72.



of the appropriate size, the root-canal is enlarged to fit the pin along its whole length, and so hold the crown firmly *independently* of the cement. With a root-facer a labial slope is given to the root-end, so that the crown neck shall fit under the edge of the gum.

Fig. 74 shows the method and its result, and the cross-section shows how the cement incases the pin. The suitable preparation of the bifurcated roots of some bicuspid and of all the molars

FIG. 73.



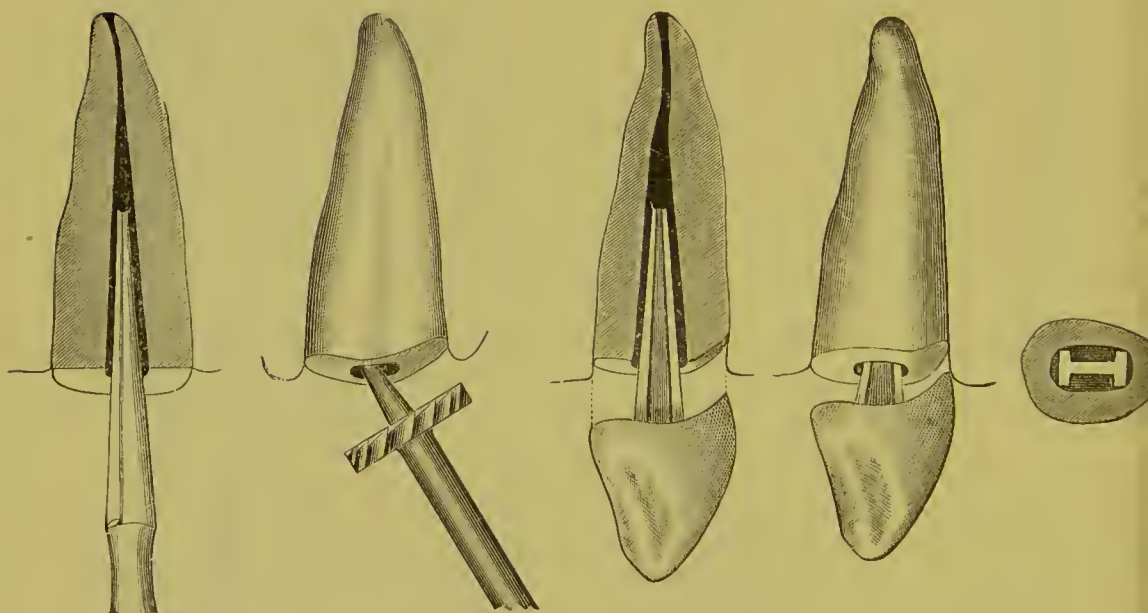
is a matter involving difficulties of an unusual character and requiring good judgment. The feasibility of splitting the post of a Logan crown to adapt it to the bifurcated root of a bicuspid is shown by Figs. 61 and 62. This example directs attention to the peculiar shape of the post, in which there is effected such a distribution of the metal that its greatest strength is in the line of the greatest stress that will in use be brought to bear on the crown, while the least metal is found at the point of the least strain; the applied part of the post being in outline nearly correspondent to that of the root itself. The root-canal is likewise conformably enlarged to receive the largest and stiffest post which the size and shape of the root will permit.

“The fitting of a Logan crown to a root may be done with a

wet stump-wheel in the engine hand-piece. A safe-side crown corundum-wheel (Fig. 75) can be used in the same manner. It also affords the greatest facility for the slight touches required to abrade the thin cervical borders of the crown, which may by this means be done without encroachment on the post.

“By the old method of adapting pivot-teeth to roots, the close fitting of the crown precluded the use of a plastic packing, because its thinness over the surface of the joint made the packing liable to break loose under the shock and strain of use. The recess in the Logan crown obviates this defect by providing

FIG. 74.



a receptacle for a considerable interior body of cement that will be deep enough to be self-sustaining internally, and yet allow the peripheral portions of the root and crown to approach each other so closely that, though only a film of packing remain, it will still be strong enough to insure the persistent tightness of the joint. This annular boss, if formed of amalgam, also adds strength in some cases to the mount.

“When enough of the natural crown remains, it is well to leave standing some of the palatal portion, and cut the root under the gum-margin at only the labial part, as shown by Fig. 69. The safe-side crown wheel is especially useful in such

cases (Fig. 76). Thus the labial joining of the root and crown will be concealed, and the other parts of the joint will be accessible for finishing and keeping clean (Fig. 70). The Logan crown may be ground until a large part shall have been removed for adaptation to the occluding tooth or teeth without seriously impairing its strength (Fig. 71). This crown also in such cases maintains the translucency which is one of its peculiar excellences, owing to its solid porcelain body, and the absence of a metallic backing or an interior largely filled with cement or amalgam.

“The distal buccal root of the natural superior molar is nearly always too small to receive a post of any useful diameter, and therefore the Logan superior molar crown has but two posts,

FIG. 75.

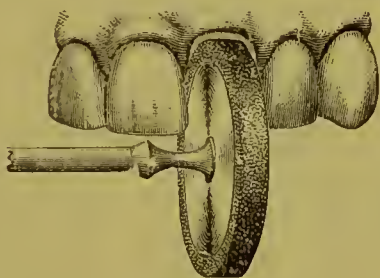
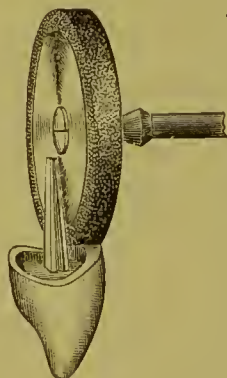


FIG. 76.



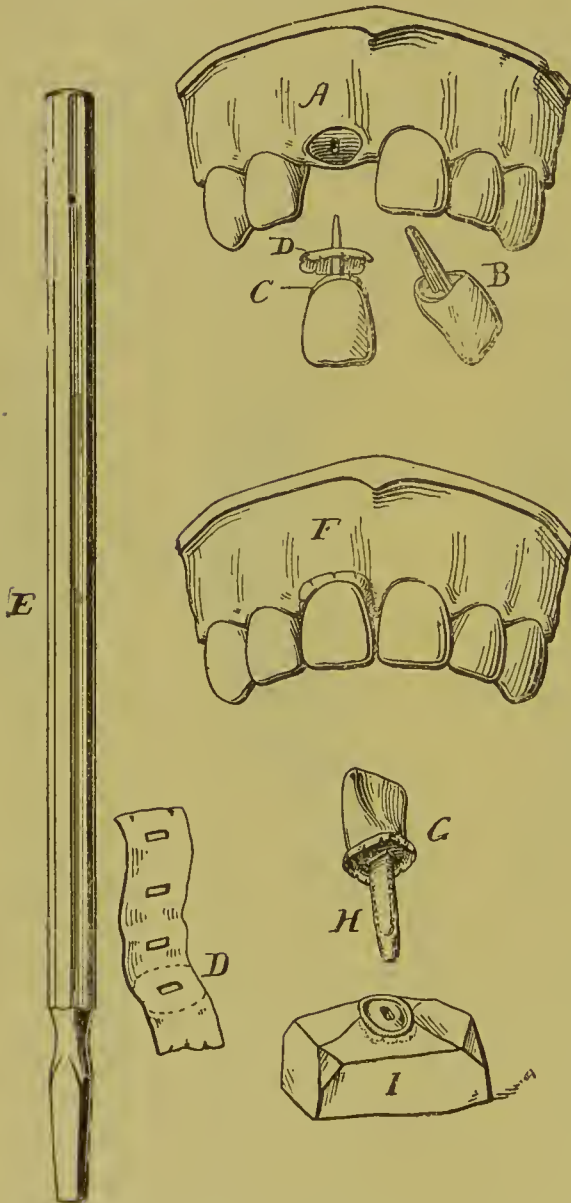
which like those of the inferior molar crown are square, and thus may be easily barbed, as may also the ribbed posts of the crowns for the anterior tooth-roots. These posts are large enough in all the Logan crowns to answer in any given case, and can of course be easily reduced to suit thin or short roots.

“Any of the cements or amalgams may be used in fixing these crowns, but good gutta-percha, softened at a low heat and quickly wrapped around the heated crown-post, which is at once seated in the root, forms the best mounting medium, and has the great advantage of permitting a readjustment, or, if need be, the ready removal of the crown by grasping it with a pair of hot pliers or forceps, and holding it until the gutta-percha is sufficiently softened.”

*Method of Fitting Logan Crown by Model of Natural Tooth.*

First prepare the face of the root to be crowned as desired, (A, Fig. 77), and having selected a suitable crown, B, bend the pin, if necessary, so as to make a proper alignment.

FIG. 77.



Next place a piece of paraffin wax around the pin next to the porcelain, C, then take No. 60 tin foil and trim a disk a little larger than the abutment, D, pierce the center of the disk with the crown pin or instrument shown in the margin, E, pushing the disk down until it touches the wax; place the crown on the root and force it to place, F, the wax driving the tin-foil disk to a perfect apposition with the abutment of the root.

Remove the crown with the wax, holding the tin-foil disk in position, and with a pair of sharp-pointed seissors snip the edges of the disk slightly all around. Place a small pellet of wax on the end of the pin, H,

then insert the pin up to the porcelain in quick-setting plaster, I: after the plaster hardens warm the crown and remove it, the snipped edges of the disk serving to hold it in position; clean off the wax and replace the crown on the model, and you have a perfect metallic-surfaced model of the abutment of the root to

which to grind with a perfect view of every surface of the root, the wax which was on the end of the pin allowing it to penetrate the plaster as the porcelain is ground away. By this method a Logan crown can easily be made to fit perfectly.

*The Brown Crown.*—Fig. 78 is a lateral view of a porcelain crown, with an iridio-platinum pin baked in position, invented by Dr. E. Parmly Brown. The pin has great strength at the neck of the tooth, where the strain is heaviest, and this strength is further increased by extending the porcelain up on to the pin.

Fig. 79 is a front view of the same crown, showing by the dotted lines the shape of the pin and the position which it occupies in the crown.

The pin is flattened laterally, affording a strong hold in the porcelain without bringing the pin too near the surface in thin

FIG. 78.



FIG. 79.

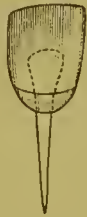

FIG. 80.

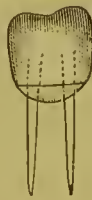
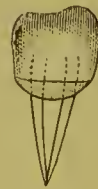
FIG. 81.



teeth, while it also permits alteration of the palatal surface of the crown in a close "bite" without risk of weakening the body.

Fig. 80 is a view of the bicuspid crown, in which a pin is provided for each root of two-rooted bicuspids.

Fig. 81 is a view of a bicuspid crown with the two pins pressed together, forming a single pin of great strength for a tooth with only one root.

The double pin in the bicuspids prevents the gradual loosening of the crown by the rotary movement of the jaws in mastication, which, acting on the two cusps, exerts such leverage as to sometimes turn and break down ordinary crowns where only one pin is used.

The roots are ground concave to fit the crowns with eorundum-points or a Willard countersink bur, and elose joints are made well under the gum, the pins being set with oxyphosphate

cement. The canal should be enlarged enough only to admit the pin, which should fit snugly throughout its entire length, the better to distribute the leverage exerted by the crown, and thus directly to increase the strength of the attachment. (For process of cementation, see article on "Insertion and Cementation.")

**REMARKS ON THE USE OF PORCELAIN CROWNS AND  
CROWNS WITHOUT COLLARS.**

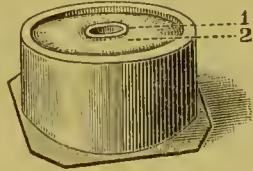
Porcelain crowns have some decided advantages. They are especially useful in many cases where an inexpensive or easily adjusted crown is required; or where some pathological condition limits the probable durability or permanence of any operation. In the insertion of porcelain crowns, the removal of the whole or a part of the natural crown, which could be utilized to some extent as a foundation by other systems, has given rise to various objections. If the natural crown is entirely cut away, the pin, or post, upon which almost the entire support of the artificial crown is thrown, exerts great leverage in the root-canal, when no band or brace is present on the exterior of the root to relieve the strain. With the whole force of mastication bearing directly upon these pulpless roots, whose disintegration is slowly but constantly progressing, the inevitable result can well be conjectured. Sooner or later they are fractured, and their usefulness as a foundation ended. Then, again, if porcelain crowns are attached with amalgam, the discoloration of the line of union with the root, if subsequently exposed, is disfiguring. These facts, and the lack of strength incident to some forms of construction, are the principal objections urged against porcelain crowns as ordinarily inserted.

## CHAPTER II.

### PORCELAIN CROWN WITH GOLD COLLAR ATTACHMENT.

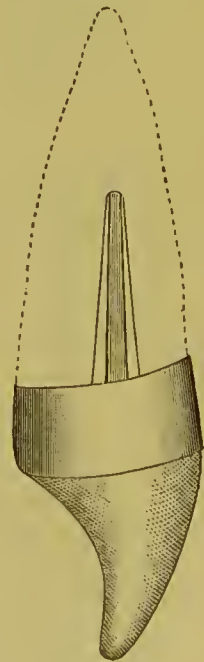
A GOLD collar, either seamless or soldered, can be used advantageously in combination with many of the porcelain crowns.

The root having been properly prepared, a collar is adjusted and adapted to it the same as for a gold collar crown. (See page 71.) The porcelain crown, the base of which should be fully as large as the end of the root, is then ground even with the cervical walls, and fitted into the collar, which should be trimmed and burnished to the form of the crown. Dr. Townsend's fusible metal die, used in the following manner, facilitates the application of a collar to a Logan crown (Fig. 82). Enlarge the root-canal to receive the Logan pin. Grind a Logan crown to fit, and articulate it. Construct a band of No. 30 gold (or of No. 32 crown-metal) wide enough to project beyond the end of the root say  $\frac{3}{32}$  of an inch. Cut a wooden peg about an inch long and taper one end of it to the general size and shape of the pin in the Logan crown. Place the band on the root, insert the peg in the canal, and fill up the band with Melotte's moldine or plaster, pressing it closely about the peg. Remove all together, and hold the die over the flame of an alcohol lamp to melt the fusible metal. When melted, place the socket side of the band or collar and wooden plug that enters the root-canal downward on the surface of the metal; cool and remove the moldine or plaster, and plug. This gives a tight grasp on the lower end of the band and does not allow it to change shape.



1. Socket. 2. Fusible Metal.

FIG. 82.



While fitting the crown into it, place the crown in the band, allowing the pin to enter the socket. Drive down with a mallet till the porcelain comes in contact with the metal. In this way you stretch the gold around the porcelain; now burnish down tightly. If this work is carefully done, the articulation should be the same as before the band was put on. Melt fusible metal to relieve the collar and crown. This method of setting a porcelain crown makes a strong operation.

Enough of the collar should be trimmed away at the labial portion to prevent too conspicuous exposure of the gold (Fig. 83).

This collar combination is available in very difficult cases, as, for instance, when a root is decayed upon one side far beneath the gum, as seen in Fig. 84.

FIG. 83.



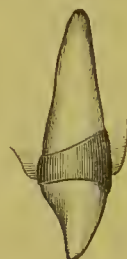FIG. 84.



FIG. 85.



FIG. 86.



Such an operation, when completed, would appear in vertical section like Fig. 85, and a view in perspective would resemble Fig. 86. The collar is also very useful wherever the root and crown are not made flush and smooth at every point, as, if practicable, they should always be.

#### METHOD OF MOUNTING A LOGAN CROWN WITH A BAND AND CAP.

Prepare the root in the usual way for banding. (See Fig. 87, front view, and Fig. 88, side view.)

Grind the abutting surface of the crown to fit the root under the free margin of the gum, along the labial face *only*. (See Figs. 87, 88, *a* to *b*.)

Cut the crown away slightly at the lingual surface, so as to



leave a space between it and the end of the root. (See Fig. 89, *c*.)

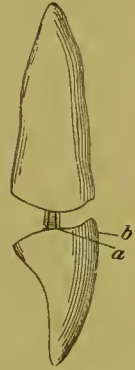
Make a band wide enough only to give a good hold on the root, but not to extend beyond the margin of the gum to fit the root, and trim off even with the end of it. (See Fig. 89, *d*.) After

FIG. 87.



fitting the band properly, remove it and solder a piece of pure gold plate, say about No. 34, on the outer end. (See Fig. 89, *e*.) This can be done quickly by placing the plate in the hand and pressing the band onto it with the thumb for a fit, then soldering in the flame of a Bunsen burner. Punch a small hole through the plate to take the pin in the crown, and replace in position on the root after trimming off the exposed edges. Now take a piece of

FIG. 88.



thin pure gold, say No. 34 or 36, with ears as shown in Fig. 90, *f*, punch a hole through it, slide it over the pin of the Logan crown, and burnish tightly to the base of the crown. (See Fig. 90.) Next warm the pin and place a sufficient quantity of Parr's

FIG. 89.

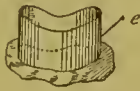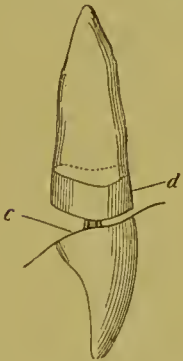
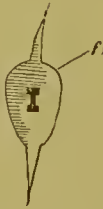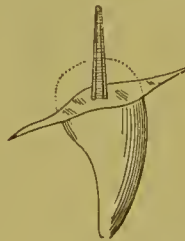


FIG. 90.



fluxed wax around it as shown by dotted lines, Fig. 90. Replace the Logan crown on the root (with the cap in position), force home until the labial edges of root and crown meet, obtain the proper alignment, and cool and harden the wax by using a napkin with ice-water. Then remove the crown and cap together, held in proper relative position by the wax. (See Fig. 91.) Trim off the surplus wax and invest. (See Fig. 92.)

Remove all the wax possible between the crown and the band, and flow 20-carat gold solder into the space. The wax which will necessarily remain, being fluxed, will carry the solder into every crevice and give the crown great strength. Finish the band and the soldered edges, and the result will be a strong and perfectly aligned crown.<sup>1</sup>

FIG. 91.

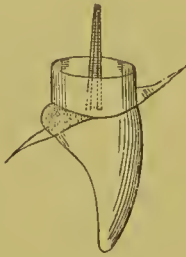
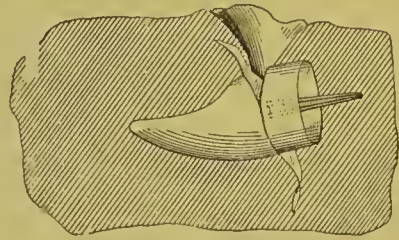


FIG. 92.



Dr. E. C. Kirk, of Philadelphia, uses for bicuspid and molars a Foster crown in combination with a collar (Fig. 93). A collar is made, and, on being fitted to the root, is cut narrow on the buccal side, and left wide on the palatal, so that it shall extend

FIG. 93.

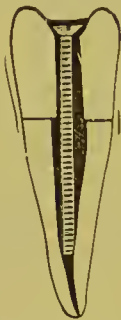

FIG. 94.



nearly to the cusp of the crown when finished (Fig. 94). (The seamless gold collars are well suited for this style of crown.)

The crown selected should have a somewhat greater circumference at the base than the collar, so that when ground down somewhat 'conically on its lingual and approximal surfaces, it can be tightly adjusted to the collar. If a crown smaller than the collar is used, a tight joint cannot be made. The screw is fitted so that it shall hold the crown in proper relations with the

<sup>1</sup>A method quite similar to that just shown, but omitting the band, was described by Dr. Gordon White in the *Dental Cosmos* for January, 1893.

root. The screw and crown are then removed, the parts dried, and the root-canal filled with a slow-setting oxyphosphate cement, mixed thin. The crown is then pressed into its position, the surplus cement flowing through the opening in the porcelain and filling up any interstices around or between the band, the root, and the crown. The screw is then driven into position, and when the cement is set perfectly hard the head of the screw or the nut on it is notched to form a retaining-pit, and the countersink of the crown filled with gold.

Dr. C. S. W. Baldwin caps the root and attaches a Logan crown in the following manner :

First, the root is shaped, the outer margin beveled about the thickness of the gold used, to give a proper form for close adaptation of a cap. Then an impression is taken and a die made in the gold seamless cap method (see Chapter VII). To strike up the cap, place No. 32 gauge gold plate on a cushion of lead, holding the die firmly on the gold where you wish to produce the cap, and strike until the required depth is secured before removing it. This drives the gold and die into the lead, forming a female die and a perfect-fitting cap at once, in less time than is occupied in describing the process. Trim the edges to fit the festoon of the gum, and drill a hole from the inner side for the pin, leaving the raggedness made by drilling to catch in the cement. Place the cap on the root and fit the porcelain crown accurately to it in the desired occlusion and position. A Logan crown can, with little grinding, be made to do good service (Fig. 95). A crown having the H-shaped pin, but square on the edge, like some of the early patterns of Logan or Bonwill crowns, would reduce the time of setting and give best results. Having polished the edges of the cap, the crown is adjusted as follows : Place oxyphosphate cement in the countersunk portion of the porcelain, and with the gold ferrule or cap in place, properly adjust the crown. When the oxyphosphate is hard, remove the crown and cap and solder the pin to the inside of the cap, with a very small amount of soft solder,—tin and lead,—using muriatic of zinc as a flux, a few blasts of the blow-pipe being all that is required. Fill the root-canal and the inside of the cap with oxyphosphate and press the crown to place (Fig. 96).

In most cases the gold band will be invisible and below the free margin of the gum. Cases may occur where the anterior teeth are prominent, and it will be necessary to cut away the top of the cap in front, allowing the porcelain to come directly in contact with the root, the band going deeper than in ordinary cases, which prevents the appearance of gold (Fig. 97).

Dr. Bonwill's plan is to cap the tooth with a platinum or gold cap having a slot, into which the pin passes as it is slipped on the root (Fig. 98). The crown is then fastened on the post and cap with amalgam.

FIG. 95.



FIG. 96.

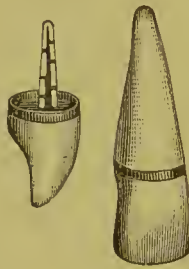
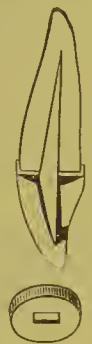

FIG. 97.



FIG. 98.

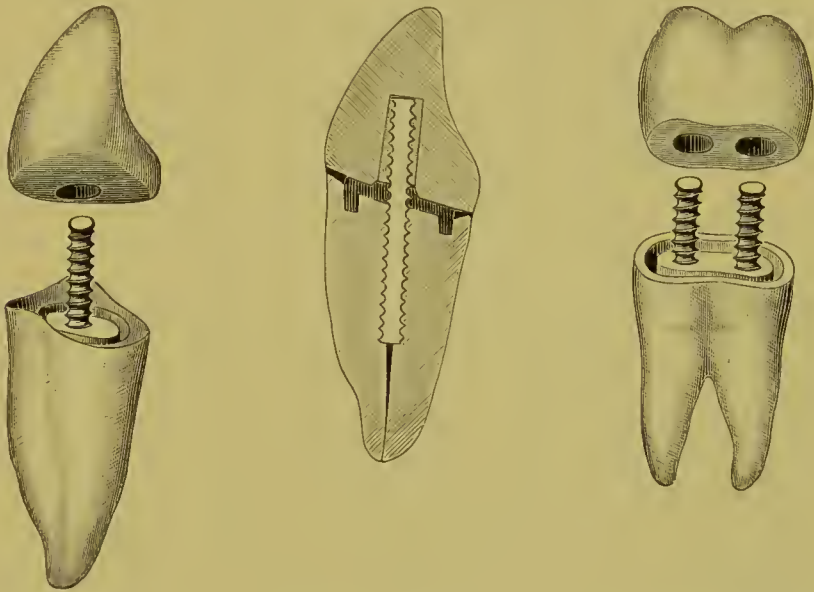


Dr. S. S. Stowell suggests the following method of applying porcelain crowns, with or without a countersunk base in which a post can be cemented, forming what he calls the "Simplicity Crown":

The end of the root is prepared in the usual manner and slightly countersunk. The porcelain crown (an ordinary pivot, an English tube tooth, or a Howland-Perry crown) is then fitted in position, and the glazed surface of the base and cavity removed to secure better adhesion of the cement. A How screw-post, preferably of iridio-platinum, is inserted in the root in alignment with the cavity in the crown. After the screw-post is set, a groove is cut on the end of the root, around the post, with small-sized engine-burs. This groove is filled with copper amalgam, the crown placed on the root, and the excess of amalgam pressed out. The crown is then removed, filled

with oxyphosphate cement, and pressed back in place. The excess of cement exudes on all sides, and carries with it any excess of the amalgam. The crown is held in position until

FIG. 99.

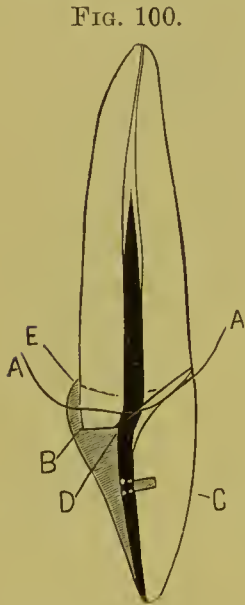


the cement sets. Fig. 99 shows an incisor and a bicuspid made by this plan, when ready for adjustment; also a sectional view of the completed incisor.

## CHAPTER III.

### PORCELAIN CROWNS WITH RUBBER OR VULCANITE ATTACHMENT.

FIG. 100 illustrates the formation of such a crown. The root, when prepared, extends at the palatal side a little below the line of the gum (A) at the point B. A plate tooth (C) is ground and fitted to the root. An iridio-platinum post is then fitted to the root, flattened slightly and bent at D, and riveted to the tooth. The proper alignments of the tooth and post to the root are then obtained, and they are invested and the post soldered and strengthened at the point D. The backing is then grooved and notched slightly, wax applied, the crown adjusted to the root, and the wax shaped so as to form a foundation and overlapping edge at the palatal portion (E), and also extend around the post up the canal. The crown is next removed, invested in a flask, packed with rubber, and vulcanized. In trimming and finishing, the rubber is allowed to form a partial band or collar around the palatal portion of the root, where it will not show. It is then cemented on to the root with oxyphosphate.



*A Temporary Crown.*—Fit in the root-canal a post of metal, preferably made of German silver wire. Let the post extend out of the canal about one-eighth of an inch and roughen the sides. Perforate a disk of the heaviest pattern tin with the post, and fit the tin to the end of the root. Fit a suitable two-pin rubber porcelain tooth to the disk. Groove out the porcelain, if necessary, to fit over the post. Wax the porcelain tooth to the disk and post, remove and invest in plain plaster of Paris. Remove the wax with boiling water, and, in its place, melt fusible metal and instantly press down firmly into the investment with a napkin over the finger; cool, remove, trim, and cement on the root with gutta-percha that softens at a low heat.

## THE GOLD SYSTEM.

### CHAPTER IV.

#### GOLD COLLAR CROWNS.

THIS style of gold crown includes those methods which consist in banding, capping, and hermetically inclosing with gold the end or the neck of a root, with or without any portion of a natural crown, for the purpose of securing stability to the artificial crown, preventing fracture of the root and decay of the parts, thus permanently preserving them. This method possesses much practical value as a preserver of tooth-structure and restorer of usefulness to the teeth, and affords excellent supports for bridge-work.

Collar crowns, the use of which has become quite general, have been described by many writers in the past. Dr. Wm. H. Dwinelle relates the application of the method to a crown with a porcelain front,<sup>1</sup> and Drs. W. N. Morrison<sup>2</sup> and J. B. Beers<sup>3</sup> tell of it in the construction of all-gold cap-crowns.<sup>4</sup>

Collar crowns of which the part that essentially constitutes the cap is constructed in sections, will be first described.

#### THE CONSTRUCTION AND ADAPTATION OF COLLARS.

Careful study of the different forms of crowns and roots, and of the anatomical structure and relationship of the contiguous parts, is most essential for the perfect construction and adaptation of collars, bands, or ferrules, as they are variously designated.

---

<sup>1</sup> *American Journal of Dental Science*, April, 1855.

<sup>2</sup> *Missouri Dental Journal*, May, 1869.

<sup>3</sup> Circular to dental profession, 1873.

<sup>4</sup> J. Patterson Clark, 1836.

Many devices and methods in use facilitate this operation, but its skillful performance can only be attained by study and practice, as is proved by the easy and perfect manner in which it is done by experts in crown- and bridge-work, who use no appliances but pliers and shears guided by an intuitive perception of the requirements of each case.

The collar is preferably made of coin gold, or of 22- to 23-carat gold plate. Pure gold plate lined with platinum is also used, and platinum<sup>1</sup> plate in special cases.

Gold plate of No. 28 to No. 30, or gold and platinum about 30, U. S. standard gauge, affords the requisite strength, together with easy adaptation to the form of the crown or root. The size of the cervix of the root or dimension of the natural crown to be capped, and whether it is to only effect restoration of the natural crown or to additionally give support to bridge-work, should govern the choice of the gauge of plate to be used. Cuspids and molars require a heavier plate than small laterals or lower centrals, and in all forms of gold caps the gauge should be increased when they are to support bridge-work. The natural crown or root having previously been properly prepared (see page 36), a strip of the metal is cut of the length required, and generally from one-fourth to one-half of an inch in width (Fig. 101). The end to underlap at joint is beveled with a file. The strip is then bent with suitable pliers (Fig. 102) to the average form (Fig. 103), any special deviation from such average being noted (Fig. 104), and to the size of the cervical periphery of the root of the tooth to be crowned.

It is then placed on the root and adapted as closely as possible to its form, with the upper edge of the metal pressing gently

FIG. 101.


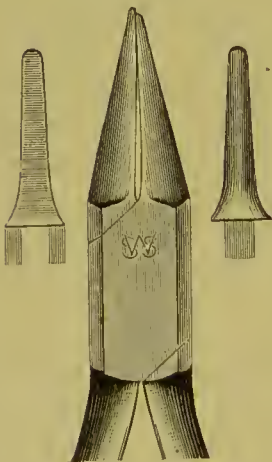


FIG. 102.



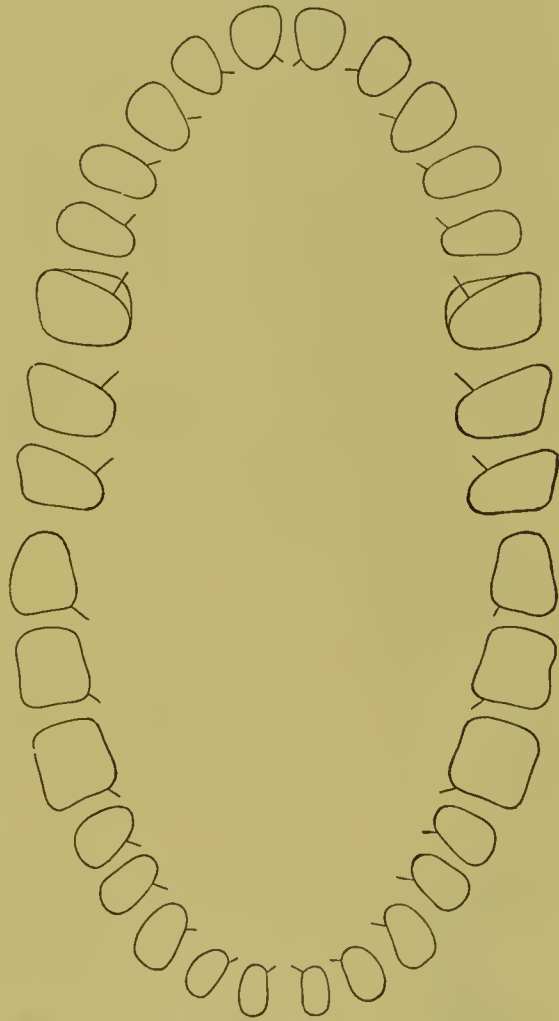
<sup>1</sup>The use of platinum plate, 30 to 32 gauge, is recommended to students, as collars formed of this metal are not apt to be melted in any of the soldering processes.



under the free edge of any portion of the gum it may meet. It is then removed and cut so as to allow the ends to lap over slightly. The adaptation to the root is then continued, during

which process the metal should be heated and chilled in water after each trial, in order to maintain the shape given to it. At the last adjustment to the root, the lap-over is marked on the metal with a sharp-pointed instrument. The joint is made at this mark by placing there the least possible quantity of solder, or, better, fluxed solder filings, and holding the collar with a clamp in the flame of an alcohol lamp or a blue gas flame. Another method is to grasp the seam of the collar at the cervical side with a clamp (see Fig. 148) or with common tweezers held by pliers, or, better still, by a small hand-vise (Fig. 105), and unite the extreme outer end of the seam by an atom of solder

FIG. 103.



The palatal side of the superior molars, in many cases, is of the large oval form indicated by the outer line to the form of the first molar. The small spurs indicate the points generally found the most suitable to make the joint.

or fluxed solder filings with a blow-pipe. The points of the elamp or tweezers prevent the solder from flowing along the joint. The cervical side of the collar is thus left open, which admits of the collar being slightly contracted, if desired, and accurately burnished to the root. The solder can then be flowed across the collar and the joint closed.

The collar is then slipped on the point of a small anvil, and the joint tapped down and trimmed level.

*A method by measurement is as follows:* The root is encircled with a strip of thin sheet copper, previously annealed, one-sixteenth of an inch or less in width, and the copper fitted to the cervix. It is removed, and cut so there will be a slight lap-over of the ends on the root, then again fitted to the root, and the position of the lap-over end marked on the copper. This little strip of copper, being soft and flexible, can be most accurately fitted to the root without inconvenience to the patient, and when removed shows the exact length and shape to cut the gold or platinum for the collar.

Upon a strip of the metal to form the collar, from one-quarter to one-half inch in width, is laid the copper pattern, and the exact length required for the collar is marked on the metal, which is then cut a trifle longer than the mark indicates (less

FIG. 104.

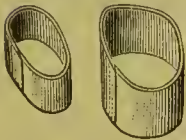
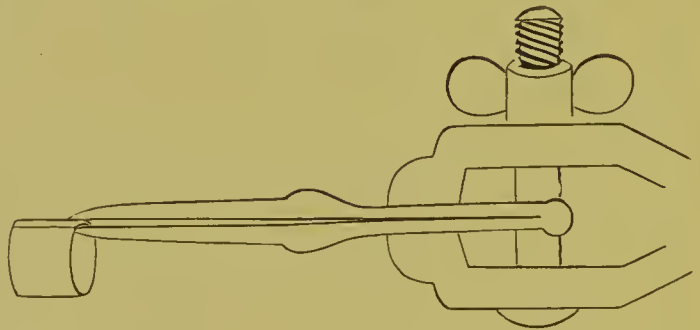


FIG. 105.



than one-sixteenth of an inch), to allow for an over-lap joint. It is then bent and the ends brought together, the outer end placed even or flush with the mark, and soldered as above described. The collar is next bent to the shape of the root, when it is ready to be adjusted. This method is simple and practical, and also economical, as it accurately defines the amount of plate required.

*To measure with a wire:* Form a loop of copper wire, about 30 gauge, by twisting the ends together with pliers. Slip the loop over the tooth or root, press the wire down under the gum-margin, and twist the ends with the pliers until the loop fits tightly at every point (Figs. 106 and 107). Slip off the loop, cut

it in the center and extend the ends lengthwise in opposite directions, as shown in Fig. 108. Then lay it on the surface of the plate of which the collar is to be constructed, and mark the length. Cut the metal beyond this mark sufficiently to allow for an over-lap; bevel and lap the ends to the mark and solder them.

When a mandrel is used in forming a collar, the size or shape is first taken with a wire. The wire ring is then carefully re-

FIG. 106.




FIG. 107.

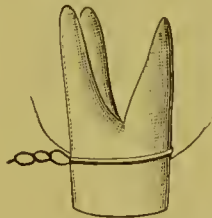
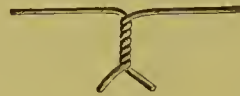

FIG. 108.



moved, laid on a piece of air-chamber tin, a piece of flat iron put over it, and with a blow from a hammer on the iron the wire is driven into the tin (Fig. 109). The wire ring is removed from the tin, slipped on a mandrel<sup>1</sup> that represents the form of

FIG. 109.

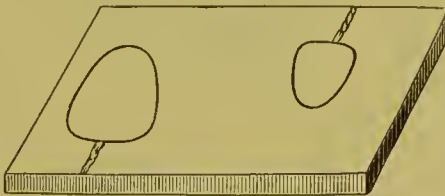
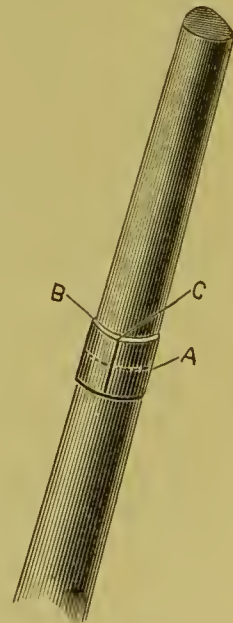


FIG. 110.



the root to be crowned, and pressed down gently as far as it will go without stretching the wire (A, Fig. 110). The distance from the end of the mandrel to the wire is then measured and marked on a strip of paper, and the wire removed. The gold to form the collar is then bent and shaped on the mandrel, with the edge which is to form the cervical portion (B) placed a little below the line of the wire (A), as shown by the measurement previously taken. The ends of the gold are beveled, slightly lapped, and the edge of

<sup>1</sup> A description of mandrels will be found in the chapter on the "Mandrel System."

the lap-over marked (C) and soldered. The collar is then shaped to the form given by the wire in the tin, after which it is ready for adjustment in the mouth.

When the collar has been formed, it is adjusted on the root and pressed or, by the aid of a piece of wood, one end of which is placed across the outer edges of the collar, tapped, up to the margin of the gum. A line parallel with the margin is marked with a sharp-pointed instrument on the collar (A, Figs. 111 and

FIG. 111.



FIG. 112.

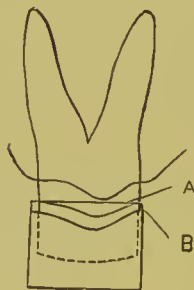
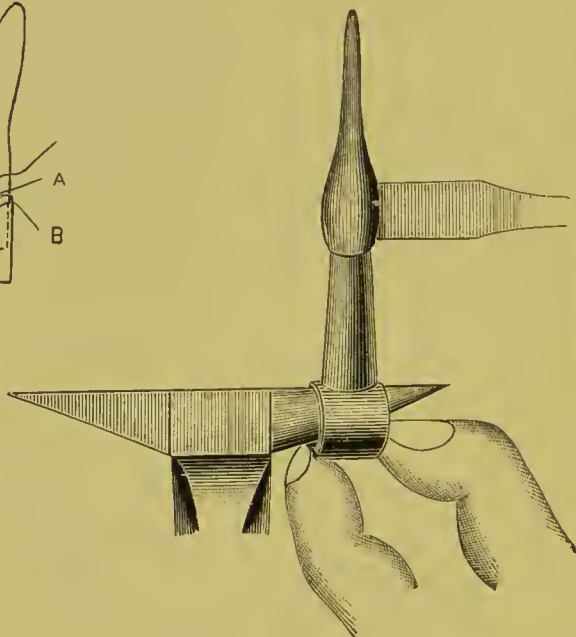


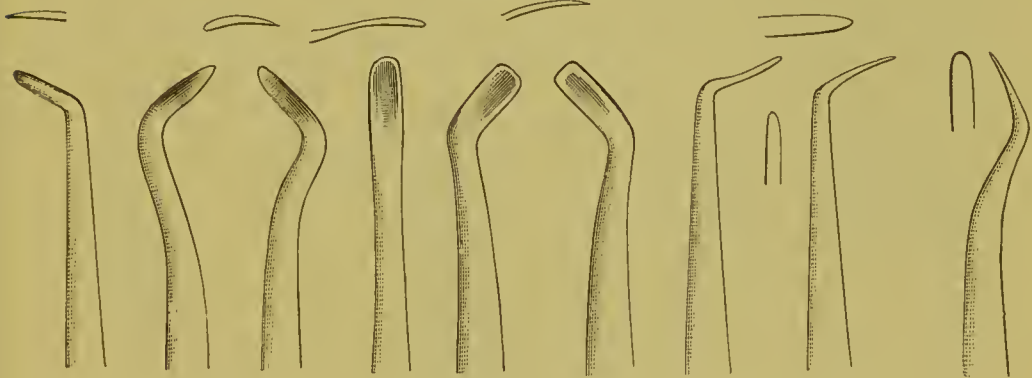
FIG. 113.



112), which is then removed, trimmed to this mark, readjusted, and again marked (B), and the process continued until the collar fits proportionately under the margin of the gum. If, on adjusting, the collar is found a trifle too small, it is easily enlarged by tapping the gold with a riveting hammer on an anvil as shown in Fig. 113. If, on the contrary, the collar should prove to be too large in circumference, the difficulty can be remedied by slitting the gold partly across the side opposite the joint, beveling and lapping the edges slightly, and soldering. The edge is then burnished to the periphery of the root. For this purpose a set of burnishers should be used especially formed to suit the different positions and avoid irritation of the margin of the gum. Such a set is illustrated by Fig. 114. Fine serrated foot-shaped gold-foil condensers can be advantageously used to flatten a stiff or angular point of a collar.

The application of local anesthetics, such as cocain, carbolic acid, or a mixture of tincture of aconite-root and chloroform, will lessen the pain attending the operation. Cocain is most effective in the form of a saturated solution in glycerin. The parts should be surrounded with a napkin, or with bibulous paper, and dried. Then a drop of the solution is placed on a slab, and a little at a time is carried on the edge of a thin bur-nisher and applied well up under and around the free margin of the gum of the tooth operated on. When this has been done, some of the excess of the solution, which will usually be found at the cervix, may be rubbed on the labial and palatal

FIG. 114.



sides of the gum. The patient should be directed not to swallow the saliva during and for some time after the application of the cocain. The anesthetic effect produced by this method will usually be found sufficient to partly or entirely divest the operation of pain, and of such duration as to seldom require repetition except at subsequent stages of the operation. Electrolysis will effect rapid diffusion of the cocain (cataphoresis), the solution of cocain being placed on cotton against the sides and margins of the gums.

A weak current of electricity should be used, the positive pole being applied to the cotton and the negative pole to the cheek or held in the hand of the patient.

## CHAPTER V.

### GOLD COLLAR CROWNS WITH PORCELAIN FRONTS.

#### INCISORS AND CUSPIDS.

THIS style of crown for incisors and cuspids, as originally made by Dr. C. M. Richmond, and with which his name has become associated, consisted of a cap for the root, formed of a band of gold capped with platinum on which was soldered a tooth with a slot in the center between the pins. Through this slot and the center of the cap a screw passed which entered into a cylinder previously screwed and cemented into the root-canal.

The form of gold collar crown in general use at present is, in principle, the same as what was formerly known in dentistry as a gold pivot tooth, with the addition of a gold collar for the root, and having the advantage of oxyphosphate for its cementation. These improvements enhance its value as a crown, and materially change the process of its construction. In making an incisor or cuspid crown of this style, the collar, having been formed, is trimmed even with the surface of the end of the root. With the collar in position on the root, a corundum-wheel is passed over the labial edge, along the margin of the gum, to level the gold with the root and render it invisible when the crown is finished. The side of the wheel used should revolve toward the root, and when necessary it should be reversed for that purpose, so as to turn the feather-edge of the metal of the collar over the end of the root. The work will then present the appearance shown in Fig. 115.

The cap is made by adapting the surface of a very thin piece of platinum plate to the outer edge of the collar, and uniting them with solder in the flame of a lamp (Fig. 116). The quantity of solder used must be very small, and it should be placed on the platinum outside of the collar, as otherwise it will flow over the inside of the collar and interfere with the fit of the cap.

The process is facilitated by first merely attaching the platinum, with the solder, to the edge of the collar, then readapting, and finishing the soldering. The platinum is then trimmed to the collar, and the cap adjusted on the root. The labial section of the surface of the cap is then burnished to the end of the root (A, Fig. 115). The root-canal having been slightly enlarged, a pin of round iridio-platinum wire, No. 16 or 17, U. S. standard gauge,—filed a little smaller for laterals or other roots which require it,—is slightly tapered at the point, fitted to an aperture made in the cap, and to the canal (B). The pin is then cut off even with the cap, removed, and temporarily laid aside.

A hollow wire, the open space in the center of which is very small, affords the advantage that it can be drilled out of the canal in a comparatively easy manner if for any reason it be-

FIG. 115.

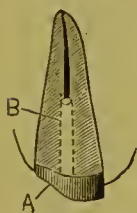


FIG. 116.

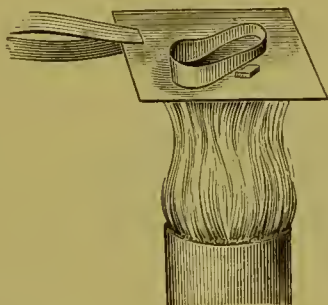


FIG. 117.

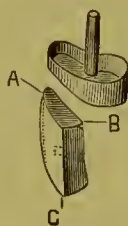
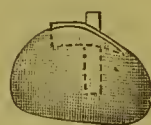

FIG. 118.



comes necessary to remove the crown, as the drill will follow the fine opening in the center of the wire.

A plain-plate cross-pin tooth, suitable in form and color, is ground and fitted in position on the cap. The labio-cervical edge of the porcelain (A, Fig. 117) should be flush with the edge of the collar, and meet the margin of the gum. It should be cut out at the base (B) so as to form a slight space just over the end of the pin. The tooth is then backed with very thin pure gold, gold lined with platinum, or pure platinum foil. Platinum gives a faint blue shade, and gold, or gold lined with platinum, if the gold side is toward the porcelain, a slight yellow shade. The backing should extend as far as possible under and between the tooth and the cap, as the solder will flow in and fill the space, thus giving strength and continuity of structure. This result can also be effected by shaping a piece of very thin platinum

foil to the base, extending from A to B, heating the porcelain, veneering with a mere film of resin and wax, and by pressure with a napkin or cotton causing the foil to adhere to the surface of the porcelain. The backing, if bent over the incisive edge (C) at an obtuse angle, will protect the porcelain in occlusion. A narrow strip of fine gold placed transversely across at that point previous to investing, and united in the soldering of the backing, will answer the same purpose. If the platinum backing used is of the nature of foil, it is advisable to rivet a small piece of gold plate over it on the back of the tooth, to insure against melting the platinum off the porcelain with the gold solder, which may occur if a pointed flame is used.

The tooth, when backed, is secured in position on the cap with a compound of wax and resin, and the whole adjusted in

FIG. 119.

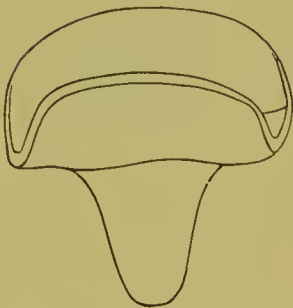


FIG. 120.

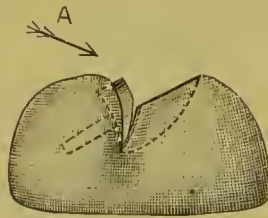
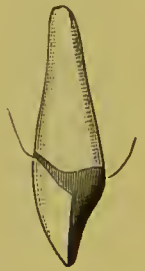

FIG. 121.



the mouth, then removed, and the pin, which has been laid aside, warmed and placed in position by passing the end from the inside of the cap through the hole into the wax attaching the porcelain crown. Another adjustment in the mouth is then made to determine the exact line for the pin, and the case is ready for investment.

After the fitting of the pin to the root and root-canal, as was described when the cap was formed, some prefer to solder it to the cap, for which purpose it should be adjusted in position and cemented with wax, then removed, invested, and soldered (Fig. 118). At this stage of the work, if desired, an impression can be taken in a small impression cup (Fig. 119) with either plaster or modelling composition. The cap should be removed in position in the impression. To aid this, a piece



of gutta-percha can be put on the end of the pin projecting from the cap. An articulation of the lower teeth should also be obtained. When the model is made, the pin is cut off even with the cap, and the porcelain tooth fitted as already described.

Calcined marble-dust and plaster, in the proportion of two parts of marble-dust to one of plaster, to which is added a pinch of sulfate of potassium to quicken the setting, makes what is considered to be the most suitable investing material for crown-work. The metallic section of the crown, when invested, should be left exposed at the sides, about as illustrated in Fig. 120, but the porcelain should be carefully covered. Pour boiling water on the investment when desirous of removing the wax before heating, but never attempt to remove it with an instrument. Many simply allow the wax to burn out. This is always done when fluxed wax is used. The investment should be first heated over a Bunsen burner, and then removed to a charcoal soldering-block. Gold solder cut in small pieces is then placed in and over the aperture between the porcelain front and the cap. By uniformly heating the entire investment, especially underneath and in the direction A, with a large flame from a gas blow-pipe, the solder is melted and flowed between the porcelain and cap. More solder should be added, and melted in this manner until the space between cap and porcelain is filled in and continuity of structure assured; but if an excess is used, it is apt to bulge or flow out over the collar. Additional solder is then placed on the backing and cap, and with a small pointed flame melted and flowed over these parts. Only sufficient gold should be used to insure restoration of contour. When soldered, after having been placed in acid and thoroughly divested of borax, the crown is ready for the finishing and polishing process. Fig. 121 represents the completed crown.

#### BICUSPIDS AND MOLARS.

Bicuspids crowned by this method will have greater strength if a portion of the palatal section of the natural crown is reserved (Fig. 23), and the band or collar made deep enough to cover it.

The end of the root is capped after the manner of the typical

central already described, one or two pins being used in the canals as required. A porcelain cuspid tooth, or a bicuspid front, is then ground, backed, and adjusted on the cap to represent the labial aspect, and secured with wax. The front and cap are then removed, invested, and soldered, after which they are adjusted in the mouth, and the occluding edge of the porcelain is ground clear of the antagonizing teeth (A, Fig. 122). With a die of suitable size representing the occluding surface of a bicuspid, as illustrated in Fig. 123, a piece of pure gold plate (about No. 30 gauge) is swaged (Fig. 124) and the cusps filled in with 18-carat solder or gold plate. The cap is then trimmed (Fig. 125), ground, and fitted to the occluding edge of the porcelain front (Fig. 126) in proper position as re-

FIG. 122.



FIG. 123.



FIG. 124.

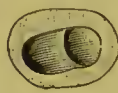


FIG. 126.

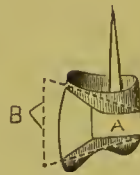


FIG. 127.

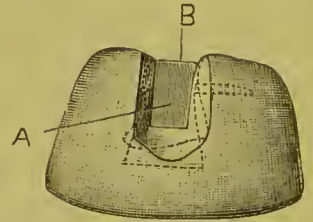


FIG. 125.



gards occlusion, and the wax attaching it is shaped to the contour of the crown (A). A piece of pure gold plate (B), not over 34 or 35 gauge, is then adjusted on each side of the crown, which is invested (Fig. 127). The long ends of the two side-pieces of gold plate are designed to retain them in position, as the investing material should be removed from the portion inclosing the sides of the crown (A). Mica—isinglass—is recommended for this purpose, and is preferable to metal. In the process of soldering, the solder is placed in the aperture at B, and the flame of the blow-pipe being directed on the exposed sides of the gold at A, the solder is flowed into every part, forming perfect continuity of structure of the metallic portion of the crown. If this aperture at A is left open without the gold or mica, and the solder is first flowed in the interstices as described in soldering an incisor crown, the remaining solder necessary to contour the part can be added, if the pointed flame

is used and not applied to the other portions of the crown and investment. In finishing, the surplus gold is trimmed to the contour of a bicuspid tooth. Fig. 128 represents the finished crown.

The method described produces a perfect and artistically formed crown, but simpler and quicker methods are practiced. One of these is to build up the palatal cusp with several pieces of gold plate, which have been previously melted into the form of small balls and flattened out on an anvil. These, laid in position and united with solder, are shaped in finishing to represent the palatal cusp (Fig. 129). The porcelain front should be backed so that the solder can be flowed over its occluding edge.

FIG. 128.

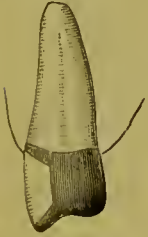

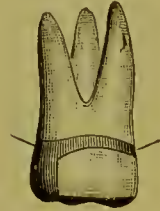
FIG. 129.

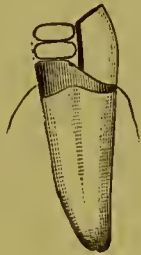

FIG. 130.

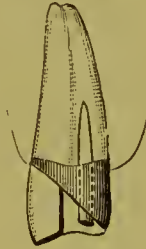

FIG. 131.



Another method is to extend the palatal part of the collar down as shown in Fig. 130, and then fill in the space with solder. In finishing, the gold is trimmed to the form of the crown. In this and in the method just previously described, the porcelain front can be soldered and the palatal cusp formed in the one investment.

The method of construction of molar crowns with porcelain fronts is similar to that for bicuspids (Fig. 131).

*Dr. Stowell's Method.*—A porcelain crown can be soldered on the cap, according to Dr. S. S. Stowell's method, as follows:<sup>1</sup> "The tooth used may be a Logan or an E. Parmly Brown crown or an ordinary countersunk tooth, but in most cases the Logan crown is preferable. The pin is first cut off, then the tooth is ground to fit on the cap, the porcelain and the stump of the pin being reduced alike evenly and smoothly; after which the stump of the pin is ground with a small wheel below the surface of

<sup>1</sup> *Dental Cosmos*, vol. xxix, page 641.

the porecelain (Fig. 132). The tooth is then invested (Fig. 133) and pure gold fused on to the platinum pin, and while in a fluid state it is with a wax spatula 'spatted' down flat (Fig. 134). The gold is then filed or ground down even with the porcelain, and at the palatal border the tooth is ground to bevel baek until the gold is reached (Fig. 135). The tooth is then secured in place on the cap with wax cement (Fig. 136), the case invested,

FIG. 132.



FIG. 133.



FIG. 134.



FIG. 135.



FIG. 136.



and heated until the wax has melted and burned out. A small clipping of thin platinum plate is crowded into the opening (Fig. 137) caused by the grinding of the bevel on the crown. The clipping of platinum serves as a lead for the solder, which follows it down into the countersunk cap, around the ends of the

FIG. 137.




FIG. 138.

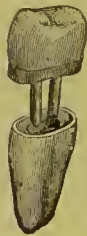

FIG. 139.



FIG. 140.



FIG. 141.



dowels, and finally attaches itself to the pure gold already attached to the stump of the platinum pin. Fig. 138 represents the completed crown. A sectional view of a like crown (Fig. 139) also shows the organization in detail. A porcelain crown can be used to represent any of the teeth in the same manner. (See Figs. 140 and 141.)”

## CHAPTER VI.

### ALL-GOLD COLLAR CROWNS FOR BICUSPIDS AND MOLARS CONSTRUCTED IN SECTIONS.

THE root and crown having been properly prepared, the collar is formed and adjusted as described at page 72, and the edge toward the antagonizing teeth trimmed, to fully clear them in occlusion. The collar is then slightly expanded toward the occluding surface for better contour. A close knuckling can be insured by seizing the collar and the approximal tooth in the manner shown in Fig. 142. The crown is removed, filled with

FIG. 142.

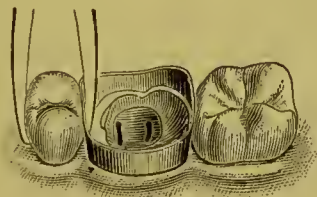
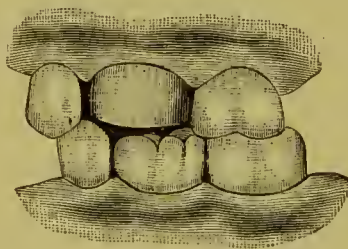


FIG. 143.



plaster, and adjusted in position. Fig. 143 represents a typical case. The antagonizing teeth, having been covered with a piece of tin foil, are then occluded until the plaster sets. The collar is then removed. The surface of the plaster inside the collar will give the impression of the natural root or crown, and the outside that of the antagonizing teeth. The latter furnishes an outline to form the grinding-surface of the crown.

The plaster is then trimmed and shaped to represent the cusps and fissures of the natural tooth, enough of the surface being removed to allow for the thickness of the plate that forms the cap. Readjustment in the mouth will show the accuracy of the occlusion.

A small tube of copper, a trifle larger in circumference than the crown under construction, is filled with Melotte's "moldine,"

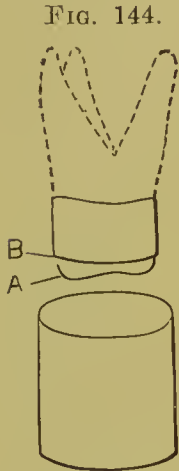


FIG. 144.

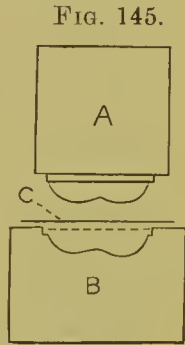



FIG. 145.

A, Fusible die.  
B, Counter-die.  
C, Plate to form  
the cap.

and the surface rubbed with soap-stone. An impression of the lower portion of the form of the crown A to the line B, Fig. 144, is then made in the moldine, and a strip of paper wound around the tube, extending about an inch above the edge. Fusible alloy is then melted and poured into the mold, thus forming a die. An indentation is made with a punch in a block of lead, into which the die, when cold, is hammered slightly

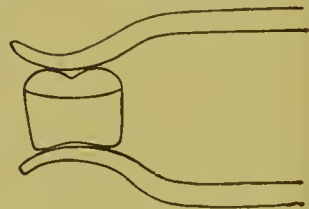
beyond the impression of the edge of the collar. By this method a die and a counter-die (Fig. 145) can, with practice, be completed in five minutes. With this die the cap is then struck up on the lead from a flat piece of plate and fitted to the collar. A little of the surface of the plaster in the collar may have to be removed, if, on trial in the mouth, the cap is found a little flush. The crown, with the plaster still inside the collar, is fixed in a soldering-clamp constructed in one of the forms shown in Figs.

FIG. 146.



The frame of this clamp is formed of iron wire, and the support for the crown of plaster, asbestos, and marble-dust.

FIG. 147.



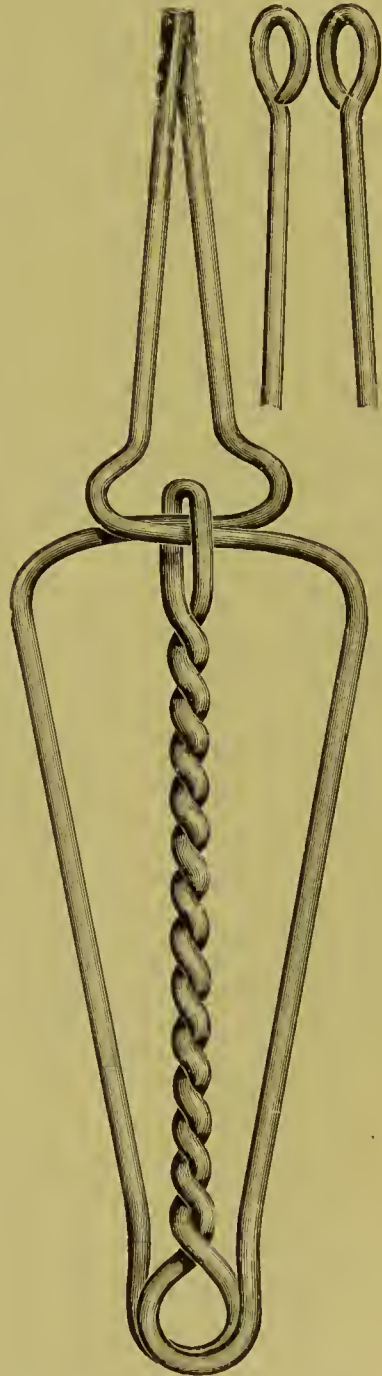
146, 147, or 148, which holds the parts together and permits the flame to reach all points. The parts of the crown can also be held together for soldering with iron wire in the form of a loop passed over the grinding-surface, against the sides of the collar, with the ends twisted together over the aperture of the neck and

the crown. No more solder should be used than the contour requires, as an excess necessitates additional labor in finishing.

Another method, if the crown is not to be contoured with the aid of the solder, is, when the cap is struck up, to melt solder into the cusps, and then adjust the cap in position on the collar, for which purpose some of the plaster underneath the cap must be removed. A jet of flame from the blow-pipe is then thrown upon it in such a way as to cause the solder to flow down on the edge of the collar and fill the seam from the inside. The objection to this method is that, when a large portion of the natural crown is inclosed by the gold, the solder will occasionally alter the inside form of the fitted cap, thereby interfering with its adjustment, which is a defect troublesome to correct.

Still another method is to adjust the collar in the mouth, and, with a small piece of wax or impression-compound pressed upon it, to take an impression and "bite," in which the collar will be imbedded and removed. With this a model and articulation are made and the form of the cap shaped in wax. An impression of the cap is then made, either in moldine in a soft state in a tube, or in plaster, and a die cast. The cap is stamped on this die, then adapted to the collar by the model, and the crown finished. This method, which was first made known by Dr. N. W. Kingsley, is adopted when it is preferable to construct the crown between the visits of the patient.

FIG. 148.



In utilizing a tooth as an abutment in bridge-work when all or nearly all of the occluding surface of the natural crown is present, a practical method of construction is to mark the outline of the natural crown on the inner surface of the collar; then remove the collar and trim so as to leave a border of about one-sixteenth of an inch outside the mark. This border is then thinned with a corundum-wheel, and slit as seen in Fig. 149. The collar is next adjusted on the crown, and the slit border bent over to the form of the occluding surface, to which it is burnished. A piece of pure gold plate, about No. 34 gauge, is then placed on the occluding surface of the tooth and adapted to

FIG. 149.

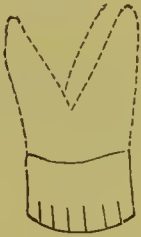

FIG. 150.

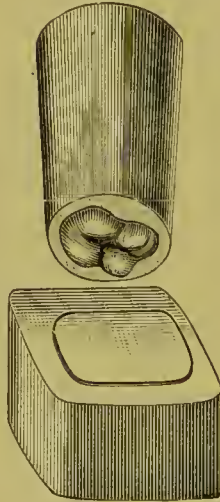
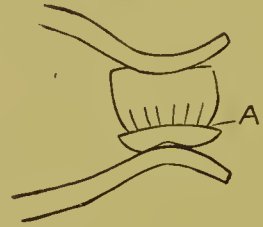


FIG. 151.



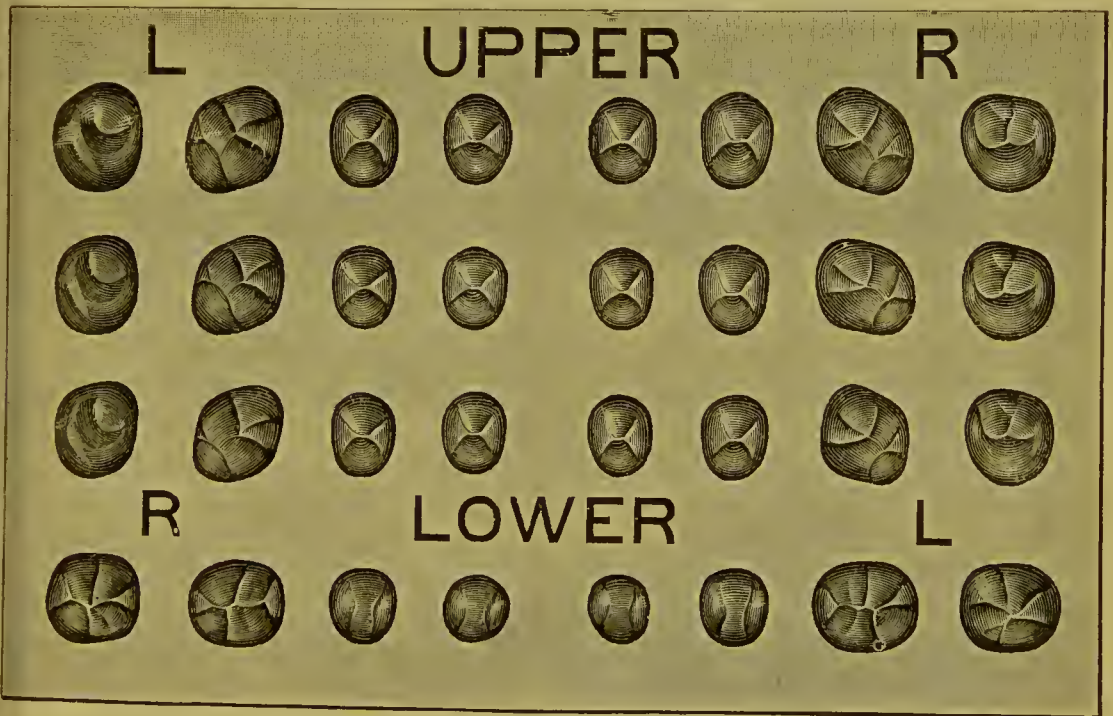
it and to the collar. The gold may be first struck in the form of a cap by laying it on a block of lead and hammering into it a die corresponding to the surface of the tooth to be crowned (Fig. 150). The antagonizing teeth are then occluded on the gold, which is thereby pressed to form to articulate with the occluding surfaces. Enough of the occluding surface of the tooth crowned should always be removed to allow for the thickness of the gold covering its surface. The collar and cap are next removed and soldered. This is done by resting the collar on the cap, which is held by a pair of tweezers, or by clamping the cap and collar together and placing the solder in small pieces around the collar outside the cap, at A, Fig. 151, and soldering



by holding in a blue gas flame. Only sufficient solder should be used to join and fill the seams, so that it will not interfere with adjustment on the natural crown.

The methods described insure a perfect occlusion of the crown with the antagonizing teeth. In the absence of antagonizing teeth, or when the general form of the grinding-surface permits it, the cap can be struck up with a die similar to the one shown in Fig. 150. The cusps are then filled in, and the edges of the inner surface of the cap ground level on the side of a corundum-

FIG. 152.




wheel. The entire circumference of the edge of the collar is also leveled, and the cap adjusted, clamped, and soldered. If the cusps of the cap are filled in with solder, it will flow down and join the collar on the inside; if with gold plate, the cap and collar must be joined with solder either on the inside or outside.

When the mere form of the grinding-surface for the crown is all that is required, an impromptu one may be made by indenting a piece of pure or soft gold plate with the round end of

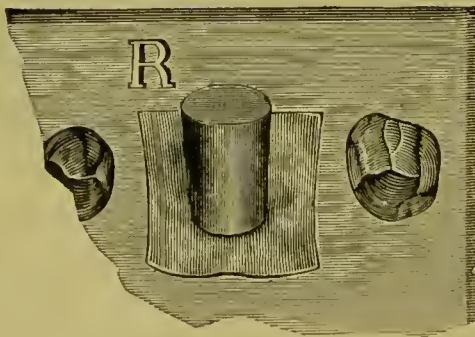
an instrument-handle to form the cusps, resting the plate on a flat surface, and creasing between the cusps with a burnisher.

Metallic caps, or forms of the occluding surfaces of teeth for use in constructing crowns, are quickly made with the die-plate



shown in Fig. 152,<sup>1</sup> "in which are four groups of intaglio dies representing the peculiar cusps of the bicuspid and molars. The hubs A, B (Fig. 153) are of the sizes shown, and are made of an alloy composed of tin one part, lead four parts, melted together. The mold C should be

FIG. 154.




warmed, the metal alloy poured in every hole, and the overflow wiped off just before the metal stiffens: this will make the butts of the hubs smooth and flat. After a minute or two the mold may be reversed, the hubs shaken out, and the casting process continued until a considerable number of hubs shall

have been made. In Fig. 154 a molar hub is shown in place on a piece of No. 32 gold plate, which lies over the upper right first molar die. A succession of blows on the hub with a four-

<sup>1</sup> *Dental Cosmos*, vol. xxix, p. 482.

pound smooth-faced hammer will drive the plate into the die, and at the same time spread the hub metal from the die center to its circumference, in such a manner that the plate will be perfectly struck up with the least possible risk of being cracked. The flattened hub is seen in Fig. 155, which also shows at D the obverse of the struck-up hub, and at E the cameo of the struck-up plate, having every cusp and depression sharply defined. The counter-die plate (Fig. 152) is made of a very hard cast metal, which will admit of the striking up of many crown plates by the means described, if the crown plates be not too thick and stiff. Of course they should be annealed

FIG. 155.



before they are placed over the die. If a cusp or fissure should chance to crack in hubbing, a small piece of plate may be struck up over the fissure, and then soldered to the original cap.”

The methods which have been described for the construction of all-gold bicuspid and molar crowns are those generally adopted in practice. Of others, Dr. J. J. R. Patrick’s method<sup>1</sup> consists of first forming a very narrow collar and telescoping it with a seamless cap of the form of the crown, and soldering along the line of the cap to the collar.

Dr. E. P. Brown’s method is to make or select a metallic die for the crown to be formed; then place a piece of pure gold plate, about No. 31 gauge, on the flat surface of a block of lead, and gradually stamp the die downward into the gold to about half the depth of the intended crown. The gold is then re-

<sup>1</sup> Dr. Patrick’s crown-work methods and the principles upon which they are based are set forth in a paper published in the *Dental Cosmos* for October, 1888, page 706.

moved, and each side of the unswaged portion slit and adapted to the form of the die, the full length of the crown, which is then adjusted in the mouth, the edges of the gold trimmed to the proper form, and the slits soldered.

Dr. M. Rynear's crown is of the same general character and construction as Dr. Brown's, except that a seamless cap is used to form the crown, instead of a flat piece of plate.

*All-Gold Crowns for the Incisors and Cuspids.*—When the teeth are short and the incisive edges flat or abraded, and the all-gold crown required is to correspond in form or be only a little longer, the gold collar, after being fitted to the tooth, is slit on the palatal or lingual side, and bent and burnished to it. The collar is then removed and the seams soldered together. This

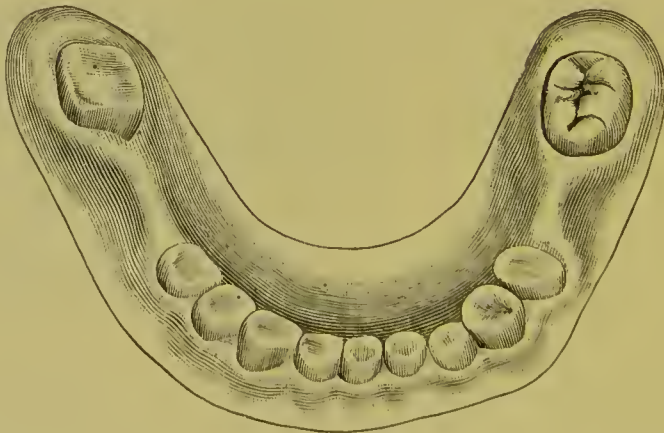
FIG. 156.



is best done by holding the collar in a Bunsen gas flame, with the solder placed in position in very small pieces, and only sufficient in quantity to join the seams. The collar is next adjusted to the tooth, and the gold at the incisive edge trimmed even. A flat, thick piece of gold plate or clasp-material is soldered across the incisive edge to form and inclose that portion of the crown.

When the crown required is of the normal form, the collar when properly fitted should be removed at the palatal section, as shown in Fig. 156. The edge of the gold is then chamfered,

FIG. 157.



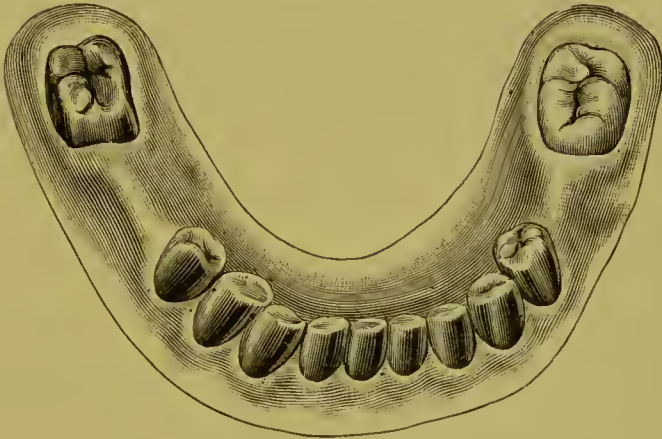
and bent and burnished over the incisive edge and sides, close to the natural tooth. To this open section is next adapted a flat

piece of gold plate, the collar is removed, and the parts are soldered together. Fluxed solder filings can be melted in the interior of the incisive edge to increase its thickness.

A fusible metal die of the natural tooth is a material aid in the construction of this style of crown.

Fig. 157 represents a case of abrasion of the lower teeth, to

FIG. 158.



which all-gold crowns have been applied, as shown in Fig. 158. In such cases, owing to the attrition of the occluding teeth, the cap forming the occluding surface should be constructed of heavy gold and platinum plate. An artificial plate replaces the upper teeth.

## CHAPTER VII.

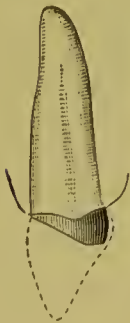### THE GOLD SEAMLESS CAP CROWN.

THIS method consists in the use of a gold seamless cap for the construction of the required root cap or crown.

#### INCISORS, CUSPIDS, AND BICUSPIDS, WITH PORCELAIN FRONTS.

Incisor, cuspid, and bicuspid crowns with porcelain fronts are constructed by this method as follows: The natural crown is ground down to within about one-eighth of an inch of the gum at the palatal wall, or enough to clear the antagonizing teeth when occluded, and slanting from the posterior edge of the pulp-chamber to the cervico-labial edge of the gum and slightly under its margin if it is desirable to conceal the joining of the crown with the root. The sides are shaped the same as for a collar crown (Fig. 159). A die of the end of the root is then made. For this purpose an impression of the part is taken with

FIG. 159. FIG. 160.



gutta-percha on the end of a piece of wood trimmed to the proper size, or, better still, by placing some plaster of Paris with a little sulfate of potassium, mixed to the consistence of a paste, in a tube formed of a strip of copper about one and one-half inches in length and three-eighths of an inch in diameter, cut out on the sides to the depth of half an inch, with the flange for the palatal side shortened<sup>1</sup> (Fig. 160). The impression thus taken will be confined almost entirely to the end of the root to be capped. When gutta-percha is used, it is cooled and dried perfectly. A strip of paper is tied around the

<sup>1</sup> See article on "Molds and Dies," which describes how to make a tube without soldering.

wood or tube, and a die cast with the fusible metal. The cooling is hastened by immersion in a glass of water. When cool, the die is removed from the mold, and the metal is trimmed, with file and chisel, a little deeper than the gum has permitted the impression of the root to be taken, and without altering the form of the end of the root (Fig. 161). A counter-die is then made by punching a hole in the surface of a block of pure lead, and with a few blows of a hammer driving the die into it.

A cap of gold can be formed by placing a piece of gold plate (preferably pure, No. 30 U. S. standard gauge) of suitable size upon a block of lead, and with an oval-shaped punch one-fourth

FIG. 161.

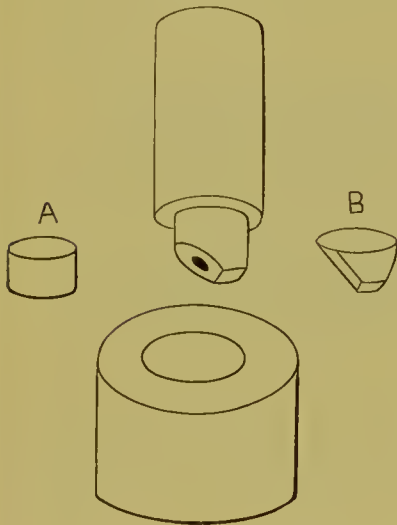


FIG. 162.



FIG. 164.

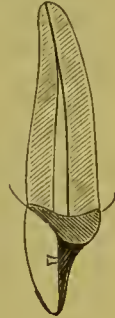

FIG. 163.



of an inch in diameter gradually driving it into the lead until the gold has assumed the shape of a cap about a quarter-inch in depth (A, Fig. 161). The gold should be withdrawn from under the punch and annealed several times during the process. Caps can also be made with a stamping-press. (See page 98.)

The cap is then annealed and swaged on the die to the form of the end of the root (B, Fig. 161). The palatal portion of the cap should be allowed to go well up under the free edge of the gum, and at the cervico-labial edge it can be, if preferred, cut out to the edge of the root. In the process of adjustment, the edges which fit under the gum should be marked and trimmed as directed in describing the construction of a collar crown, and

then burnished close to the sides of the root and into the orifice of the root-canal, forming a perfect-fitting seamless cap (Fig. 162). An iridio-platinum pin is then fitted in the root-canal and soldered to the cap (Fig. 163), or afterward adjusted as in the construction of the gold collar crown with porcelain front (page 75), with which operation the remainder of the process of construction is identical. Fig. 164 represents the completed crown.

The advantages of this style of crown are, simplicity, as the formation of a collar is avoided, and strength, as a large portion of the natural crown can be left at the palatal side. This affords a stronger and more reliable foundation than can be obtained at any other point, as the direction of the force in mastication is forward at an angle with the line of the root, and although the gold of the cap, where it encircles the root at the cervico-labial edge, is entirely removed, the crown is still held securely.

In a paper on the subject of preserving and utilizing this part of the tooth, Dr. W. F. Litch, of Philadelphia, describes a crowning operation,<sup>1</sup> in which he constructed the cap of platinum by slitting a piece of the plate in a number of places, adapting it to the end of the root, and then soldering the whole together.

This operation is not, however, so easily or so satisfactorily performed as the method above described, in which platinum, if desired, can be used instead of gold, and the soldering done with 22- or 24-carat gold. In some respects pure platinum is preferable to gold in capping roots, as it is less likely to be affected by the secretions of the mouth.

#### ALL-GOLD SEAMLESS BICUSPIDS AND MOLARS.

All-gold seamless crowns for bicuspids and molars that will accurately fit the natural crown and root, and occlude properly with the antagonizing teeth, are easily and quickly formed, if sufficient of the natural crown remains to admit of temporary restoration of its contour with gutta-percha or any other suitable plastic material. The sides of the natural tooth should be removed at least the thickness of the plate to be used. An impression of the restored tooth is then taken in plaster or gutta-percha in a tube, as explained on page 90, and a die then

<sup>1</sup>*Dental Cosmos*, vol. xxv, No. 9, page 449.



formed of fusible alloy; or a plaster model can be made from an impression of the tooth taken in wax, and a mold obtained from the model with moldine. Additional preparation and shaping of the natural crown to receive the artificial crown can then be proceeded with.

Where the natural crown is very badly decayed or broken down and the method just described is not practicable, the portion of the natural crown or root remaining should be shaped and prepared to receive an artificial crown. Then the form of the cervix is ascertained with a wire as described on page 70, and an impression of the parts taken in wax, and the wire form, the twisted ends having been shortened, is carefully adjusted on the wax at the cervical line. The plaster model, when made,

FIG. 165

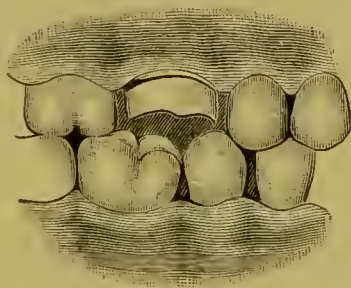
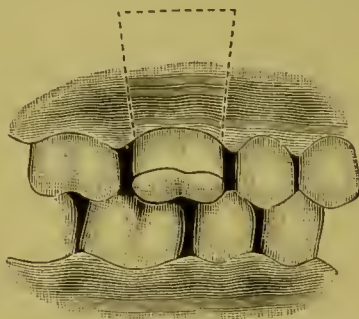


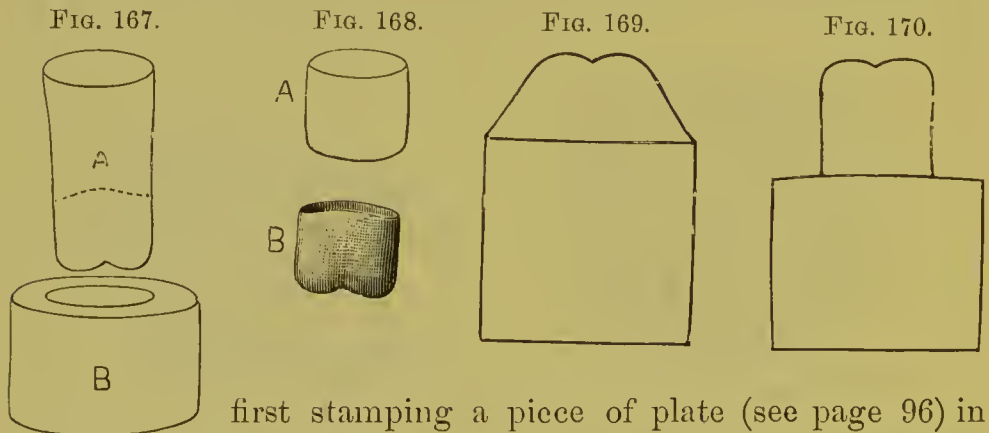
FIG. 166.



will show the wire slightly imbedded in the plaster. The plaster should be trimmed to the inner edge of the wire, as that represents the exact form of the root (Fig. 165).

From a "bite" taken in wax a plaster articulation is then made to the model. A hole is drilled in the center of the form of the root on the model to be crowned. In this hole, and over the end of the root, a ball of soft plaster, slightly colored with carmine, is placed, and the teeth of the articulation, covered with tin foil, closed on it. This, on separation, gives the outline of the form of the grinding-surface for the crown. The sides of the plaster are then trimmed to the form of the crown, and the whole carved in detail (Fig. 166). As the crown will always stamp larger in circumference than the die, in proportion to the thickness of the gold used, an allowance must be made by trimming off a proportionate amount of the grinding-surface.

When the plaster model for the crown is made, it is separated from the rest of the model at the dotted line seen in Fig. 166, and trimmed in the form shown by the cast A, Fig. 167. From this model the die is made in a tube with moldine and fusible metal as described at page 82. The cast should always be lengthened at the neck, so that the crown when constructed shall have a surplus in depth of gold to allow for any trimming or shaping of the collar that may be required. The counter-die (B, Fig. 167) is made by punching a hole in a block of lead and hammering the die into it. The crown, which is usually formed of pure gold, or gold slightly alloyed, or gold lined with very thin platinum from No. 30 to No. 32 gauge, is then made by

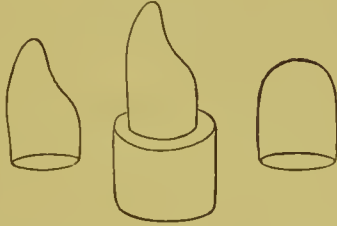


first stamping a piece of plate (see page 96) in the form of a cap of gold (A, Fig. 168). The cap is then placed on the cast, and with the aid of the counter-die (B, Fig. 167) swaged to the form of the crown B, Fig. 168. A piece of kid-leather or rubber-dam should be used to cover and protect the gold from the lead, and to facilitate its removal from the counter-die. An allowance for the thickness of the leather must be first made, by driving it, without the gold on the cast, into the counter-die to enlarge it. If this is not done, the gold is liable to be torn in the swaging.

Dr. C. B. Parker's method of stamping the piece of gold plate is to form two dies of the required crown,—the first with a cone-shaped neck up to the grinding-surface (Fig. 169), and the second straight on the sides (Fig. 170). The gold is stamped up on the first die, giving the grinding-surface, but leaving the sides flaring, and then on the second to straighten the sides.

Cuspid crowns from which a portion of the gold on the labial aspect is to be removed, or which are to be used entire as a support for bridge-work, can usually be advantageously formed

FIG. 171.



with a seamless cap (Fig. 171). The necks of these crowns can be contracted in fitting in a contracting plate, or slit, lapped, and soldered, should the case so require. (For details of process of adjustment and insertion, see "Adjustment of Seamless Contour Crowns," page 99.)

## CHAPTER VIII.

### GOLD SEAMLESS CONTOUR CROWNS.<sup>1</sup>

THE artistic requirement in all-gold crown-work is, that it shall reproduce the anatomical contour of the natural teeth. This is usually accomplished by melting solder on the collar and then trimming it to the form of the crown. A preferable method is to shape the metal forming the sides of the crown by swaging. This is easily done in a crown formed in sections, but a special process is required in the construction of seamless crowns.

A contour crown can be made by placing a seamless cap on a sectional die or mandrel of the shape of the tooth, first swaging

FIG. 172.



FIG. 173.

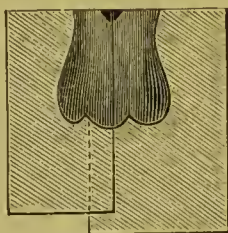
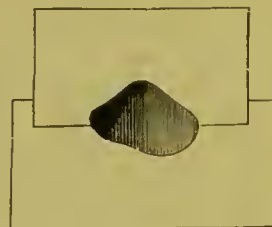


FIG. 174.



the grinding-surface on the mandrel and then stamping downward on the straight sides of the crown with a cap fitted to the shank part of the mandrel. But such a process, like many others, is too complicated to be of any use to the dental practitioner. The sectional mold method here presented is simple, practical, and general in its application.

To describe and illustrate the process, we will take one of the most difficult crowns to construct,—a superior molar (Fig.

<sup>1</sup> Gold crowns of this form are now made and sold as the "Evans Gold Crowns." The Evans Gold Non-fusible Crown is lined with platinum on the interior of the occluding surface and part of the sides, to prevent melting the gold in soldering.

172). A natural tooth, or one made of plaster, is used as a model. From this a sectional mold is made, as illustrated in Figs. 173 and 174, in Babbitt's metal, zinc, or fusible alloy. Into the mold a cap of gold (Fig. 175) 23 to 24 carats fine, No. 28 to 30 gauge, is adjusted, fitting tightly the orifice of the closed mold. The mold is placed in a vise, the cap expanded to the general form of the mold by hammering it into a mass of cotton, and then swaged more in detail to the form, and with a wood point or a burnisher revolved by the dental engine burnished in every part of the mold (Fig. 176). To facilitate the process, the mold should be frequently opened, and the gold annealed. Fig. 177 represents the completed crown. These results can be secured by other styles of molds. Fig. 176 illustrates one, but the principle is the same.

FIG. 175.

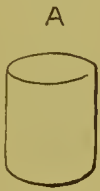

FIG. 176.

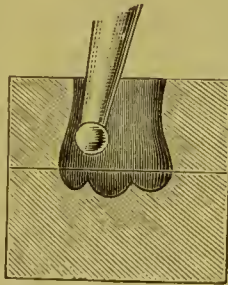



FIG. 177.



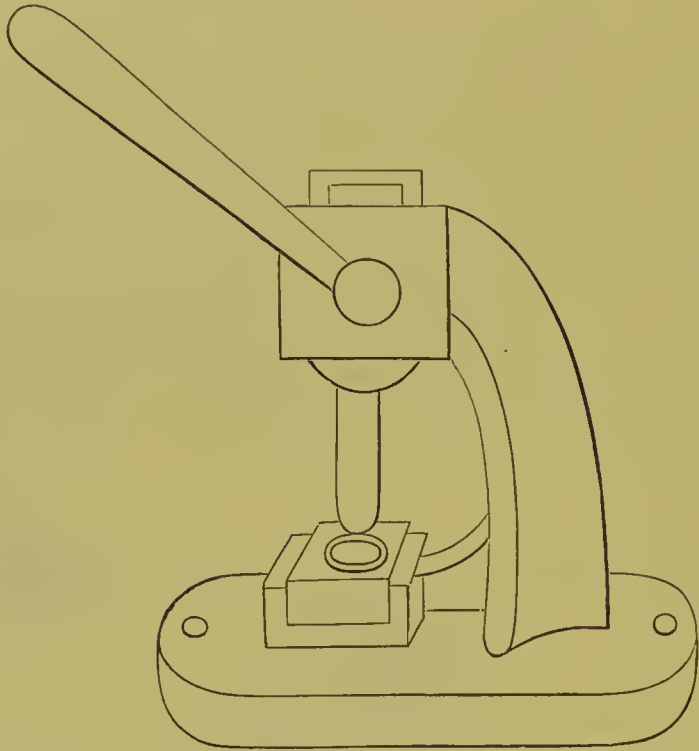
Another method is to form a fusible-metal die of the tooth to be crowned, and, after having stamped the grinding-surface of the crown, to reverse and swage the sides close to the die; the crown is then relieved of the core (die) by heating to the melting point of the fusible metal and pouring it out.

For practical use, a variety of molds is required, made from natural teeth of different sizes and average forms to serve in corresponding cases. The crowns can be contracted at the neck more than their size and contour call for, so that the gold will act as a tight-fitting band which will expand to the form of the root as the crown is pressed up in the process of adjustment.

Caps of metal can be made in different sizes and kept on hand for use in this and other styles of crown-work by means of a machine (Fig. 178), which in principle is such as is used by

jewelers for forming cap-shaped pieces of gold, and in factories for making copper cartridges. The gold plate, cut into circular

FIG. 178.



The form of stamping machine introduced by the late Dr. J. J. R. Patrick.

pieces, is pressed through a steel die-plate, with punches gauged to the holes; at each punch a small portion of the gold is turned

FIG. 179.

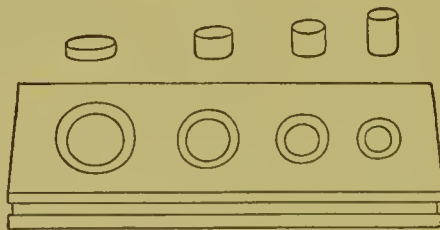
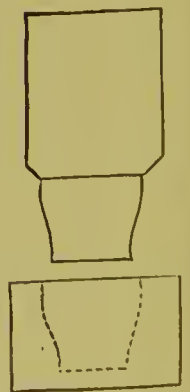


FIG. 180.



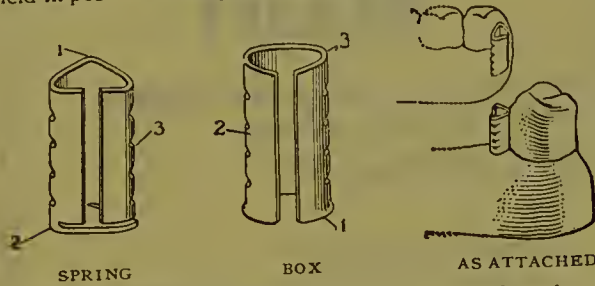
over, thus preventing its lapping or creasing (Fig. 179). Repeated annealing of the metal is very necessary in this process.

*Methods of Contouring Crowns constructed in Sections.*—In constructing a crown in sections, the collar can be

# The Griswold System

## For Bridge Work

**T**HIS is a method of constructing Removable Bridges and Partial Plates, by soldering spring attachments to Artificial Crowns or Root Caps, and the making of dentures with corresponding locking attachments, so that while the denture may be easily removed, it is firmly held in position when placed in the mouth.




The attachments consist of a "V"-shaped male part, corrugated, called the Spring, which is soldered to the crown, and a female part to fit over it, with corresponding corrugations, called the Box, located in the denture. The corrugations on the Spring and Box interlock, and form a *distinct locking device*, which will hold the denture firmly in place.

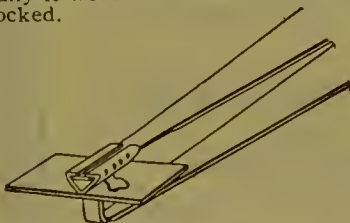
As it is *necessary* that the Springs when soldered to the crowns should be *parallel*, to enable the removal and replacing in position of the Bridge or Plate, the work of soldering the Springs to the Crowns should be performed on the Soldering Jig, which will hold the Springs parallel.

### How To Construct

In constructing a Griswold Case, the teeth are first prepared, the same as for any bridge, and the crowns fitted. An accurate impression is then taken, with the crowns in place, and the model is poured, using any material on which the soldering may be done. This model is then placed on the Soldering Jig, the location and common angle at which the Springs should be soldered to the crowns determined (naturally it would be in line with the ridge) and the Jig firmly locked.



PARALLELING JIG FOR SOLDERING ATTACHMENTS TO CROWNS



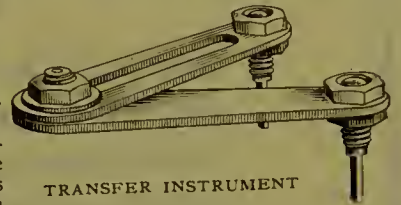
PLIERS

With the aid of the Pliers, solder a little piece of thin gold plate across the apex of the Spring for reinforcement, using as little solder as possible; then place the Spring on the Jig Soldering Chuck, bending the plate to conform as closely as possible to the crown, and



SOLDERING CHUCK

solder the plate to the crown. When the Springs are all soldered to the crowns and finished up, set the crowns in the mouth and cement them in position, the only difference being that you have soldered the Spring Attachments to the crowns. *Be sure* the Springs on crowns are *parallel* when cemented in the mouth. The Transfer Instrument, which should be used to insure this, has two little chucks which fit into the Springs on the crowns and will hold

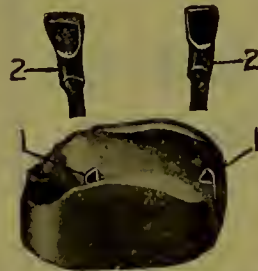

TRANSFER INSTRUMENT

the Springs parallel to each other while the crowns are cemented into place.

If the spring has expanded somewhat from the heat of soldering, close it gently with a pair of pliers, and adjust the box so it will slip on and off easily. Solder a little piece of plate across the top of each box, and a small stub at the back for anchorage in the denture.

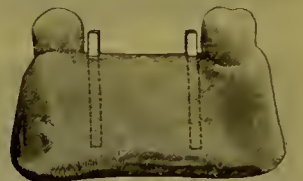Now with the Boxes on the Springs take a new impression in plaster and you will find your Boxes come away in your impression. When your impression is thoroughly dry, oil or varnish and



1. IMPRESSION  
2. BOX-RETAINING CHUCK

place a Box-Retaining Chuck in each Box to locate the exact position of the Box in the denture and pour model on which to make denture. Place the Boxes, taken from the impression, over the Box Chucks projecting from the model, where they will be held rigidly in position while the denture is made up. Wax up your case, pack your rubber and vulcanize on this model, painting inside of Box with whiting to prevent entrance of any rubber.

When the plate is finished, if ordinary care has been taken, it will be a perfect fit, the Boxes fitting the Springs accurately. Now spread the Springs a trifle (an ordinary penknife blade is best) to tighten the case, and instruct the patient how to remove same.



MODEL, WITH BOX CHUCKS PROJECTING IN CORRECT POSITION FOR BOXES



MODEL, WITH BOXES IN POSITION FOR MAKING UP DENTURE

The result will be a piece of work that will please the patient as well as the dentist.

The price of the GRISWOLD OUTFIT complete, including three sets of Attachments, is \$15.00.

Write for descriptive literature or any special information.



AS FINISHED

# The Griswold Dental Bridge Co.

1133 Broadway, New York  
1001 Masonic Temple, Chicago

DR. A. C. HEWETT'S  
**STERION  
 WHITE ALLOY**

PROPHYLACTIC  
 PRESERVATIVE  
 UNSHRINKING  
 GERM PROOF

**STERION WHITE ALLOY CO.**

1111 Masonic Temple  
**CHICAGO**

A TRI-CONTINENTAL SUCCESS

**Immediate Mastication**

will not disturb a filling of

**STANDARD  
 ALLOY**

and you may build the biggest  
 crown or pivot a tooth

**At a Sitting**

FINE AS FLOUR

Three Dollars a half-ounce  
 Discount for Quantity

**ECKFELDT & DUBOIS**

LABORATORIES IN MONTGOMERY COUNTY, PA.  
 NO DENTAL DEPOT

Address  
 P. O. Box 995, Philadelphia, Pa.



35-37 RANDOLPH ST.

OVER S. S. WHITE'S  
 DENTAL MFG. CO.

CHICAGO, ILL.

W. J. TRUMPOUR, Mgr.

DR. J. C. McLEAN, Sup't

**It's No Longer a Question**

as to where dentists receive the best workmanship and materials  
 or the most prompt service, as the

**Atlas Dental Laboratory Co.**

is admitted by all first-class dentists who are in a position to  
 judge to have the largest and most competent aggregation of ex-  
 pert mechanical workmen ever before known to operate under  
 one management, and their business methods are in strict  
 harmony with their work and materials. Others may duplicate  
 their prices, but that's all.

**Is the Best Too Good for You?**

"Catalogues mailed upon application"  
 Highest prices paid for gold and platinum scrap

**ATLAS DENTAL LABORATORY CO.**

INCORPORATED

OVER THE S. S. WHITE DENTAL MFG. CO.

**35-37 Randolph Street, CHICAGO, ILL.**

Telephone Central 1780

Please mention DENTAL COSMOS



first formed on a mandrel, then placed in a mold, and burnished to the shape of the sides. The process of its adjustment to the neck of the root is then continued in the usual manner.

Another method is to stamp or burnish up the collar on a die representing the upper sections of a tooth, designated as the middle and cervical third (Fig. 180). After contouring the collar, the cap is adjusted and soldered on. With a metallic stamping plate (see page 85) these caps are quickly made.

#### ADJUSTMENT OF SEAMLESS CONTOUR CROWNS.

A superior molar—one of the most difficult teeth to operate on—will serve as a typical case to illustrate this process. The crown or root is first shaped and if necessary built down with amalgam, straight, or tapering slightly on its sides toward the occluding surface, as described at page 38.

*How to Select a Suitable Crown.*—The width of the crown required from the anterior to the posterior sides of the occluding surface is first obtained by measurement with a piece of cardboard or thin copper plate, as shown at A, Figs. 181 and 186. The measurement can be taken direct from the mouth, or more conveniently from a small plaster cast made from a correct impression of the *prepared crown or root* and the two approximal teeth. This measurement can also be taken by means of tweezers with a set-screw (Fig. 182). With this measurement as a guide, the proper-sized occluding

FIG. 181.

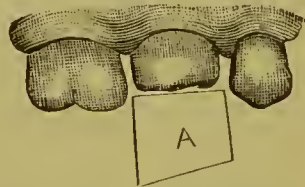



FIG. 182.



Tweezers with set-screw to use as calipers.

surface is readily found by comparison with the dimensions of the various crowns as shown on the printed chart of the crowns (C, Figs. 183 and 184).

The size of the neck can be gauged by the eye, or by taking the dimensions with a piece of fine wire (Fig. 187), pressing the

wire on the surface of a piece of sheet wax, and then comparing with the impression the necks of the gold crowns.

FIG. 183.

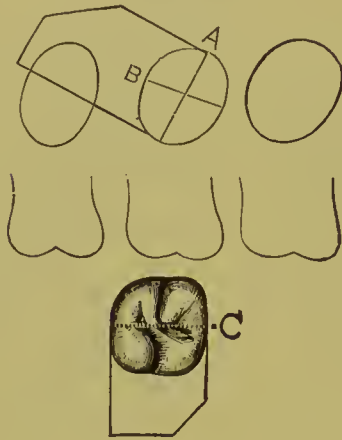


FIG. 184.

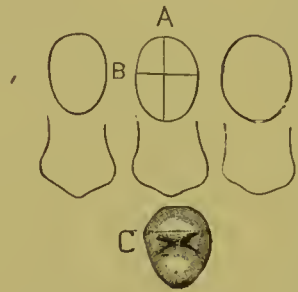
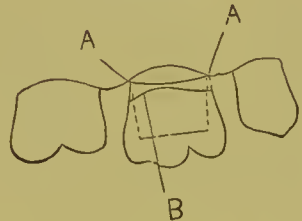


FIG. 185.



In making a selection, it should be borne in mind that the cervix of the gold crown should preferably be smaller than larger, as it can always be easily expanded, while its contraction is difficult. It is not essential that the curve of the collar shall correspond with that of the tooth, as the gold will readily take the proper shape as the crown is adjusted.

*Method of Adjusting the Crown.*—1. Anneal the crown selected, and slip it over the end of the natural crown or root and gently press or work it upward—the gold of the collar will expand to

FIG. 186.

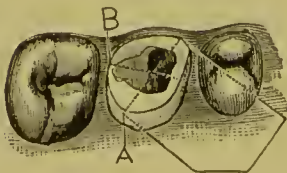


FIG. 187.

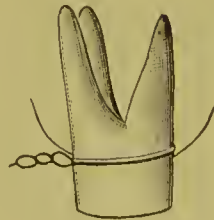
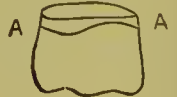

FIG. 188.



the form of the root in the operation—until the edge meets the margin of the gum (A, Fig. 185).

2. Mark a line (B) on the gold parallel with the margin of the gum.

### Mold for Seamless Crowns.

AFTER the model for the crown has been carved, mix plaster and set model in so that only the cusps are covered. Remove the model, cut a guide groove in the plaster, replace model and oil slightly. Now run plaster around one side, and when set trim it up and run the other side. This gives you a mold in three pieces, which has been found preferable for casting Melotte's metal. The gold may now be swaged by any of the methods, and after the swaging is completed boil in water to facilitate the removal of the crown from the metal die.—DR. HOMER ALMON, *Review*.

---

### [ Seamless Crowns.

I MUCH prefer to make all crowns seamless, especially those with open face. Swaged over an accurate model of the tooth, they have a glove-like fit which I have been unable to attain by any other method. It is well to remember, however, that drawing a disc of gold plate to the form of a thimble does not increase its toughness, that a seamless crown so made must be thoroughly reinforced. The narrow bar at the gum margin should be doubled, and any bridge attachment should be so extended as not to depend for security upon a small area of the crown. I find a satisfaction in using seamless crowns for bridge supports in that when fitted there is no risk of the fit being impaired by solder running inside. The method of construction, however, is a mere personal matter, and has but little to do with the result.—DR. WM. H. TRUEMAN, *Dental Brief*.

policy of promotion by selection on professional grounds rather than a rigid adherence to the more purely military claims of seniority. The new Director-General has distinguished himself as an organiser both in the late war in South Africa—where his services obtained for him the medal with clasp, mention in despatches, and the Companionship of the Bath—and at headquarters, working under his predecessor, Sir William Taylor.—*The Lancet*.



### A NEW SPECIMEN OF THE GENUS "DIPLOMA IGNOTA."

WE have discovered what is to us an entirely new brand of diploma, and a new brand of Latin. The diploma is "Chirurgia Dentium Doctorem," and is translated "Doctor of Dental Surgery." A correspondent of the *Western Mail* objects to having seen this described as an American diploma in chemistry. Certainly the paragraph in which it was so described was headed "Unregistered Dentist," but the publication of the correspondent's letter will not convert this rare and interesting specimen into a registrable qualification, though it may serve as a gratuitous advertisement. We refrain from giving the correspondent's name on the latter account. It reminds us of the quack doctor who was prosecuted for using the letters "M.D." on his door-plate, and argued in defence that it was not intended to suggest that he was qualified to practice medicine, but simply meant "money down." Perhaps the letters "C.D.D." may be interpreted as meaning

3. Remove and trim to this line (A, Fig. 188). If necessary, repeat the marking and trimming until the edge meets the gum evenly.

4. Bevel the edge of the gold, readjust the crown and press it up until the edge of the collar passes under the margin of the gum, and, if the occlusion is correct, burnish the gold to the cervix.

*To Expand the Collar and Crown.*—If the collar of the crown needs enlargement, it is easily and most properly accomplished with crown expanders (shown in miniature form in Fig. 189), the points of which should be introduced at first just within the edge of the neck, and the gold spread sufficiently to allow it to fit over the end of the natural crown or root, the process of expansion being gradually continued as the crown is brought into position. By proceeding in this manner too great expansion is avoided.

If the entire crown needs enlargement, it is best done by softening a mass of gutta-percha of about the same size as the crown upon the closed ends of a pair of expanding or clamp forceps, which are heated for the purpose. The forceps points with the gutta-percha are then introduced inside the collar of the

crown, which should be moistened to prevent adhesion. The gutta-percha is next withdrawn, hardened in cold water, and cut through the center between the points of the forceps. This makes practically an expanding sectional mandrel with which the crown can be enlarged according to the position in which the forceps were introduced (Fig. 190).

To expand the crown without enlarging the neck, trim off the gutta-percha on the forceps at the neck.

The naked points of an ordinary clamp forceps can sometimes be used to advantage to expand a

portion of the coronal section of the crown.

*To Alter a Side.*—The contour of one or both sides can be de-

FIG. 189.

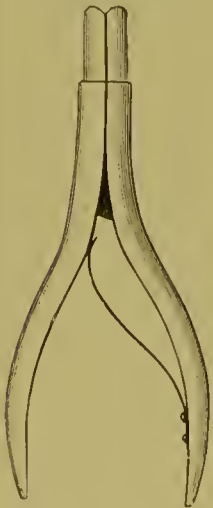
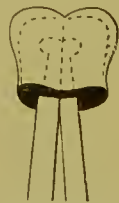
FIG. 190.



*pressed and the crown thus narrowed* by introducing the points of a crown expander or some tool that will fit loosely inside the crown, then steadying the crown with the fingers, as shown in Fig. 191, and tapping the sides to be reduced with the flat end of a riveting hammer. Pliers will also accomplish it, one beak being placed inside of the crown, and the other being placed against the bulge on the outside. This is necessary when the *contour* or *the side* of a crown *presses on an adjoining tooth*, and the crown is thus prevented from coming in proper position.

*To Alter the Shape of a Portion of the Collar or Side of a Crown.*—Slip the crown over the point of an anvil, or the end of a pair of expanders, or a small round-handled instrument held in a vise, and then tap the part to be altered with the flat end of a riveting hammer to the form desired.

FIG. 191.

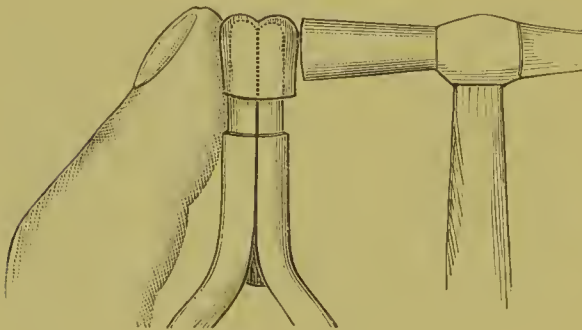
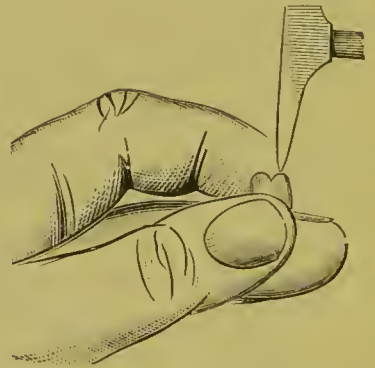

FIG. 192.



*To Alter the Occluding Surface.*—Before the crown is pressed up to its apparently proper position, the occlusion should be examined, and calculations carefully made to obviate any defects of articulation, which can be readily corrected at this stage by proper manipulation of the crown. Any necessary change in the form of the occluding surface can be made with the crown in position on the tooth, by means of an instrument tapped by the mallet; or by removing the crown, placing it over the closed points of an expander, and tapping and burnishing the part; or by holding the crown between the thumb and forefinger with the edge of the collar resting on the side of the next finger, which when necessary can be protected with a napkin, and then tapping the gold with the point of a riveting hammer (Fig. 192).

The occluding of the antagonizing teeth on the crown by the patient will assist and complete the process of articulation.

*To Contract the Neck.*—Slightly bend in the edge of the gold at the neck with narrow-beaked pliers, and holding the crown evenly and firmly between the fingers, as shown in Fig. 193, burnish the sides and neck section inward around the entire circumference of the crown.

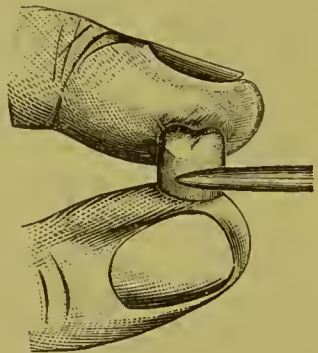
*To Considerably Contract a Crown.*—Slit the gold longitudinally at the palatal or lingual side its full length to the grinding-surface, bevel off the edge to lap under, contract the crown, readjust to the tooth, remove, place the smallest quantity of dampened flux solder filings in the seam *on the inside of the crown only*, and solder by holding in an alcohol flame. Then proceed with the further adjustment of the crown.

The outside line of the seam can be stoned off and polished after the crown has been fitted, and additionally soldered to strengthen the sides or grinding-surface.

*Strengthening Seamless Gold Contour Crowns.*—Additional strength and stiffness can be given to seamless gold crowns, when desired, in several ways. The liability of melting the gold which forms the side of the crown in the operation has, with some, been the principal objection to their use. This, however, can be avoided.

When the crown has been properly adjusted, dampen the inner surface with a piece of wet cotton on the point of an instrument; place in the interior a quantity of fluxed solder filings (solder filings mixed with Parr's flux or pulverized vitrified borax); place the finger over the open end of the crown, invert, and shake well. A portion of the solder filings will adhere evenly all over the wet surface. The surplus is allowed to drop out by removing the finger. Then gradually and uniformly heat the crown by holding it with tweezers in an *alcohol flame* (not gas) until the solder fuses, when it will flow evenly over the surface of the gold without materially altering the general form.

FIG. 193.



The crown should be held in such a position that a full view of the interior is presented and the melting of the solder rendered visible, which will occur at a red heat.

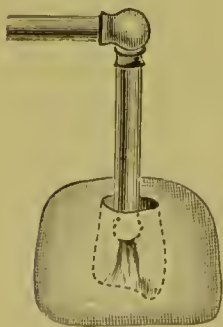
An extra quantity of the solder filings can be placed in the interior of the cusps with a spoon-shaped excavator to additionally fill or strengthen them if found necessary.

When a *Bunsen gas flame* is used instead of an alcohol flame, the grinding-surface and sides of the crown should be first coated with whiting. This is easily done by dipping the crown into a cream-like mixture of whiting just before inserting it in the flame. The moisture in the whiting should be first slowly evaporated by heating up gradually. Great care must be exercised in the use of a gas flame to avoid melting the crown. The crown should be watched, and instantly removed as soon as the solder fuses and flows.

If too much solder has been applied at any point, it can be trimmed and smoothed with corundum melted on to an old engine bur-point. Always boil the crown in acid to remove the flux. The removal of flux from the inner surface of the crown is absolutely necessary if you intend to use it in bridge-work, as solder will have to be melted on the outside.

*To repair a hole* melted in any kind of a gold crown, place a piece of soft wax in the aperture, on the outside of the crown, adapt on the inside close against the gold a piece of platinum foil, somewhat larger than the aperture, so that it will adhere to the wax. Fill the interior of the crown with investing material, and flow a little solder over the surface of the platinum, and gold on the outside of the crown.

FIG. 194.



Gold seamless crowns can also be strengthened or filled with solder, or even 18- or 20-carat gold plate, by investing the outside surface in plaster and marble-dust (Fig. 194), and then with a small flame of the carbo-oxygen blow-pipe, not over one-half an inch in length, introduced inside of the crown, melt and flow the solder or gold plate over any portion or even all of the surface of the gold. The crown, if formed of gold with



a thin lining of platinum, can be soldered by either method with little danger of being melted.

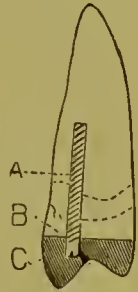
*Supporting the Crown.*—In crowning teeth with living pulps there is sufficient of the natural crown present to afford a secure foundation and attachment for the artificial crown, as is also the case with many teeth that are pulpless; but in badly broken-down crowns, or where only the root is present, a metallic pin or post should be inserted in the root, and the part built down with amalgam to a form which will afford secure support and attachment to the artificial crown, and facilitate its adjustment. (See "Special Preparation of Badly Decayed Teeth or Roots," page 39.)

In many cases the required support for the crown can be secured by means of a screw (Fig. 195). A How screw or post of silver wire is inserted in the root-canal A (see page 47). Amalgam is then packed in the lower section of the artificial crown, C, to the line B, and into the amalgam the screw is pressed. Amalgam which has been put in a piece of chamois and the mercury pressed out with a pair of pliers until it is in the condition termed "dry" will adhere to the gold without affecting it. The amalgam is first placed in the crown slightly in excess of the amount required, and the crown adjusted, removed, and the surplus scraped out. This process is continued until the screw or the crown section of the natural tooth forms an indentation in the amalgam, which it will fit when the crown is cemented on. (For process of cementation, see article on "Insertion and Cementation.")

These crowns can be inserted in an easy and inexpensive manner by filling in the lower section of the crown with amalgam instead of gold, and allowing the head of the screw or the natural crown to indent the amalgam as above described, and then cementing on the crown with oxyphosphate in the usual manner.

In a case so inserted, with no antagonizing teeth, the result is the same as though the inside of the occluding surface of the crown was filled with gold; but if antagonizing teeth are present, the gold of the crown is apt to wear through in places and expose the amalgam.

FIG. 195.



*To Securely Attach a Crown.*—If the tooth is short, and the occlusion of a character requiring the reduction of the collar to such a degree as to suggest insecurity when the crown is cemented, a barbed or headed pin, which will anchor in the natural crown or root, should be soldered in the center of the gold crown, as shown in Fig. 196. This is done by passing the pin through a hole drilled in the occluding surface of the crown, which is then adjusted in the mouth, removed, invested, and the pin soldered from the outside. If the pin is tapered and fitted tightly to the hole (Fig. 197), the soldering can be accomplished without investing, by holding the crown and pin with solder in position in an alcohol flame.

*To Alter a Gold Crown to the Exact Form of any Corresponding Natural One.*—In a case having nearly all the natural teeth present, in which the occluding surface and sides differ in shape

FIG. 196.

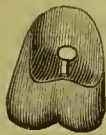

FIG. 197.



FIG. 198.



from the form of the gold crown, to such an extent as to interfere with its adjustment, a die of the natural crown should be made of fusible metal (Melotte's Fusible Alloy,—see article on "Molds and Dies"), and with it the interior of the gold crown should be altered in shape sufficiently to receive the natural crown, by resting the occluding surface of the gold crown on a folded napkin and gently tapping the die into it.

Fig. 198 represents the typical molar crown cemented in position.

The advantages of seamless contour crowns are, that they represent perfectly the tooth in its anatomical contour, present a uniform surface of pure gold, which preserves its color without tarnishing, and are quickly and easily adjusted. Their defects are inability to meet the requirements of abnormally-shaped roots and anomalous articulations.

## CHAPTER IX.

### GOLD CROWNS WITH PORCELAIN FRONTS FOR TEETH WITH LIVING PULPS—COLLAR CROWNS HYGIENICALLY CONSIDERED.

IN the anterior teeth, in case of atrophy or erosion, or where decay has destroyed the approximal sides of a tooth in such a manner that crowning is considered the most desirable operation to perform, the pulp is frequently found unexposed and in a normal condition. The importance of its preservation in such a case is unquestionable

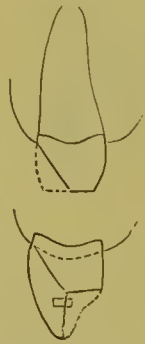*Crowning in Cases of Abrasion.*—In a case of extensive abrasion of the incisive edges of the anterior teeth, with pulp living though considerably calcified in the coronal section, crown-work to restore the length and form of the teeth is best performed by removing a portion of the labial aspect of the natural crown and then forming the artificial crown similar to a gold collar crown with a porcelain front without the pin. Fig. 199 gives an outline of the construction of such a crown. If a case should suggest

the necessity of a pin, a short one can be so inserted between the line of the pulp-chamber and the palatal wall.

*In Atrophy or Erosion,* when only a limited portion of the labial side of the natural crown can be removed, the porcelain front takes the form of an inlay in the case of a gold crown or of a film of porcelain attached by baking in a furnace in a platinum crown.

The descriptive details of the crowning of a central incisor will serve to illustrate one of the inlay methods. A model is first made representing the tooth in a perfect form. This can be done readily in several ways: by restoring the form of the

FIG. 199.



natural tooth in the mouth with oxyphosphate or gutta-percha, taking an impression of it in wax or moldine, and from this forming a model in plaster or fusible alloy, or by taking a natural tooth and shaping it to correspond, or, if the operator is an expert, carving a model from a piece of plaster.

Two casts, one of the coronal form of the tooth (Fig. 200), and the other of only the palatal and approximal portions (Fig. 201), are made, using the moldine in tubes with fusible metal. This will consume only a few minutes. A piece of gold and platinum crown plate, No. 34 U. S. standard gauge, about the length and circumference of the tooth, is then struck up on the palato-approximal cast, from which it receives the palatal and approximal aspects of the tooth (Fig. 202). It is then transferred to the coronal cast, which is previously trimmed the

FIG. 200.

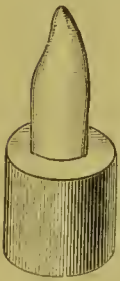


FIG. 201.

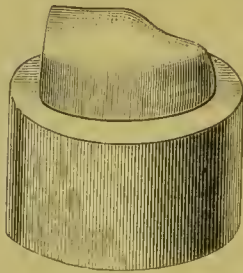


FIG. 202.




FIG. 203.



FIG. 204.



FIG. 205.



thickness of the gold plate upon the approximal surfaces, and worked down to the exact form of the tooth on the anterior portion. The metal, which is then of the exact form of the tooth on all sides, is cut even at the incisive edge, the seam down the front beveled, lapped, and marked, then slightly opened, and the gold slipped off the die. Guided by the mark, the gold is then pressed back to the form assumed on the die, and fitted to the natural crown, which should have been previously trimmed and shaped as described on page 38 (Fig. 21), and the joint on the labial side soldered (Fig. 203). Into the incisive edge, which is open, a narrow strip of gold, about one-sixteenth of an inch in width and thick enough to fill the space, is fitted and soldered. This strengthens the whole crown, and forms a protecting edge for the porcelain front.

We have now a gold contour crown, an exact imitation of the tooth under treatment. The crown is then filled with plaster, and the labial portion ground and filed away, leaving the upper part to form the band, and the lower the incisive edge, as represented in Fig. 204.

A porcelain tooth of the proper shade and form is then ground down—in which operation the pins are obliterated—to a thin porcelain front, thickest at the incisive edge, and fitted to the space made by cutting away the labial face of the gold crown. The porcelain is then removed and a piece of platinum foil adapted to its back, and turned just barely over the edges, the upper and lower of which should be slightly tapered off, as shown in Fig. 205.

The platinum can be made to fit closely to the porcelain by rubbing the edges on a piece of cloth or chamois, on a flat surface.

FIG. 206.



FIG. 207.

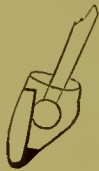

FIG. 208.



FIG. 209.



The porcelain front is then adjusted on the crown and cemented on one side with wax, and the crown invested in plaster and marble-dust, so that the seam along the edge of the platinum and gold is exposed on the cemented side and at one end as shown in Fig. 206. When the investment has set, the wax is removed, and small pieces of gold solder or fluxed gold solder filings, 20 carats fine, are packed in and over the seam, in quantity sufficient to make a perfect joint when finished. The investment is then heated uniformly and the seam soldered. Care must be taken not to flow the solder upon the porcelain, or to use more borax than is absolutely necessary. Neglect of either of these precautions will be likely to result in the fracture of the porcelain.

When the investment is cold, the crown is removed, again invested, and the remainder of the seam soldered, or the invest-

ment can be immediately removed from the other side, and the soldering completed; though this latter plan is attended with some risk to the porcelain.

After the crown has gone through the finishing process, any excess of porcelain on the inside of the crown is ground away in a few minutes with a small piece of corundum melted on an old oval-shaped bur. The cavity in the crown is, meanwhile, kept filled with water (Fig. 207).

In adjusting the crown, the natural tooth can be smeared with a paste made of rouge and sweet oil, which will easily indicate any point obstructing its perfect adaptation. When fitted, the crown is attached with oxyphosphate cement. Fig. 208 shows the completed crown.

In making this style of inlaid crown, Dr. J. B. Littig depresses the labial aspect of the gold crown as much as possible, and grinds and properly fits over it a porcelain front. The porcelain is then removed and a narrow strip of gold soldered around the line of the porcelain which will just receive its edges. In this setting of gold the porcelain is inlaid by cementing it with oxyphosphate and burnishing the edges of the gold over on the edge of the porcelain.

Bicuspid and molars can be made in either of the methods described by using a contour crown of gold lined with platinum (see chapter on Gold Seamless Contour Crowns), and, after its adjustment, filling in the crown with plaster, then cutting away the labial portion and replacing it with porcelain (Fig. 209).

When the porcelain is to be attached by baking, a platinum crown<sup>1</sup> is first formed. The portion to receive the porcelain is depressed and perforated as shown in Fig. 210, in case of a bicuspid. The film of porcelain is ground to fit the depression and then secured by a small portion of body placed under and around the film, and baked in a furnace in the usual manner. A film of porcelain body alone baked on the platinum crown instead of the porcelain film as described, has a dead and unnatural appearance. Both of these styles are liable to chip off if not

FIG. 210.



<sup>1</sup> Pure gold alloyed with platinum sufficient to resist the heat of the furnace is also used.

securely attached through perforations made in the metal above the line where the force of occlusion is applied.

#### COLLAR CROWNS HYGIENICALLY CONSIDERED.

The principal argument against ferruled or collared crowns is that they are productive of irritation to the peridental membrane, ultimately causing its absorption and the exposure of the collar. This would be theoretically and practically true of a rough or porous substance encircling the root, or of an imperfectly and unskillfully adjusted or cemented ferrule or collar which would by its presence hold a position analogous to a calcareous deposit, but no such comparison can be fairly made with a perfectly fitted collar, forming at its edge a smooth and imperceptible union with the sides of the root, and presenting a uniform and benign surface to the investing membrane. In case of perfectly adapted collars, when any irritation of the membrane exists, it will be found to result from such causes as usually produce it when the natural crowns are present, namely, dental concretions. A tarnished and unclean condition of the surface of the gold of the collar will produce irritation of the membranes, which is a matter independent of the collar itself, and easily remedied by cleansing and polishing the surface. Where an acid condition of the secretions of the mouth exists, a collar of platinum or iridium, or one of gold and platinum crown-metal, presenting the platinum surface, is suggested in preference to gold, as these metals will not be affected, but will constantly present an untarnished surface.

When evidences of a tendency to pyorrhea alveolaris exist, a collar adjusted to support bridge-work should be extended well under the gum-margin, or the edge of the collar kept considerably above it. Where pyorrhea alveolaris is present, a collar of fine gold, properly fitted and extended well up over the exposed section of the surface of the root, has often a tendency to retard the disease, as calcareous deposits do not adhere to the smooth surface of the gold so readily as to the dentine.

## CHAPTER X.

### SPECIAL FORMS OF GOLD CROWNS WITH PORCELAIN FRONTS.

#### PORCELAIN AND GOLD CROWN WITHOUT A COLLAR.

THE root of a cuspid will be taken as a typical case to illustrate the construction of this style of crown.

The end of the root is prepared the same as for a porcelain crown (Fig. 211). The root-canal is then uniformly enlarged a reasonable distance up, with a drill which will closely fit the opening. Into the canal, gauging its full diameter, is fitted a

FIG. 211.



FIG. 212.

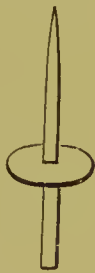

FIG. 213.



FIG. 214.

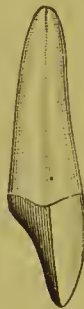

FIG. 215.



piece of iridio-platinum wire, tapered off to a point, so that by introducing it far up the canal greater strength can be obtained, and the root rendered less liable to longitudinal fracture from pressure in a forward direction. A piece of platinum plate, a trifle larger than the end of the root, of about No. 30 U. S. standard gauge, with a hole punched in its center, is then slipped on the post, which it must fit tightly (Fig. 212).

When the post is adjusted firmly in the canal, the platinum plate is pressed down on the root, and burnished into the orifice of the canal around the post. When the post is withdrawn from the root, the platinum will adhere to it, if fitted closely, with-

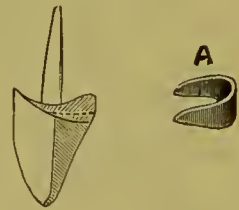


out the use of wax. A particle of pure gold with borax is put in the joint, and melted in the flame of an alcohol lamp. Barely enough gold should be used to unite the parts. When soldered, the post and cap are again adjusted in the mouth and the cap malleted and burnished to the form of the end of the root, so that its edge will leave a mark on the platinum. The cap, on being removed, should be trimmed to this mark, and again burnished on the root (Fig. 213). Sometimes around the palatal portion of the root the platinum may be slightly burnished over the edge. The post is then cut off just above the platinum, and a plate tooth fitted, backed, and cemented with wax in position on the cap, as described on page 83. The whole is then removed, invested, and soldered with gold, which should be melted in at the base of the post, as at this point, when in use, the strain is very great. The post is then barbed, and the crown is cemented to the root with gutta-percha or oxyphosphate cement (Fig. 214).

Dr. F. T. Van Woert, of Brooklyn, N. Y., in constructing crowns without collars, shapes the end of the root, and adapts the cap as shown in Fig. 215. The slant given to the palatal side aids the root to resist force in a forward direction.

The advantages of a collar can in a great measure be given this form of crown by the addition of a metal flange, encircling the palatal section of the root, as shown in Fig. 216. A piece of gold or platinum, similar in shape to that shown at A, is formed and fitted to the crown, fixed in position on the crown with wax, and adjusted in the mouth, removed, invested, and soldered. After finishing, the metal flange is burnished against the root before the crown is cemented.

FIG. 216.



Ready-made posts corresponding in size to the Ottolengui reamers, Fig. 72, with disks of platinum, can be used to facilitate the construction of crowns of this style.

The posts are illustrated in Fig. 219. A disk of platinum with a perforated depression in which a little gold has been melted is shown in Figs. 220 and 221.

The method is as follows:

Shape the surface of the end of the root as shown laterally in Fig. 217.

Trim the approximal and palatal sides of the end of the root as illustrated in Fig. 218, but leave the labial side A, intact.

FIG. 217.

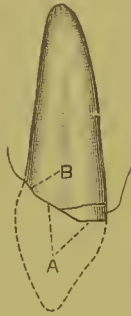


FIG. 218.



Enlarge and ream the root-canal with Ottolengui root-canal reamers, shown in Fig. 72, to the proper depth, first using the smallest size, and if necessary the larger sizes afterward.

FIG. 219.



FIG. 220.




FIG. 221.



FIG. 222.



Select a post (Fig. 219) corresponding in number to that of the reamer used. Seize the large end of the post with the points of the pliers and fit the post to the canal. Move the post up and down—but do not twist—a few times in the canal, and the slightest discrepancy that may exist respecting size will be instantly removed.

Grasp the post when fitted in the canal with the pliers, having the points close to the surface of the end of the root. Remove the post without moving the position of the pliers. Screw the post into the hole in the depression of the platinum disk, shown in Fig. 220 and in section in Fig. 221, up to the points of the pliers, thus giving the post its position in the disk.

Bend the sides of the disk downward, as shown in Fig. 222, and adjust the post in the canal to determine their relative posi-

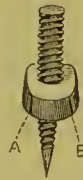tions. By twisting the post, changes of its position in the disk may be effected.

The orifice of the canal of the root should be slightly enlarged with a round bur to allow the depression of the disk to fit within it. Press the post firmly upward in the root-canal to assure that its original position is not interfered with by the disk.

Remove the post and disk, the disk retaining its position on the post. Unite post and disk by holding them in a Bunsen gas flame until the pure gold in the depression is fused. No flux is necessary, as sufficient remains from the fusion of the gold in the depression.

Place the post and disk on the root, and press and mallet the platinum to it with a large flat plugger, which, owing to the rigidity of the post in the canal, will accurately outline the form of the end of the root on the platinum. Remove and slit the platinum at two points between the palatal and approximal sides to the outline of the end of the root as shown in Fig. 223, at A and B, and bend the platinum over with the pliers to embrace the approximal sides of the root.

FIG. 223.



Again place the post and cap on the root, and elosely fit the side flaps, with the aid of foot-shaped condensers and burnishers. Next bring the palatal flap down to position. Frequent removals and annealings are necessary during the process, which should include the final trimming of the edge of the platinum, smoothing with a corundum-point, and then an annealing and all-round burnishing of the cap to the root. Cut off the end of the post above the cap with a corundum-disk and level with a wheel. The cap can now be invested and the seams soldered, or this can be done in the soldering on of the poreelain front.

#### MOUNTING THE PORCELAIN FRONT.

At the cervico-labial section the porcelain can rest on the platinum, or the platinum can be trimmed, so that the front edge of the poreelain may be fitted against the root, and cover it. (See Fig. 224.) The projecting end of the post should also be removed by first notching with a disk, leaving it a little flush at the palatal side. The porcelain front, which should be a

cross-pin plate tooth, is ground and closely fitted to the surface of the root or metal, as may be, at the cervico-labial section under the edge of the gum, but a properly shaped space opening toward the palatal side is left between it and the surface of the cap. To so shape the porcelain simplifies the fitting of the cervical section. The space between the cap and the porcelain is also easier filled in the soldering. To the porcelain front at the part B, Fig. 225, a piece of very thin platinum foil is shaped, the porcelain heated, the part veneered with a mere film of resin and wax, and by pressure with napkin or cotton the platinum foil is attached thereto. The rest of the porcelain is then backed with thin platinum plate (about No. 34 gauge). The platinum is left slightly extending over the incisive edge, and the porcelain front is waxed in position on the cap.

Fig. 224 shows the crown waxed up ready for investment. Wax in full quantity must be extended over the collar to its edge, in the seams, and between the porcelain and the cap at

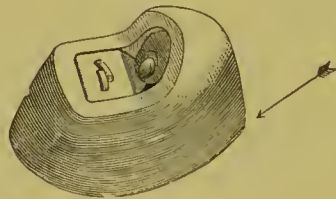
FIG. 224.

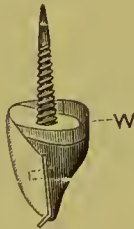

FIG. 225.



FIG. 226.



every point solder is to flow (the writer uses Parr's fluxed wax). Fig. 226 shows the invested crown with the wax removed. In trimming the investment the material must not be removed from over the collar lower than the line of the surface of the cap, nor in such a manner that the platinum turn-over edges are exposed to the direct force of the flame. Even though the collar is not exposed, the solder will flow over the outer surface of the platinum just where it is wanted and where wax has been applied, and all the parts will become united. The investment must be slightly raised at one end and heated up under its base with the full flame of a gas blow-pipe thrown in the direction indicated by the arrow in Fig. 226. Heat thus applied will cause the solder to flow downward by gravitation and fill the interstices

in all parts of the investment as though it were an ingot. The best way is to apply solder a little at a time until the deep parts are filled. The flame is withdrawn for an instant, and with a small pointed flame and more solder the backing contoured. As platinum forms the cap and backing, the soldering can be conducted without fear of accidentally fusing those parts. Unless the soldering is conducted as described, the two seams of the cap should be previously soldered.

#### THE PARR CROWN.

This crown, which in form of construction possesses special points of merit, is largely used by Dr. H. A. Parr.

The root is prepared, banded, and capped without a pin, the same as for a gold collar crown (A, Fig. 227). A hole is made in the cap, and a post fitted in the canal. A piece of gold plate, fully the size of the cap on the root, is adjusted on the post above the cap by making a hole in the gold in which the post will fit tightly. The gold plate is then adapted to the cap on the

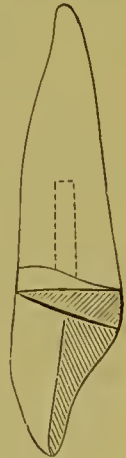
FIG. 227.

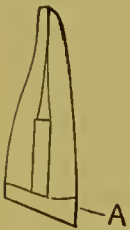

FIG. 228.

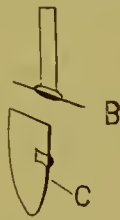

FIG. 229.



root, and burnished into any open space around the post, forming an outside cap; the pin and the outer cap are then removed and soldered together and adjusted on the inner cap, and the edge of the outer cap trimmed even with it (B). The porcelain tooth to form the crown, C, is fitted and attached to the outer cap, which, when finished, is cemented in position as shown in Fig. 228.

The advantage of this form of crown is that the root is securely and permanently capped independently of the crown, which can be removed without disturbing the cap on the root.


For use in crown- and bridge-work the outer cap may be made with a band which half encircles the inner cap, and tapers off from the palatal to the labial section, as illustrated in Fig. 229. The cap on the root is cemented with oxyphosphate, and the post and outer cap with gutta-percha.

#### THE LEECH CROWN.

Dr. Leech's crown is thus described by Dr. J. E. Dexter:<sup>1</sup>

"A method devised by Dr. H. K. Leech, of Philadelphia, shown in Fig. 230, and described in the *Dental Cosmos* for April, 1879, is as follows: The root is drilled out to a depth of about

FIG. 230.



three-eighths of an inch in diameter of about No. 16, standard (American) wire gauge, the bottom of the hole being flared or enlarged, and the canal above filled with gutta-percha. A gold tube is made to fit the hole accurately and project sufficiently for convenience of handling, and is soldered through a hole in a gold base struck to the root, projecting through the plate some distance. A plate

tooth is fitted to the root and plate and soldered to the latter, gold being flowed onto the plate and backing and around the projecting tube to form the palatal contour, and the tube cut off flush with the latter. We now have a plate tooth, gold backed, with a tube-pivot, the orifice of which opens on the palatal aspect of our tooth. The root-end of the tube is now slit perpendicularly in three or four places, for about two-thirds of its length, a thin sheet of warmed gutta-percha is placed on the base of the crown around the tube, and the whole is pushed securely to place. Now pack gold or tin into the tube, *condensing the bottom portions so that the slit end will spread and tightly fill the flared end of the hole in the root*, and the operation is complete."

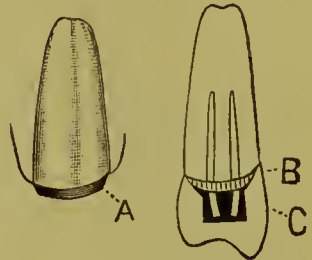
A collar crown fastened with a tube-pivot as described can be used to advantage in detachable bridge-work, as the tube if filled with tin foil will admit of the crown being easily detached.

<sup>1</sup> *Dental Cosmos*, May, 1883.

## THE PERRY CROWN.

Dr. Safford G. Perry, of New York, employs a porcelain crown in combination with a capped root. A bicuspid will be taken as a typical case to illustrate Dr. Perry's method. The end of the root, by trimming the edge, is given the tapering form shown at A, Fig. 231. The collar (B) is made very narrow. A cap made of platinum soldered with pure gold is fitted on the collar, and a post or posts fitted in the root and through the cap. Enough of the post is allowed to extend beyond the cap to attach and firmly retain the porcelain crown (C).

FIG. 231.



A suitable Howland-Perry porcelain (see page 50) crown (C, Fig. 231) is ground and fitted in proper position on the cap. This operation is facilitated by perforating a disk of marking-paper with the posts and adjusting it on the cap. Then, as the crown is placed on the cap and pressed against it, points which prevent perfect adjustment are marked on the porcelain. By this means a close joint is easily secured. The edge of the porcelain should be fitted under the free margin of the gum, especially at the cervico-palatal part. The porcelain crown is next set over the projecting pins, and cemented to the cap with oxyphosphate.

The advantage of this method is, that the root being slightly tapered, the collar can be made to fit absolutely, while the excess of oxyphosphate is gotten rid of through the vent-holes, instead of being squeezed out around the edge of the collar. The edge of the collar being made to a knife-edge, can be properly burnished before the crown is placed, so that it will not irritate the gum or make a shelf. The crown covers the cap, and can usually be ground and fitted so as to entirely hide any exposed portion of the collar, the junction of which with the cap should be trimmed and then rounded with a burnisher, to give a form which will better meet the interior of the porcelain cap or crown. The porcelain can be replaced at any time in case of fracture without disturbing the cap on the root. Easy repair, simplicity of construction, and artistic result, are the special features of this crown.

## CHAPTER XI.

### CROWNING FRACTURED TEETH AND ROOTS—CROWNING MOLAR ROOTS DECAYED APART AT BIFURCATION—CROWNING IN CASES OF IRREGULARITY.

THE crowning of fractured teeth and roots is a process that requires skill and delicate treatment. Its practicability depends on the nature of the fracture, the previous health of the parts, and the length of time that has elapsed since the occurrence of the injury.

#### LONGITUDINAL FRACTURE OF THE CROWN AND ROOT.

By this is meant a fracture extending lengthwise through the crown or what remains of it, and along the root or roots. Foreign substances having been removed from within and around the parts, the crevice of the fracture is syringed thoroughly with tepid water and then with peroxid of hydrogen. The

FIG. 232. fractured parts of the root are then drawn together with waxed floss silk, passed at least twice around the tooth, and tied, the ends being passed through twice in forming the knot. The pulp-chamber is then prepared, and dovetail slots are drilled across the parts (Fig. 232).



If it is suspected that in the preparation any particles of dentine have invaded the crevice of the fracture, the ligature must be removed, the parts again syringed, and the ligature readjusted. Aromatic sulfuric acid followed by the peroxid can be recommended for the final injections. The upper parts of the root-canals are then filled with gutta-percha, and the main body of the cavity and the slots with a hard, quick-setting amalgam. A collar crown should always be used in these cases. If the form to be used has a post, a short, small tube of gold or platinum



should be set in the amalgam in proper position to receive it. At the next visit of the patient the ligature is removed and the parts carefully prepared for crowning. The circumference of the root is first measured with a wire, a tight-fitting collar constructed, and the crown then completed in the usual manner. The crown may be favored by leaving a slight space between its occluding surface and the antagonizing tooth.

The great drawback in these cases is that the patient generally fails to present himself immediately for treatment, and foreign substances work into the fracture, causing inflammation, which is difficult to control. Often subsequent to treatment a septic condition of the fracture supervenes, the irritation caused thereby and the exudations from the fracture becoming so annoying that extraction is the only alternative.

Teeth fractured as above described are rarely found with living pulps.

#### FRACTURE OF THE CROWN WITH SLANTING FRACTURE OF THE ROOT.

Fractures of this kind are common, especially in bicuspid, where large fillings are inserted extending from the anterior to the posterior approximal walls, leaving the separated buccal and palatal cusps to bear the brunt of mastication.

In such cases the fracture seldom extends beyond the edge of the alveolar process. The fractured part having been carefully

FIG. 233.

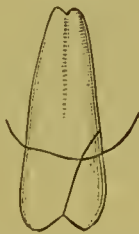
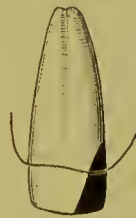
FIG. 234.



removed, a dovetail slot is made in the crown or root, in which gutta-percha is inserted for a day and the membrane of the gum pressed back, so as to fully expose the surface and margins of the fracture. The form of the neck is then in a measure restored with amalgam, which, when hard, is polished (Figs. 233 and 234).

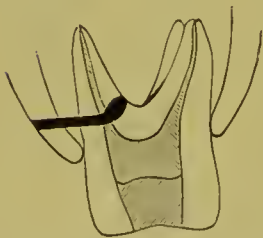
The tooth or root is then crowned, the mode of operation being the same as in any other case.

**PERFORATION OF A SIDE-WALL OF A ROOT-CANAL OR OF THE DENTINE AT THE BIFURCATION OF THE ROOTS.**

Extensive perforation by decay in these locations below the line of the edge of the alveolar process seldom admits of successful treatment. When the decay is of limited extent, and a very slight perforation has been produced by its thorough removal or by the improper or careless use of a bur, cicatricial tissue may be induced to form over the part by creating and maintaining a sterilized condition, and then sealing the cavity.

The method of procedure is as follows: First effect sterilization of the dentine and canals. Bathe the perforated part with peroxid of hydrogen. Dry the canal thoroughly. Bathe the edges of the perforation with chloroform. Fit closely over the perforation a small, flat piece of gutta-percha, warmed and applied with a gentle pressure, sufficient only to produce adhesion without forcing the gutta-percha through. The filling of the canal can then be carefully completed. Oxychlorid of zinc is the most suitable in these cases, as no pressure is required, and a dense antiseptic filling in the roots and over the cap on the perforation is the result. If this method proves unsuccessful and inflammation

FIG. 235.

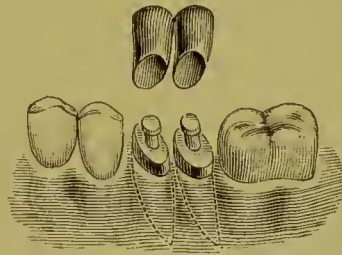


ensues, the position of the perforation should be carefully calculated, and an artificial fistula should be formed on a direct line with it through the gum and alveolar process (see Fig. 235). Carbolic acid may be used as described at page 33, to obtund the tissue. The necessary perforation through the alveolar process should be small in diameter, and be made with a drill. Injections can be made outward through the fistula, and the perforation sealed with gutta-percha similarly to the closing of a foramen in cases of alveolar abscess.

**CROWNING MOLAR ROOTS DECAYED APART AT THE  
BIFURCATION.**

The roots of a molar decayed apart at the bifurcation can often be crowned serviceably by making a cap for each root separately,

FIG. 236.



and then soldering the sides of the cap together (Fig. 236). Where one root is missing, the other can be crowned singly.

**DR. FARRAR'S CANTILEVER CROWN.**

Figs. 237 and 238 represent Dr. J. N. Farrar's cantilever crowns. He describes them as follows: Fig. 237 illustrates a sectional view of three teeth, and an amputated first bicuspid root preserved by a screw, showing the application of the cantilever crown T P, set upon the decayed second bicuspid and

FIG. 237.

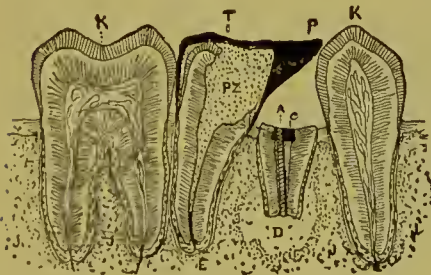
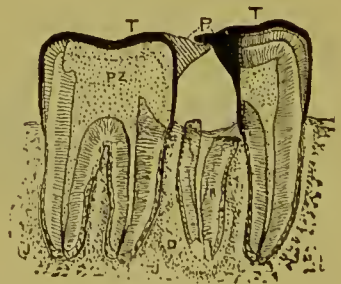


FIG. 238.



made to project over to bridge the space formed by the loss of the first bicuspid, and resting in contact with the cuspid so as to connect the broken line of masticating surfaces and prevent tilting forward of the second bicuspid. The abscessed root here shown was extracted.<sup>1</sup> Fig. 238 illustrates the appearance of two

<sup>1</sup> *Dental Cosmos*, vol. xxvi, No. 3.

molars, the posterior half of one of which is destroyed, showing also the application of two cap-crowns, which are constructed so as to form a cantilever bridge over the chasm by locking midway in such a manner as to prevent tilting or sliding of surfaces, and at the same time be easily cleansed by a quill or thread.

METHODS OF CROWNING IN CASES OF IRREGULARITY.

FIG. 239.

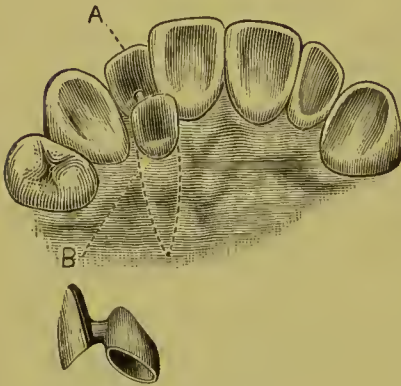
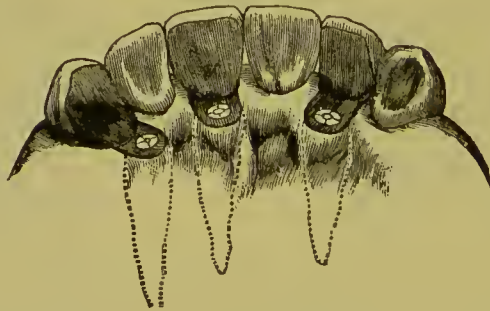

Fig. 239 shows a method of treating a case of irregularity without destroying the vitality of the pulp. The tooth at B, which stood inside the line of the lower teeth when the mouth was closed, was trimmed, shaped, and capped. To this cap was attached the tooth at A, with an oval-shaped piece of gold that cleared the lower teeth in occlusion. The cap was then cemented to the natural crown.

Fig. 240 represents a case of irregularity treated by Dr. Bonwill, who says in his description of it,—

“This shows a case of irregularity which was beyond correction, on account of the poor character of the teeth, their position in the palatal arch, and the age of the patient. In such cases I

FIG. 240.



do not hesitate to cut off the crown, destroy the pulp, and insert an artificial crown. The crown is brought in the circle and connected with the root by a strip of heavy gold plate. The plate is attached to the root with a post or a screw with a nut.”

## CHAPTER XII.

### PARTIAL CROWNS.

*Gold.*—Partial crowns of gold for the protection of plastic fillings in large cavities and for the restoration of contour are often desirable when, for any reason, a solid metallic filling cannot well be inserted. The cavity having been properly excavated, its orifice is trimmed as uniformly straight or circular as its position and character will allow, and the edge of the enamel beveled off, tapering toward the center. In the preparation of cavities in the grinding-surface, trimming and cutting away the enamel should be confined to that surface. In approximal cavities which reach the grinding-surface, it is advisable to extend them into that surface and bring the gold over and anchor it there, so as to afford greater security against its displacement in mastication. Where decay extends close to the margin of the gum, if the tooth is trimmed away so that the gold will extend just under its free edge, a recurrence of decay at that point will be avoided. The bicuspid shown in Fig. 241 will serve as a typical case to illustrate the constructive details.

FIG. 241.



The cavity having been properly prepared, a die of the tooth in its original form is then secured. For this purpose the mold is made by taking an impression of the tooth with wax, making a plaster model, and then restoring the contour and forming from it the mold in gutta-percha or moldine; or the shape of the natural tooth may be restored with wax or gutta-percha and the mold made directly from it in plaster. The die and counter-die having been formed (see article on "Molds and Dies"), a piece of pure gold, No. 28 to 30 standard gauge, the exact thickness being governed by the size and nature of the cavity, is struck up to the form and size of the part to be capped. The gold is

then adjusted to the cavity, to the margin of which the edges are trimmed and burnished to fit close and flush. In the case of large cavities including a part or the whole of the approximal surface, a model of the tooth and of the empty cavity from an impression taken in wax will sometimes facilitate and guide the preliminary trimming and shaping of the gold. Two headed pins fixed on the inside of the cap (Fig. 242) are usually sufficient

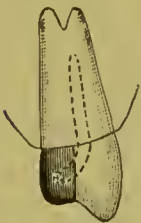
FIG. 242.



FIG. 243.

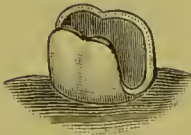
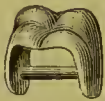
FIG. 244.



to secure it, but others can be added if the conditions of the case seem to require it. In compound cavities, including one side and the grinding-surface, one pin at least should be fixed in the latter portion. Where the grinding and both approximal surfaces are included, a wire should be extended from one side to the other (Fig. 243), but the brace should not touch the bottom of the cavity.

In pulpless teeth the pin from the upper part of the cap should extend up the canal, which gives great stability in such cases (Fig. 244).

In soldering the pins or loops when inserted in holes drilled in the gold, a little solder can be flowed over the adjacent parts if deemed necessary to stiffen and strengthen them.

Oxyphosphate, as a rule, is preferably used for the cementation of these caps, as it forms a solid and unyielding foundation, and, when properly protected from the fluids of the mouth by a carefully adjusted cap, is very durable.

The cement should be first inserted in the cavity, and then a small quantity placed around the pins of the cap, which should be immediately adjusted accurately in position. When gutta-percha is used, it is heated and applied in the same manner to cavity and cap. The cap is then heated, pressed into position, and held there until the gutta-percha hardens. This can be hastened by the application of cold water from a syringe. The surplus of gutta-percha is then removed, and the edges of the gold burnished.

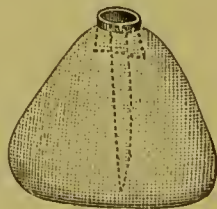
These caps applied to teeth with living pulps show durability

of a commendable character. The advantage they possess over pieces of porcelain is found in the close joint that can be made with the edge of the enamel by burnishing the gold against it.

*Solid Gold Inlays.*—The walls of at least the aperture of the cavity are trimmed straight. No. 60 platinum foil is adapted to the interior of the cavity and just over its edges by the aid of burnishers and cotton twisted on the end of an instrument, assisted by frequent annealing of the platinum. The matrix thus formed is then filled with wax, chilled, and removed from the cavity and invested, after which fine gold or 22-carat solder is melted into it. The removal of the matrix from the cavity can be facilitated by the insertion in the wax of a pin or a short piece of wax, which is grasped with tweezers. The plug of gold thus formed is properly trimmed and polished, and cemented in the cavity of the tooth. When completed, it has the appearance of a gold filling. If necessary, the cavity can be previously partly filled with amalgam or shaped with it, to give a better form to permit the removal of the shell of platinum foil. Plugs so made can occasionally be utilized as an anchorage for bridge-work.

*Solid Gold Tips* are made for abraded pulpless teeth in preference to fillings in the following manner: An opening is made through the occluding surface of the crown into the root-canal. A flat post, wide enough to fit closely in the pulp-chamber across its greatest diameter, thus tending to prevent any rotary motion of the gold tip, is then formed. A very thin piece of pure gold plate, say No. 30 U. S. gauge, is adapted and burnished, with hand-burnishers and Herbst's revolving agate points, into all the irregularities of the abraded surface, and into the orifice of the pulp-chamber. The gold is then trimmed flush and even to the edges, and burnished just over them. An opening is next made in the gold cap, and through it the post is inserted in position. A strip of thin gold plate or platinum foil is next adapted around the tooth, well over and above the edge of the gold cap, and trimmed to the length desired for the tip. With the gold cap and post placed accurately in position, the cavity formed by the strip of plate or foil encircling the tooth is filled with wax cement,

FIG. 245.

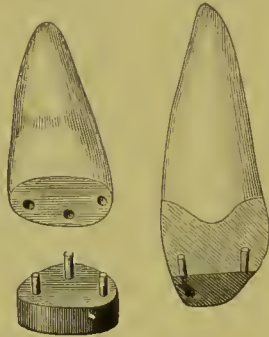


and cap, post, and plate or foil removed and invested to the lower edge of the latter (see Fig. 245). The investment is then heated, and 20-carat gold plate or solder melted into the matrix formed by the plate or foil over the cap. The surplus gold is then trimmed to the edge of the abraded surface of the tooth and to the desired form for the tip.

FIG. 246.

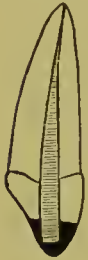

FIG. 247.



When finished, the gold tip is cemented in position with a thin mixture of oxyphosphate. Fig. 246 gives a sectional view of a central incisor tipped in this manner.

*For Gold Tips in Cases of Living Pulp*, two or three small platinum pins, as the case may suggest, are used in holes drilled about the pulp-chamber, in the manner shown in Fig. 247.

If three pins are used, it is seldom necessary for stability to extend the plate beyond the incisive surface, over the palatal side of the tooth. In a case with a vital pulp and in a pulpless tooth, if the gold tip required is short, the ends of the pins extending above the cap will hold and maintain enough solder in position to give material for proper contouring, without enveloping it with a matrix of platinum or gold foil as previously described.<sup>1</sup>

*Porcelain and Gold.*—The partial restoration with porcelain and gold of an incisor crown such as is shown in Fig. 248 is often desir-

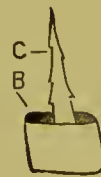
FIG. 248.



FIG. 249.



FIG. 250.



able. The edges of the crown to form the joining with the porcelain are trimmed straight and level, and then polished. A shallow

<sup>1</sup> An experience of several years in the use of gold tips as described shows that they are much to be preferred to tips formed of gold foil, even by the very best operators, the alloyed gold being superior to pure gold in resisting attrition.—G. E.



groove is generally formed to advantage at A, Fig. 249. A very thin piece of platinum is then adapted to the crown as shown at B, Fig. 250. The pin C is fitted to the root-canal, passing through the platinum. The post and cap of platinum are then attached with wax, removed, invested, and soldered with pure gold. A little of the gold at the same time is flowed over the cap. The cap and post are then adjusted to the crown, and the cap is trimmed level and burnished closely against the surface of the portion to be restored and into the groove at A, Fig. 249. At this stage of the work, to facilitate the subsequent operations, an impression can be taken which will remove in it the cap, and from this a model can be made. A cross-pin porcelain tooth is then ground down to a size and shape that will properly restore the part and form an accurate joint with the labial edge of the natural crown. The porcelain is then backed, cemented to the cap, removed, and soldered with 20-carat solder. The partial crown when properly finished is cemented in position with oxyphosphate.

In a case such as is represented in Fig. 251 the cap is shaped to the surface of the dentine and enamel at A and over its palatal edge, and the backing on the porcelain is extended out over the palatal edges of the enamel at B. The two sections of the platinum are united in the soldering.

FIG. 251.

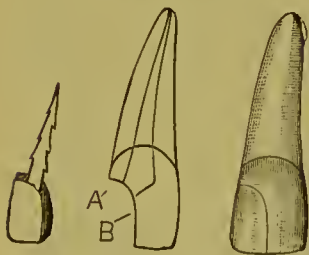


FIG. 252.

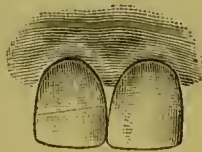


FIG. 253.



Fig. 252 illustrates a fractured central incisor in which the pulp was not exposed, restored with porcelain by Dr. J. Bond Littig, of New York. The cap to the fractured part was fastened by three small pins as shown in Fig. 253, which illustrates the details of the construction.

“Where the piece broken off is so narrow that the porcelain tooth cannot be ground to fit in the ordinary way, without cutting out the pins,” Dr. Littig describes his method as follows: “First cut a groove in the end of the broken tooth, making slight undercuts. The pins of a suitable porcelain tooth are bent outward, and the ends flattened. The porcelain is then ground away from both ends, until it is made as narrow as the natural tooth is thick or nearly so. The piece is fitted to the end of the tooth by placing the pins in the groove. If the joint is not good, grind away from either tooth or porcelain until it is perfect.

FIG. 254.



Then set the piece with zinc phosphate, and after it has become hard, grind the tip to shape in the mouth, and polish with moosehide disk and pumice-stone. Fig. 254 illustrates the second method; the ground porcelain tip, prepared crown, and restored tooth being shown separately.” Dr. Littig’s third method is to first cap the fractured part with platinum, allowing the ends of the pins, which are soldered with pure gold, to project below the cap. English porcelain body of the desired form for the tip is then baked on the cap. The porcelain by this method is secured to the platinum forming the cap, by the platinum pins embodied in it.

FIG. 255.

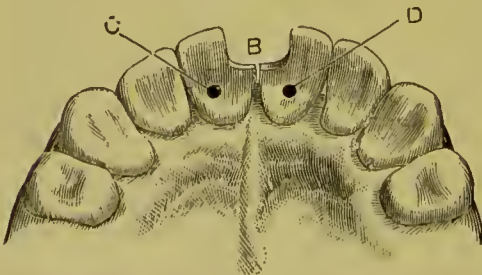


FIG. 256.

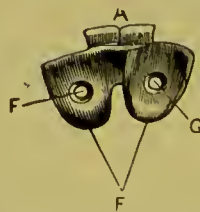


FIG. 257.



Figs. 255, 256, and 257 show how Dr. W. F. Litch’s pin-and-plate process may be utilized for the attachment of sections of

porcelain broken or decayed incisors, when the appearance of gold fillings is obnoxious to the patient. A represents the porcelain tips; B, the space to be filled by them; C and D, the openings for retaining-pins; F and G, openings in the base-plates (E) for the pins. Fig. 257 shows the appliance with pins attached. Figs. 258 and 259 illustrate a case in which the contour of a single incisor tooth was restored in this manner. Fig. 258 shows the palatal aspect of the tooth, in which the openings for two retaining pins were drilled, the openings being made quite small. In Fig. 259 is seen the porcelain tip attached to the plate and ready for mounting. The two retaining-pins will be observed soldered to the plate. In this case the cervical margin of the natural tooth was made level to afford a secure resting-place for the porcelain tip.

Dr. C. H. Land, of Detroit, employs porcelain partial crown-work in cases of the character here described. He first forms a dovetail cavity in the central portion of the section to be tipped or contoured, and then adapts, aided by frequent annealing, a piece of platinum foil (No. 60 U. S. gauge) to the cavity and surface of the part, by means of burnishers, and a pellet of cotton twisted on the end of an instrument. The platinum is then removed, and on its surface porcelain body is placed, and baked in the muffle of a furnace. (Dr. Land's Midget Furnace, Fig. 260, is the most suitable for the purpose, as each baking of the porcelain can be

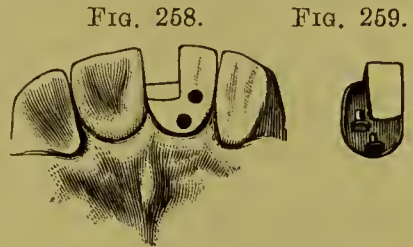
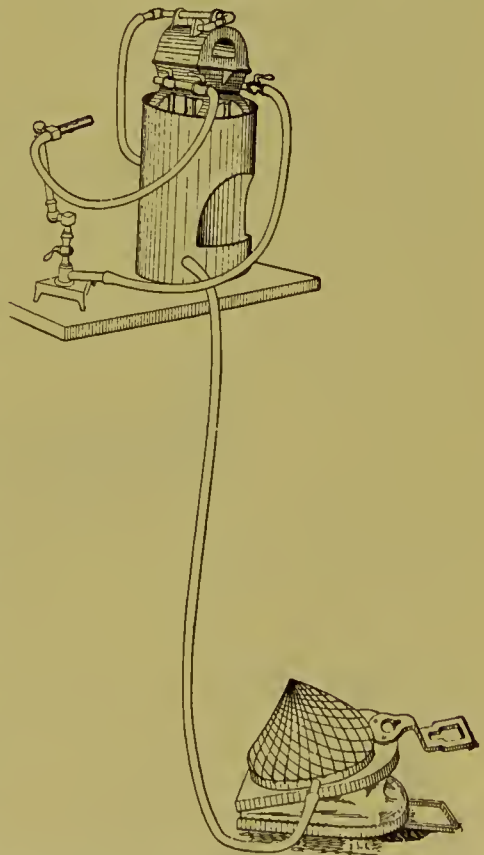


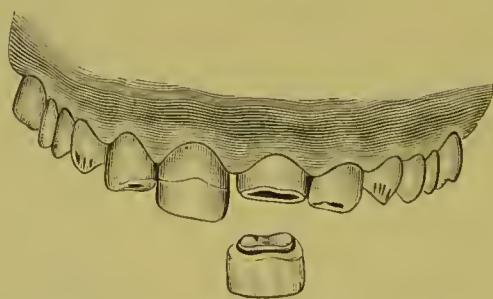
FIG. 260.



performed in about ten minutes.) After the first baking, the thin platinum, which is usually warped by the shrinkage of the porcelain body in the baking, is corrected by readjustment to the tooth, in doing which the porcelain is usually fractured. The interstices and fractures in the porcelain are then filled, the part properly shaped with body, and the porcelain rebaked, and again adjusted and fitted in position. The platinum is next trimmed free of the edge with a corundum-wheel, and the porcelain shaped accurately to the form desired. Any imperfections existing are again filled with body, and the final baking given.

Dr. Land claims that in such cases porcelain, if fitted to the irregularities of the cavity, will be securely retained when cemented with oxyphosphate. An additional attachment is obtained by placing a piece of iridio-platinum wire across the retaining cavity of the tooth, with the ends caught or bent against the sides, and then forming a dovetailed groove across the base of the porcelain tip, which will receive the wire. When a porcelain tip is desired without the platinum base, after the final baking, the platinum is removed by tearing it off the porcelain. When this is the intention, the platinum should not previously be trimmed close, but should be left extending around

FIG. 261.



and slightly beyond the edge of the porcelain. Fig. 261 illustrates a case of atrophy,<sup>1</sup> in which the tips of the central incisors were contoured with porcelain by Dr. Land. The right central shows the porcelain in position, and the left the porcelain tip ready to be adjusted.

<sup>1</sup> This operation was performed by Dr. Land at the meeting of the First District Dental Society of the State of New York, in January, 1889.

## CHAPTER XIII.

### FINISHING AND POLISHING—PROCESS OF CEMENTATION.

#### FINISHING AND POLISHING CROWN-WORK.

THE finishing should be done with small corundum or Gem wheels and points, first coarse, then fine, on the dental engine, which, for this part of the work, is preferable to files or the lathe. Gem wheels may be used dry when desired. This is an advantage in trimming certain parts of the metal, as corundum must be kept wet. In the final finishing use fine pumice with leather polishing-wheels on the engine, or felt wheels on the lathe; and, in the polishing, a brush wheel, with whiting and rouge on the lathe.

The gold should first be properly shaped, which includes trimming the collar off to a fine edge where it fits under the gum, so that the seam of union with the root will be imperceptible. The gold that has been placed on the incisive edge of the incisor and cuspid crowns should be trimmed away, so that although it will protect the porcelain, very little if any gold will be seen when the crown is in position in the mouth.

#### INSERTION AND CEMENTATION.

In the insertion and cementation of all crown- and bridge-work, the object to be effected is the same in principle, that is, to form with an insoluble material a solid, substantial, and impervious union between the natural tooth or root presented and the artificial crown.

#### OXYPHOSPHATE OF ZINC.

As a cement for this purpose, the plastic oxyphosphate of zinc is generally preferred, and it is in many respects one of the most suitable that has as yet been found. If at all exposed even the best preparations are slowly soluble in the mouth, and the porosity of the compound permits it to absorb gases and fluids

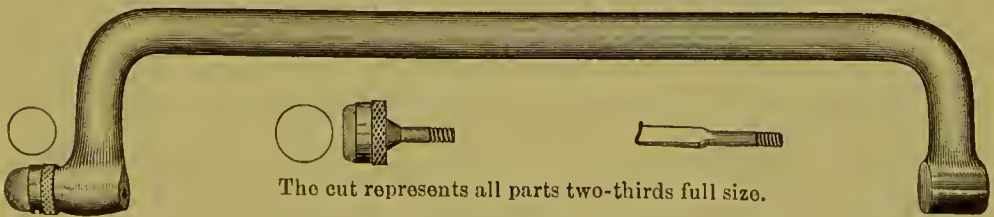
and gradually become septic. Exact scientific proportions of the chemical substances of which the cement is composed are essential in its preparation. The oxid of zinc should have been calcined at a high heat, and then ground to a very fine powder. It should possess the property of being uniformly dense and hard clear through the center, when set, after being mixed thin and formed in a mass.

The setting of the best preparations of pure oxyphosphate of zinc is materially affected by temperature. Thus, a cement which is slow-setting at 40° F. is apt to be quite quick-setting at 80° F. In some of the preparations of cement, an effort is made to remedy this variation by adulterating with various substances, but this tends to increase the solubility of the compound. A standard preparation of cement, answering the requirements previously outlined, should be used in crown- and bridge-work. For all styles of crowns with collars, and for bridge-work depending on crowns of similar construction, the cement should be mixed thin; but for crowns without a ferrule or collar it can be moderately thick. For mixing the cement, a piece of plate-glass about five inches long and three inches wide as a slab, and a small spatula, are suitable. The surface of the slab must be perfectly clean. The acid and powder should first be separately placed on the glass, the amount of powder being fully equal to the requirements of the acid. A portion of the powder should be drawn over and mixed with the acid, and then more of the powder added, a little at a time, until a suitable consistence is reached, when the surplus powder should be instantly thrown off the slab, and the mixing, which must be rapid and thorough, continued; the consistence should be that of thick cream. It is not a good plan to mix cement excessively thin, and then wait until it becomes thickened by the process of setting to a consistence suitable for use. The resulting compound is unnecessarily acid, the overplus of acidity being proportioned to the excess of acid used over the quantity required, and its character as a cement impaired. On the other hand, if mixed too thick, force is required to bring the crown or cap to position, and the thin edges of collars are liable to be sprung from the sides of the roots; neither will the cement adhere with such tenacity to the

parts as when mixed at a proper consistence. If the slab is placed on a towel which has been saturated with ice-water, the cold will retard the setting, which is quite an advantage in many cases. In this respect the side of a square bottle filled with ice-water and well corked is preferable to a slab.

The parts to be crowned should be previously syringed with water and peroxid of hydrogen if the gum-margins are slightly lacerated, then protected by a napkin, bathed with alcohol applied on cotton with tweezers, and dried with absorbent cotton or bibulous paper. A rope of twisted absorbent cotton may be wound around each natural crown and pressed close against the gum, with the ends twisted together at the labial side so that the cotton can be easily seized and instantly removed at the moment the cement is ready. Each cap or crown, which should have been thoroughly dried, is first filled with enough cement to insure a slight surplus. A small portion is then put in each root-canal or hollow part of a natural crown present, and the artificial crown or bridge immediately adjusted in position. In many cases it is best to quickly remove the napkin and close the mouth to insure the occlusion of the teeth, and then open the mouth and replace the napkin. The crown or bridge should be held under a slight pressure until the cement has set. For this purpose a piece of wood notched on the end, or a crown-driver<sup>1</sup> (Fig. 262), can be used. With bicuspid or molar

FIG. 262.



crowns and in bridge-work, however, it is better in most cases to occlude the teeth, and keep them in position under a steady pressure until the cement sets. Under these circumstances the saliva can reach only the surplus portion of the cement, and

<sup>1</sup> This instrument can be used to fit a tight collar or crown. It also has a pull-off attachment which is handy in removing crowns.

cannot interfere with that under the cap or crown. One or two thicknesses of tin foil, placed over the crown as the teeth are occluded, will slightly favor the length.

When the cement has set perfectly hard, the surplus around the edges should be removed. In collar or shell crowns the extreme edges of the gold of the collar or shell should be given a final burnishing. Excessive burnishing and force, though, should be avoided, as tending to injure the cement under the collar. Wet floss silk or dental fiber, charged with pumice, should be passed between and around the teeth to remove every particle of the superfluous cement, and finally the parts should be syringed with tepid water.

The patient should be requested to call in a few days, so that an examination may be made to see if any particles of the cement were overlooked. Cleansing gently at this time facilitates the healing of the gum around the collar or neck. Care in these little details tends to prevent that inflamed appearance and recession of the gum often seen around crowns, and also insures a satisfactory result to the patient and commendation to the dentist.

Previous to insertion the posts of crowns should be slightly barbed. By encasing the post with a film of gutta-percha it is made easily removable, which is a desirable feature in crown- or bridge-work. This is done by warming the crown to a point that will heat the post, and then painting the post with a thin coat of chloro-percha. The heat instantly evaporates the chloroform, leaving a thin film of warm gutta-percha adhering to the post. The crown is then instantly placed on the root and removed. This defines the relations of the gutta-percha on the post to the walls of the canal, and indicates any slight surplus if present. Cementation with the oxyphosphate completes the operation. At any time, by warming the crown, the thin sheath of gutta-percha is softened and the attachment of the post may be easily broken. This method of setting the post makes bridge-work, so supported, easily detachable. A film of gutta-percha placed in the grinding-surface of a gold cap will also provide a similar advantage in case of a gold crown. The gold cap should be first heated, the gutta-percha inserted, and the cap



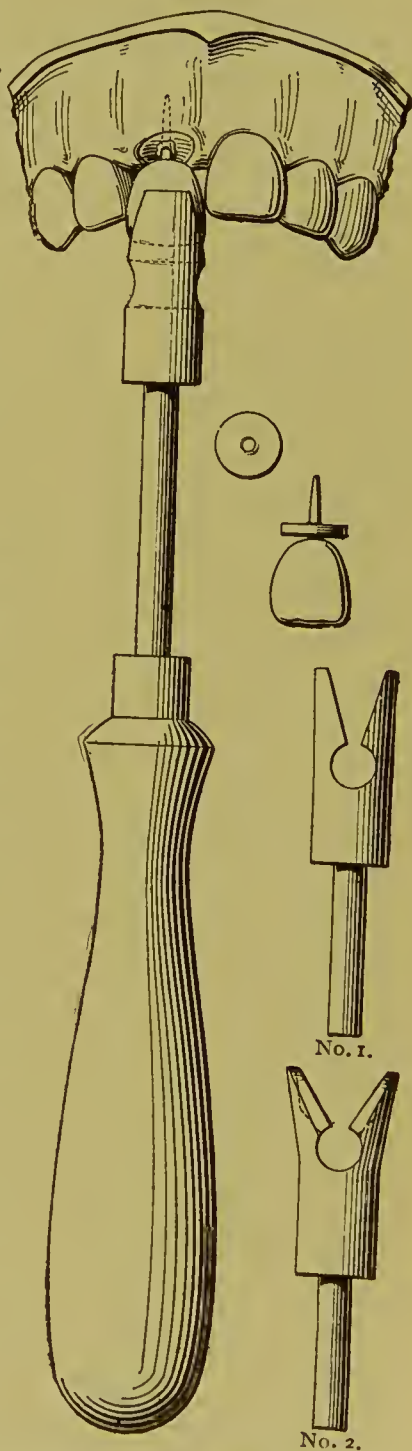
adjusted and removed and the amount and position of gutta-percha exactly determined. The cementation is then conducted as without the gutta-percha. In all-gold cap-crowns a vent for the escape of air and surplus cement is made by some in the form of a small hole, usually in the deepest fissure of the grinding-surface, but it is a practice that is now being generally discarded. When the cement has hardened, the hole must in all cases be closed with a gold or amalgam filling.

#### GUTTA-PERCHA.

When gutta-percha is used, heat the crown. Paint the post and the base of the crown, and any recesses in the latter, with a very thin solution of chloro-gutta-percha. The heat instantly evaporates the chloroform, leaving a mere film of gutta-percha tenaciously adhering to the parts. Fill the recess and cover the base of the crown with a perforated disk of gutta-percha, and press the crown to position on the root. Let the gutta-percha cool slightly, remove the crown and trim the surplus from the edges; wipe out the canal with chloroform, dry with cotton and hot-air syringe. Next place on the post or in the canal enough gutta-percha to insure a very slight surplus, heat the crown, and press to place.

A crown-setter, as illustrated in Fig. 263, assists in setting with gutta-percha. Heat the copper end sufficiently to soften the

FIG. 263.



gutta-percha, and place the grooved end over the crown with the heated copper in contact with the porcelain. Hold the setter against the crown until the gutta-percha becomes soft, when pressure applied to the setter forces the crown with its pin to its proper position. The cooling of the gutta-percha can be hastened by dipping the crown-setter in a tumbler of ice-water and holding it against the tooth until it is cold. When the gutta-percha is cold, the surplus is removed with a warmed sharp instrument, and the edges smoothed by drawing back and forth against them some twisted fibers of cotton or floss silk saturated with chloroform. Sometimes it may be desirable to fasten the post with oxyphosphate and join the end of the root and artificial crown with gutta-percha. In such a case the crown should be heated and the gutta-percha, rolled down very thin, placed on the edges to be united in the form of a perforated disk. The crown is then pressed to position in the oxyphosphate placed in the root. The order of the use of these materials should be reversed where it may be desirable at some future time to easily remove the crown.

*Bridge-work* can be conveniently attached temporarily with gutta-percha. In this event a quantity barely sufficient to fasten the caps should be used. Gutta-percha does not possess sufficient rigidity for general use in bridge-work, but certain styles can be advantageously cemented with it. In such cases the same procedure is followed respecting the posts of crowns as has been above described. The bridge is heated, a gutta-percha which softens at a low temperature placed on each post and in each root, cap, or gold crown, a trifle less in quantity than is needed, and the bridge inserted in position and in a moment removed. More gutta-percha is then added to such parts as require it, and the bridge is again warmed and inserted. This operation is repeated until the exact amount of gutta-percha required is ascertained. During the fitting, the natural teeth and roots should be protected from the saliva and their surfaces slightly moistened with oil of cloves or cassia, to prevent adhesion of the warm gutta-percha. For the final adjustment the roots and teeth should be washed free of the essential oils, again protected from the saliva, wiped with chloroform on cotton and

dried with the hot-air syringe. A very small piece of gutta-percha is placed in the center of each cap for surplus. The bridge is then heated as warm as it is possible to handle, inserted in position, and cooled with water from the syringe. Any surplus of gutta-percha, which, if it has been properly proportioned, is very slight, can then be removed as described in the case of a single crown.

#### AMALGAM.

Amalgam is used to some extent to support and retain porcelain crowns. Its use in connection with the Gates-Bonwill crown is given on page 48. Where it is desirable to use amalgam, Dr. Kirk gives copper amalgam the preference to other kinds as an attachment for the Logan crown to weak or badly-decayed roots. The following is Dr. Kirk's method for the adjustment of Logan and similar classes of crowns, which he has found satisfactory in those extreme cases where there has been much loss of root-structure through the action of caries in the pulp-canal, resulting in a large funnel-shaped opening with more or less weakened root-walls.

The canal is prepared by removing the softened structure, filling the apex, and making suitable undercuts or roughnesses along its walls, and then filled flush with its orifice with a good grade of copper amalgam softened to a plastic, buttery condition. The apical end of the crown pin is sharpened to a point or hatchet edge as may be most expedient, and placed against the amalgam surface in the root-opening, and the crown at once driven to place in close contact with the root by holding against its morsal (occluding) surface a suitable point mounted in the Bonwill mechanical mallet. For this purpose, the blow of the mallet should be considerably increased in intensity beyond that ordinarily used for filling-operations. The point used in the mallet for driving the crown home is best improvised from a porte polisher armed with a hickory point, the use of which avoids chipping the porcelain. All excess of copper amalgam is by this means driven out between the surfaces of contact of the crown and root in precisely the same manner as occurs in the use of oxyphosphate. An excess should be used in order

to be sure of filling all interstices. This method, involving the use of copper amalgam, is advocated only in the class of cases described, for which it possesses the advantage of giving complete support to the root, because of the great strength and insolubility of the material employed. Other amalgams experimented with for this purpose have not been so satisfactory, because of their lack of plasticity, and of the flowing quality which characterizes the copper amalgam when subjected to the rapid vibratory percussive force of the mechanical mallet blow.

PART III.

---

BRIDGE-WORK.



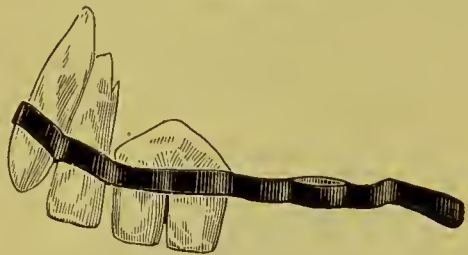
## BRIDGE-WORK.

THE artificial replacement of the loss of a portion of the teeth by bridging the vacant spaces with substitutes, supported in position by means of their attachment to adjoining or intervening natural teeth, is, as we have seen in the introduction, of antique origin, having been practiced long before plates came into use.

FIG. 264.

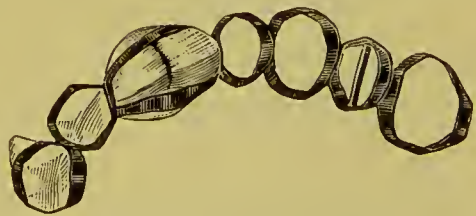

FIG. 265.



Originally, the application and mechanical construction of such dentures was of a most primitive character; and as the attachments were simply ligatures or clasps of gold, the teeth were more ornamental than useful. Figs. 264, 265, and 266 illustrate the antique methods.<sup>1</sup> Fig. 264 is an illustration of a specimen of ancient Phœnician dentistry. Fig. 265 is that of one in the Etruscan age, dating about five hundred years B.C. Fig. 266 gives a view of the same denture inverted.

FIG. 266.



Dentures constructed on the bridging plan by various methods have been occasionally employed from the earliest days of modern

<sup>1</sup> See *Independent Practitioner*, vols. vi and vii, "Evidences of Prehistoric Dentistry," by J. G. Van Marter, D.D.S., Rome, Italy. Figs. 269, 270, 271, are copies of the illustrations of the specimens, the first of which is represented as being in the museum of the Louvre, Paris, France, and the second in the Corneto Museum, Corneto, Italy.

dentistry, though until recent years the system has not obtained general recognition nor been extensively practiced.

Dental literature presents bridging operations as described by J. B. Gariot in 1805, C. F. Delabarre in 1820, Dr. S. S. Fitch in 1829, William Imrie in 1834, J. Paterson Clark in 1836, and Dr. W. H. Dwinelle in 1856. Figs. 267 and 268 are copies of illustrations in Dr. Fitch's work, published in New York in 1829, and Fig. 269 one from a translation of F. Maury's work in 1843. In 1871 the bridging process or bridge principle was again brought to notice by a patent applied for in England by Dr. B. J. Bing, of Paris, for an improved means of supporting

FIG. 267.

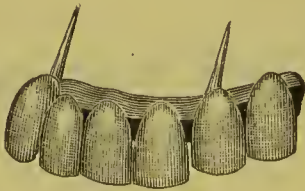


FIG. 269.



FIG. 268.

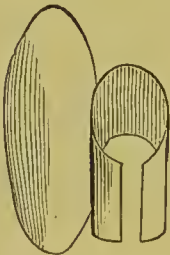
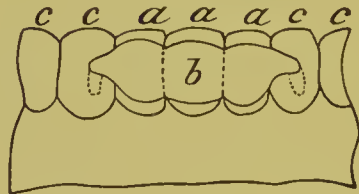


FIG. 270.



and securing a bridge by anchoring with cement or fillings clasps or bars extending from it into holes formed in the adjoining teeth (Fig. 270). The system was also practiced in operations by the late Dr. M. H. Webb, and is described in his "Notes on Operative Dentistry."

The facilities afforded by the artificial crown-work now in vogue for supporting and securing bridge dentures have caused a revival of the system in an improved form, now termed "Bridge-Work," in which artificial crowns cemented to natural



teeth or roots are employed as abutments to support artificial teeth which span or bridge the spaces between them. These bridges are so devised, in the best methods, that while supplying the patient with the means of masticating his food, the cleanliness of the denture is also provided for.

Ordinarily, bridge-work is immovably cemented in position. The claims set up in its favor are as follows :

First. The perfect replacement of lost teeth by artificial ones, and without the use of a plate.

Second. The absence of any mechanical contrivance to interfere with the tongue in articulation.

Third. The natural teeth are not abraded by the presence of clasps, the functions of the sense of taste are more perfectly performed, and a healthy condition of the tissues preserved, because the gums and palate are not covered over with a plate.

Fourth. The solidity and immovability of the denture at all times, both in speech and mastication.

Fifth. The weight of the denture and the strain of mastication are proportionately distributed on the natural teeth, which are better suited to sustain them than the contiguous alveolar surfaces.

Sixth. Its special adaptation to the replacement of single teeth, or of a small number, where bridge-work is usually superior to any other device.

Seventh. While all operations performed for the restoration of lost teeth, like other remedial operations, are temporary rather than permanent in their results, bridge-work as regards permanency takes equal rank with any other operative procedure.

The following, on the other hand, are the objections raised against bridge-work :

First. It fails to restore the contour of the soft tissues above the bridge, as artificial gums cannot properly, in most cases, be used in this style of work.

Second. The slots beveled under the artificial teeth, called self-cleansing spaces, fill with particles of food.

Third. The speech and comfort of the wearer are often affected by these self-cleansing slots under the front teeth.

Fourth. The teeth employed as abutments are usually irreparably destroyed by the process of crowning.

Fifth. If an extensive bridge is made of gold, being immovable, it is impossible to keep it perfectly clean, as the metal will gradually tarnish in parts out of reach of the brush, and will gather offensive matter on its surface and in its interstices.

Sixth. In cases where it becomes necessary to temporarily remove the bridge for the purpose of repair, or because of disease in the teeth which support it, the operation is difficult and the bridge is usually injured so as to unfit it for reinsertion.

Seventh. The teeth which support the bridge are required to bear more force and pressure than nature intended,—where the piece is large many times more,—and, the bridge being permanently attached, at no time can any rest be given the abutments or the contiguous parts by its temporary removal. Thus in a piece of bridge-work of fourteen teeth supported by caps or crowns on four natural ones, each one of the natural teeth may have to bear more than three times the strain in supporting the weight of the denture and the force of mastication, that was intended. The ultimate result is evident to any one who is experienced in dental practice; and unless the anatomical conditions are most favorable, the usefulness and durability of such work is decidedly limited in character, considering the time, trouble, and great expense attending it.

Such are the objections which have been put forth against bridge-work; and yet, whatever may be urged against it, its advantages have won from a majority of the profession, including many accepted authorities, an enthusiastic, almost a sensational, indorsement; some practitioners even going so far as

to proclaim it the only true method for the insertion of artificial teeth.

Judged impartially, bridge-work has many advantages when practiced by experts who properly construct and apply it. Without doubt it has been, and is still, abused. Bridges have been inserted where the support was insufficient, or the construction was wrong in principle or faulty from lack of skill. More than this: bridge-work has been passing through the experimental period, when failures are apt to appear more prominently than successes. The chronicles of dental literature, however, in this respect offer only a repetition of the historical difficulties that attend all new departures in the arts.

## CHAPTER I.

### CONSTRUCTION OF BRIDGE-WORK.

To the skilled mechanical dentist, well versed in metal- and crown-work, bridge-work does not present extreme difficulty. The foundations or abutments—that is, the teeth or roots on which the bridge will rest—are first to be considered, due respect being paid to the mechanical principles controlling the leverage and the force of occlusion in mastication. The amount of strain that can be borne by the different teeth, individually and collectively, according to their position and condition of health, should be carefully calculated. As a rule, the force exerted upon the incisors in occlusion will be directed outward on the upper, and inward on the lower teeth, and its tendency when they support a bridge will be to gradually push them out of line in each direction. When the incisors are replaced by a bridge, the tendency of the force of occlusion is toward a similar result. On the bicuspids and molars the force is direct. The rules which govern the number and position of the teeth or roots required as foundations for bridges in practice, are as follows :

One central root will support two centrals, and if spurs or bars from the sides of the bridge rest upon or are anchored in the adjoining teeth, a lateral in addition.

Two central roots will support the four incisors, spurs or bars resting on or anchored in the cuspids to be used additionally, if the case requires them.

The cuspid roots, alone, or with the aid of a central root, will support the six anterior teeth.

One molar or bicuspid on one side, and a bicuspid or molar on the other, with one or two roots in an intermediate position, will support a bridge between them.

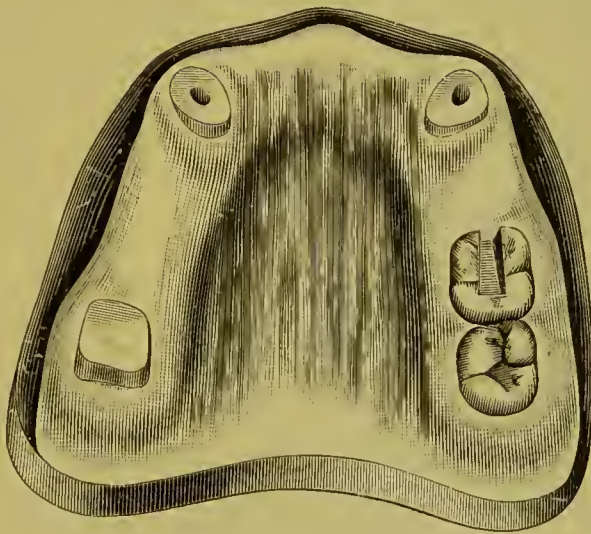
One right and one left molar, with the assistance of the two cuspids, will support a bridge comprising the arch between them.

A bridge on one side of the mouth can be supported by two

or three teeth or roots on that side. The cuspids always afford the most reliable support.

In general, the application of these principles will cover the subject of foundations, the operator being governed by the exact condition of individual cases. In a bridge of the six anterior teeth on the two cuspids, when the articulation of the antagonizing teeth is close and deep, the strain should be relieved by an additional attachment of the bridge to the teeth posterior to the cuspids.

FIG. 271.



The preparation of teeth or roots to support a bridge is the same as for ordinary crowns, except that the trimming of the sides and the drilling of the root-canals of the various anchorages should be, as far as possible, in parallel lines, so that the collars and posts of the crowns shall move readily to their places in the adjustment of the finished bridge. Teeth or roots which are to be supplied with porcelain-faced or all-gold cap-crowns are crowned by some one of the methods already described. The roots which are to carry porcelain-faced crowns can be so crowned or only capped, the posts being soldered and allowed to project a short distance beyond the caps.

The case represented in Fig. 271 will be used to illustrate the construction of a piece of bridge-work in all its details. The abutments, or supports, consist of the right second molar capped with an all-gold crown, constructed in sections by first forming

the collar and then soldering on the cap (see page 85), the two cuspid roots capped for collar crowns with porcelain fronts (see page 78), and the left first molar, which will afford anchorage to a bar on that side of the bridge (Fig. 272). A slot, dovetail in form, is usually cut well into the body, but not to an extent that will endanger the pulp of the last-named crown (Fig. 273). If the tooth is not decayed, it can be first opened up with a rubber and corundum disk. The shaping of the slot is best accomplished with fissure-burs. With the crowns and caps in position, an impression and articulation of the case are then

FIG. 272.

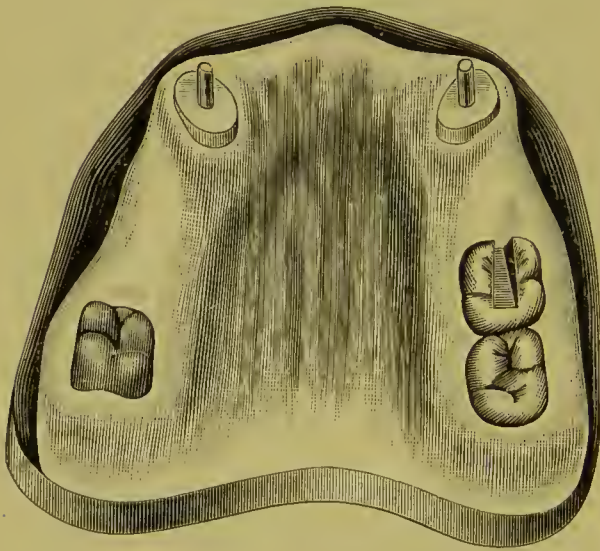



FIG. 273.

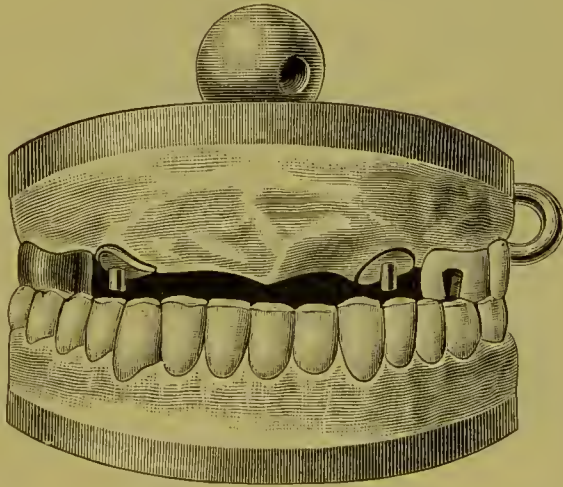


taken with plaster<sup>1</sup> slightly colored with carmine, to which is added a little sulfate of potassium, less than the proportion of salt generally used, which causes it to set quickly. The plaster is mixed moderately thick, and with the aid of a spoon or rolled in a mass in the fingers, which should be wet to prevent adhesion of the plaster, is placed around in the mouth on the crowns, caps, and parts to be included in the bridge, and the antagonizing teeth occluded tightly and so held until the plaster sets. The mouth is then opened and the plaster carefully removed, the pieces being adjusted together should it break. The

<sup>1</sup> Impression compound is used to some extent for this purpose instead of plaster, but in the author's opinion cannot be recommended as suitable.

crowns and caps (the latter held more firmly by the protruding ends of the pins) are generally removed in the impression; if not, they should be transferred from the mouth to it. The plaster is then varnished and oiled, and on the side containing the crowns a model is run, composed of equal parts of calcined marble-dust and plaster, to which a little sulfate of potassium is added. When the model has set, it is mounted with plaster on an articulator, and the other side of the colored plaster impression giving the articulation is run with plaster and the opposite section of the articulator adjusted. When the impression plaster is removed (an operation which is greatly facilitated by its having been colored with carmine), a correct model and articulation of the case will be found, with the crowns and caps in exact position as in the mouth (Fig. 274).

FIG. 274.



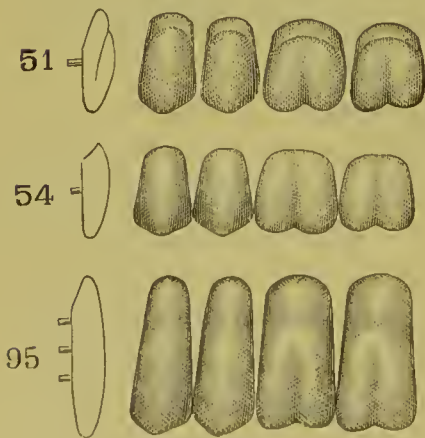
Another method is to first take the articulation in wax and then the impression in an impression-tray with plaster, and make a model and articulation from them in the usual manner.

Dr. Melotte's method is to place a piece of impression compound in the space between the crowns to be occupied by a bridge, and occlude the teeth. The compound is then chilled, removed, trimmed, and readjusted until it accurately fits the space, when it is placed in position and an impression is taken with plaster. When the impression is removed, iron pins to act as dowels are placed in the portions representing the natural

teeth, and then several pieces of fusible metal, by a few puffs of flame from the blow-pipe, are melted in around the pins. The rest of the impression is then run with plaster and marble-dust in the usual manner. This forms a plaster model on which the natural teeth are represented in metal. These metal teeth are to be removed before investing in soldering the bridge. An impression of the occluding teeth is taken in plaster, and the entire impression run with fusible metal. When the plaster impression is removed from the model of the bridge, the piece of impression compound between the crowns is to be left in position, and the metallic model of the occluding teeth fitted in position, guided by the indentations of the occluding teeth in the compound, and the case mounted on an articulator. The principal object of this method is to avoid fracture of forms of natural teeth, both in removal from impressions and in the construction of the bridge-work.

The pins protruding from the caps on the model are next cut off short. Teeth are selected,—ordinary cross-pin plate teeth for the incisors and cuspids, and partial teeth, representing the front section of the tooth and styled porcelain facings, which were specially designed for crown- and bridge-work, for the bicuspid and molars (Fig. 275). Cuspids are sometimes used

FIG. 275.



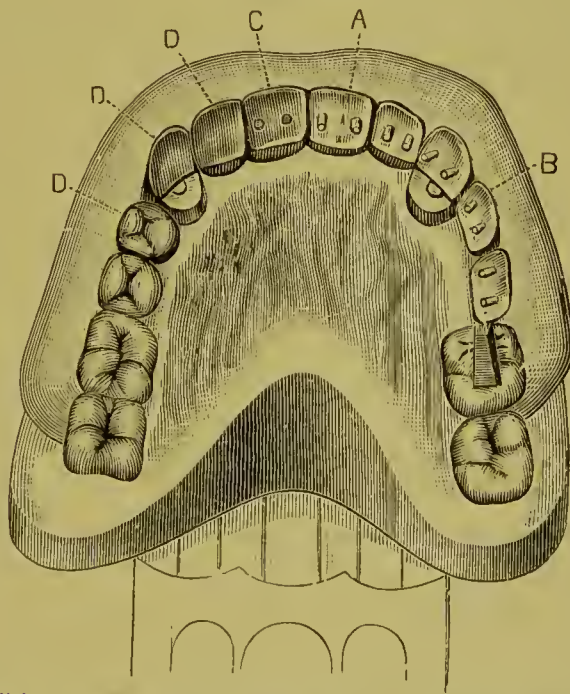
to form the fronts for bicuspid. The teeth are ground and fitted to the model and articulation, so that the labial upper edge of the teeth shall press lightly on the gum. Those which are intended to form the fronts of the caps on the cuspid roots should be adjusted in the ordinary manner for single crowns. To determine the proper positions of the teeth for producing the best appearance, they can be adjusted in the mouth

on wax, without the gold crowns or caps of the supports. The correct position of the teeth on the model having been obtained, investing material, composed of one part plaster to two of cal-



cined marble-dust, is placed on the outside of the model on the labial aspect of the teeth, merely sufficient in quantity to hold them in position, thus forming a matrix, or, the matrix can be formed of plaster and entirely removed before investing for soldering. The wax is then removed, exposing the palatal portion, and permitting the forms and position of the teeth to be studied (Fig. 276). The porcelain teeth or fronts, with the exception of fronts for the roots capped, are then removed from their investment, and the base ground from a line on the palatal side below the pins, straight to the labio-cervical edge (A and B, Fig. 276).

FIG. 276.



Shows "dummies" in various stages of construction. A, central incisor, and B, bicuspid, ready for metallic backing. C, is a central backed. D, D, D, porcelain fronts as they appear on insertion after the process of backing, capping, and soldering.

This is to form the self-cleansing spaces. The incisors are then backed, using either thin platinum or pure gold (C). The backings are allowed to extend just over the incisive edge as a protection to it, and, if preferred, down on the curve of the self-cleansing space. A more desirable result is secured if the backing extends only to the edge of the self-cleansing space, and the porcelain is polished, as its surface is superior in cleanliness to

that of gold. If the platinum backing used is so exceedingly thin as to be of the nature of foil, it is advisable to rivet a small piece of gold plate over it on the back of the tooth, to insure against melting the platinum off the porcelain with the gold, which is apt to occur if a pointed flame is directed against it. The cusps are backed in the manner described for collar crowns.

The bicuspid and molar porcelain fronts, their tips being ground off (A, Fig. 277), are lined in a similar manner. A cap of pure gold or gold lined with platinum, representing the grinding-surface of each tooth, is struck up as described and illustrated in the construction of gold crowns (see page 86), and the concave portion filled by melting in scraps of 20-carat gold plate or solder. The surface is then ground smooth (B), and closely fitted to the tip of the porcelain front to form the oc-

FIG. 277.

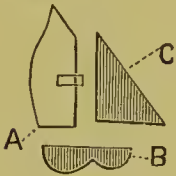

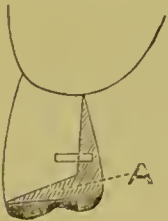


FIG. 278.



cluding surface in accordance with the articulation of the lower teeth, and the space filled in with wax. This metallic occluding surface is to protect the porcelain. Triangular pieces of very thin gold plate, platinum foil, or mica (C), cut and fitted to the sides, over which they should extend slightly, will retain the gold in position when melted, but are seldom necessary. The tooth is next invested, leaving the back open, presenting the form of a pocket (Fig. 278).<sup>1</sup>

FIG. 279.




Another method of constructing bicuspid and molar dummies is to fit the cap to the labial edge of the porcelain front, back the porcelain with thin platinum, extending the backing over and between the porcelain and cap, and then filling in the space with gold in soldering, as shown at A, in Fig. 279.

<sup>1</sup> See the Hollingsworth System for description of method of swedging grinding-surfaces of several crowns and dummies on one piece of plate.

The bar intended to be anchored in the slot cut in the molar on the left side is made of iridio-platinum wire, about No. 15 U. S. standard gauge, with the end shaped as shown in Fig. 280, and fastened with wax to the tooth and cap, and adjusted in the mouth to obtain accuracy of position before soldering.

FIG. 280.



The advisability of constructing bridge-work with what are termed self-cleansing spaces is not favorably accepted of late by many practitioners. Instead, the following method is adopted: Porcelain fronts thicker in the line from the labial to palatal side than those most commonly used are selected. The base or cervical section of the porcelain is ground and fitted to the alveolar ridge very accurately. The fronts are then waxed in position, and with a fine-pointed lead-pencil a line is drawn accurately around the base of each porcelain front on the model. The fronts are then removed, and with a suitable scraper the plaster under, and only under, the base of each is removed uniformly the thickness of cardboard. The porcelains are then fitted back in position with the bases in the indentations. The work is then proceeded with in the usual manner. When the bridge is finished and inserted, the base of each porcelain will uniformly indent the gum to the depth the plaster was removed, and the conformation will also exclude particles of food and present a much more agreeable shape to the tongue and a better appearance for the patient. The shape a bicuspid dummy would assume, constructed as described, is shown in Fig. 279.<sup>1</sup>

The teeth forming the bridge between the crowns are called "dummies." In the construction of dummies it is well to favor the occluding surface by shaping it a *trifle narrower* from *labial to palatal side* than the *corresponding natural tooth was*.

All the porcelain teeth or fronts can be invested at the same time, including the incisors and porcelain fronts to the cuspid crowns, as shown in Fig. 281. In the soldering, if the backing is done with platinum, and the occluding surface of the bicuspids and molars made with gold lined with platinum, 20-carat gold plate may be melted into the pockets formed by the cap

<sup>1</sup>The author, at present, in his own practice constructs much of his work in this manner.

and side pieces to fill out to the line at A, Fig. 282, and flowed over the backings of the incisors and cuspid fronts in sufficient

FIG. 281.



FIG. 282.



quantity to shape them as shown at B, Fig. 283. When the backing and occluding surfaces are made of gold plate, 20-carat solder and small pieces or filings of gold plate should be used instead. After the soldering and removal of the borax with acid, the metal of each tooth is then, when it is easily done, very carefully trimmed and shaped with corundum-wheels and points.

FIG. 283.

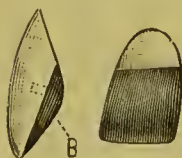
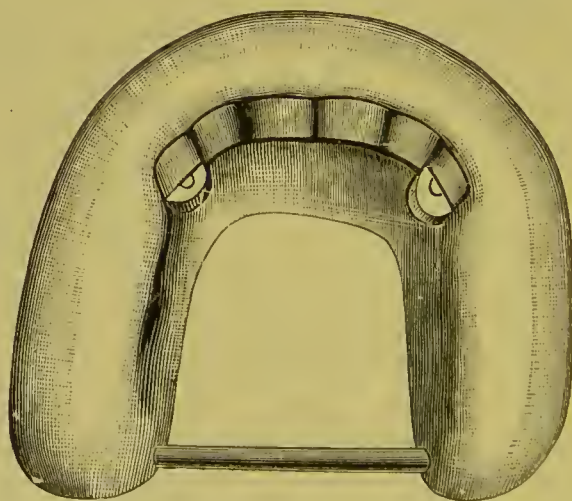


FIG. 284.



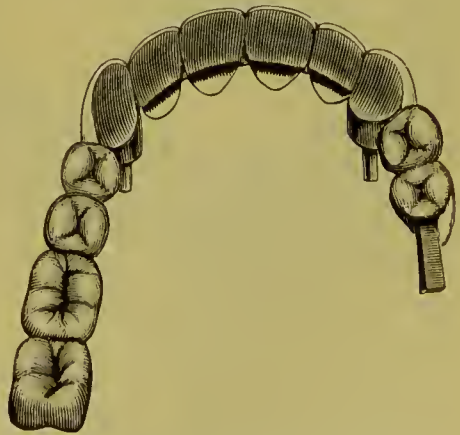The teeth are next placed in their relative positions on the model as shown at D, D, D, Fig. 276, and attached to one another with wax in exactly the relation and only where they are to be united with the gold solder. The model is then detached from the articulator, trimmed down as much as possible in size, and additional investing material, composed of two parts marble-

dust and one of plaster, or one part plaster, one marble-dust, and one common white sand, applied until all of the bridge is covered except the space along the backings and crowns where they are to be united in the soldering. To prevent fracture during the process of soldering, which might readily occur from contraction in so large an investment, an iron wire or a narrow horse-shoe shaped strip of sheet iron should be placed in the investment so as to encircle the teeth and crowns about one-fourth of an inch from their exterior surface (Fig. 284). In any spacings between the backings pieces of gold or platinum plate or wire, about one-eighth of an inch long, are placed lengthwise, and the joints well soldered. When the backings have been soldered with gold plate, 20-carat solder may be used. If the backings were done with 20-carat solder, an easy-flowing 18-carat solder should be used. The soldering is best done with a gas blow-pipe on a piece of charcoal with a concave depression (see chapter on Soldering). When the bridge is removed for finishing, the joints of the backings and crowns are finished with corundum-wheels and points and leather polishing-wheels on the engine, and the entire bridge finely polished with whiting carried by a brush-wheel on the lathe. Any little pits that may exist can be filled in with gold foil. The bridge is then ready for insertion (Fig. 285). If the constructive details have been properly performed as described, a finished piece of bridge-work is the result.

In constructing bridge-work many prefer, after the porcelain fronts are backed and the caps forming the occluding surfaces of the bicuspids and molars are properly adjusted on the model, to invest and do the entire sol-

dering at once. When this plan is followed, pieces of gold wire should be laid lengthwise in the slots under the gold caps of the porcelain fronts, and the parts filled in and all the sections of the bridge joined together in the soldering. By this method

FIG. 285.

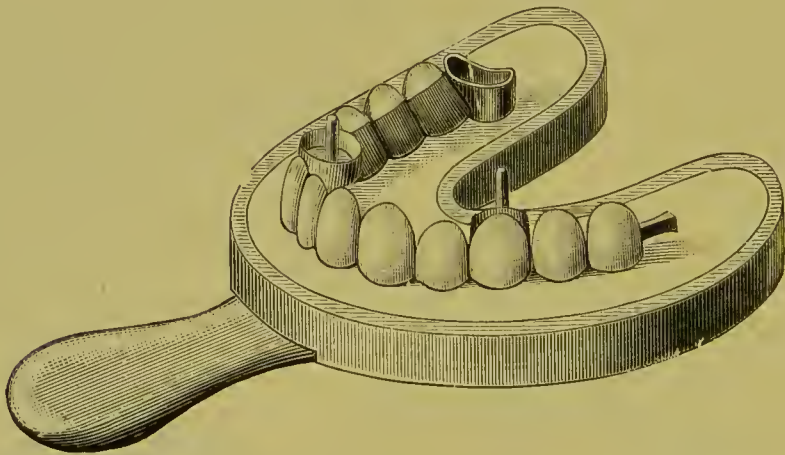


there is less liability of fracturing the porcelain fronts, but warping is more apt to occur, and the finishing of the bridge is not so easily or so perfectly done.

In large pieces of work warping may be avoided, whichever method of soldering is adopted, by first removing, in proper position, the "dummies," and soldering those of each span together. The spans are then replaced in the matrix and soldered to the abutments.

Another method much practiced is to construct the bridge in sections, adjust the sections in the mouth, and remove them in an impression-tray, using only sufficient investing material to cover the points of the teeth and crowns, as shown in Fig. 286.

FIG. 286.



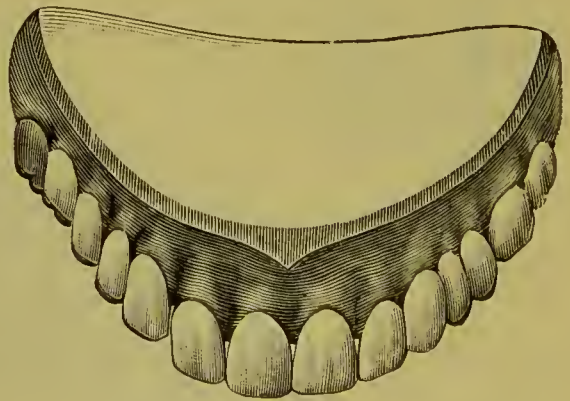
The bridge and the investing material are then removed from the impression-tray, and more investing material is added to complete the investment. The sections of the bridge to be united are then exposed and soldered together. To enable the investing material to be easily removed from the impression-tray, it is well to melt a film of wax on the interior surface, then cool and serrate the surface of the wax. The plaster will firmly adhere to the wax, but will loosen when the tray is heated. In the case just described, the right and left cuspids and molar sections could be made first, adjusted in position, the incisors then formed between them, and all soldered together; or, the front section, consisting of the cuspids and incisors, could be first made, and then the rear extensions to the molars added.

*Adjustment and Attachment.*—The bridge when finished is adjusted in the mouth, every point carefully examined, and any alterations required are then made. Should the edges of the collars of any of the crowns catch, so as to prevent their being placed in position, a small quantity of articulating paste (a thick mixture of rouge and oil) should be applied and the point found and trimmed off. If extensive warping has occurred in the soldering, the bridge must be sawed apart in one or two places, adjusted in the mouth, and removed in an impression-tray. Only sufficient investing material to cover the points of the teeth and crowns (Fig. 286) should be used as just described in construction of a bridge in sections, more investment material being added after removal, and the sections soldered together.

When the adjustment of the bridge is accomplished, it can at first be temporarily inserted for a day or two, if desired, which permits it to settle accurately in position. If the bridge is warmed and paraffin is placed in the caps before inserting, the secretions will be excluded and a septic odor prevented. Bur-nishing the collars will usually secure the bridge; if not, it can be cemented with a little gutta-percha placed in each cap, instead of the paraffin.

For its permanent attach-ment the pins or posts of the crowns are barbed, and the teeth and roots to which crowns have been fitted are then treated the same as single crowns, and the bridge cemented on with oxyphosphate ce-ment (see page 132). The end of the bar is anchored

FIG. 287.

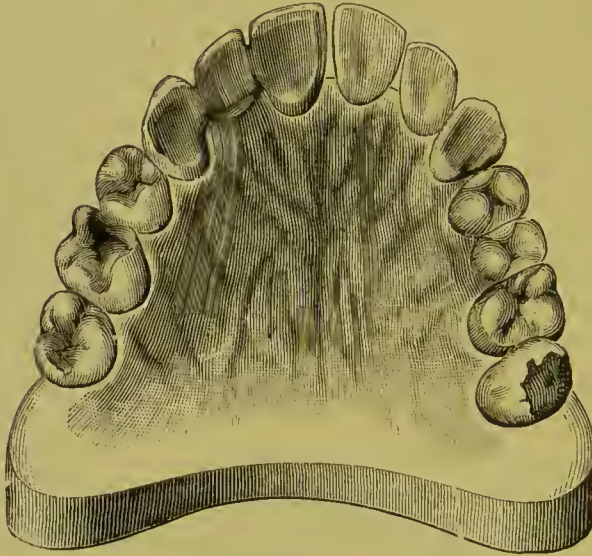


in the slot by either a gold or an amalgam filling (see chapter on Bar-Bridges). Fig. 287 represents the bridge in position.

*The Construction of Small Pieces of Bridge-work* is much simplified by the following method: Crowns are first made for the teeth or roots that form the abutments and temporarily placed in position. The teeth—"dummies"—which form the span, having been

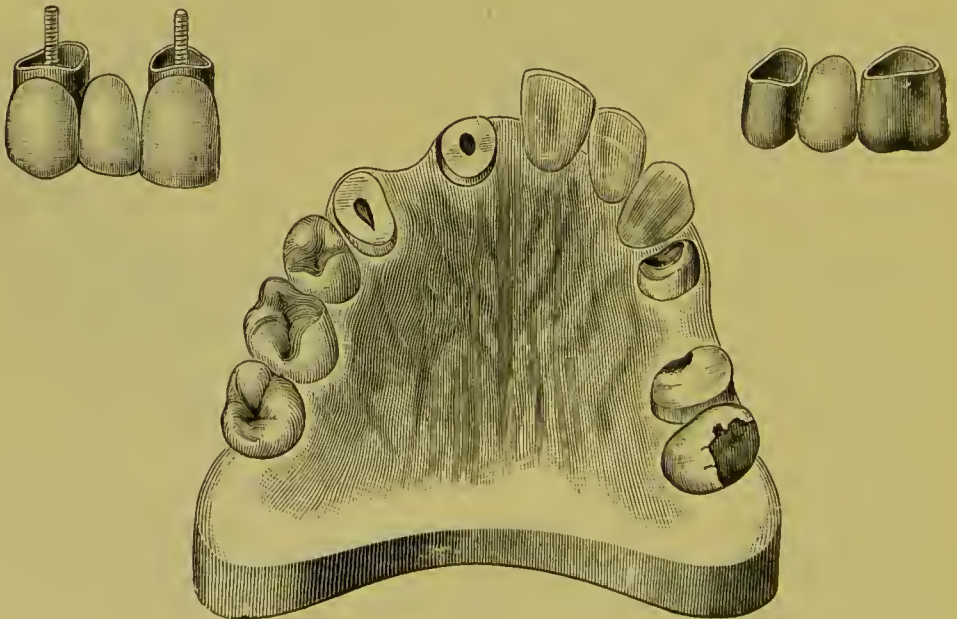
ground and backed, are adjusted and cemented with resin and wax in proper position between the crowns. The crowns and

FIG. 288.



dummies are then removed together, in an impression-tray filled with investing material. The inside of the tray should be previ-

FIG. 289.



ously oiled or coated with a film of wax with a serrated surface. The impression-tray is then heated, and the investment with the



crowns and dummies removed; more investing material is then mixed, and the exposed parts of the crowns and teeth covered. The investment, when set, is then cut away sufficiently to expose the parts that are to be filled in and united together in the process of soldering. Figs. 288, 289, represent cases of bridge-work constructed in this manner.

In a bridge of two teeth, often a preferable method is to properly adjust crown and dummy tooth cemented with wax in the mouth, carefully remove them in position, then invest and solder.

## CHAPTER II.

### SPECIAL PROCESSES AND APPLIANCES IN BRIDGE-WORK.

*Shoulders on Anterior Crowns or Artificial Teeth* are sometimes desirable, especially on the superior cuspids at the point of occlusion with the lower teeth. A shoulder can be made by melting gold plate into the form of a small ball or globule, then flattening it out and soldering it against the backing.

FIG. 290.

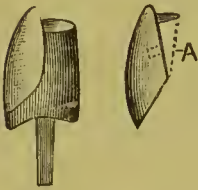
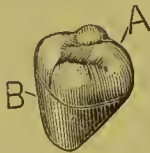

FIG. 291.



Another method is to attach with wax transversely across the backing in proper position a strip of gold plate as shown in Fig. 290, and then flow in gold to the line A, by specially investing or in the soldering of the bridge. The strip of gold should be extended a little beyond both sides of the backing or over the incisive edge of the porcelain to retain it in position in the investment.

*Solid Gold Crowns.*—In a close articulation, when the patient prefers strength to appearance, the bicuspid and molars may be made of solid gold. They are constructed by stamping up the cap (A, Fig. 291) representing the grinding-surface (see page 84), adjusting and cementing to this with wax a piece of plate cut and shaped to form the front and sides (B), the whole being then invested and filled in with gold solder, or, if pure gold and platinum has been used in the sections of the crown, with 18- or 20-carat plate.

Seamless contour crowns can be used for the purpose as follows: The proper crowns having been selected, the gold is trimmed and the crowns adjusted in position on the model. A matrix of plaster is then placed on the labial side, which permits exposure of the palatal portion, the crown removed, and cut

away to the form required. They are then removed, invested, and filled in with scraps of gold plate and solder.

A bar bridge can be made with these seamless crowns by passing an iridio-platinum wire through the crowns before filling in (Fig. 292).

*A Solid Gold Crown for a Pulpless Molar, supporting the end of a bar as shown in Fig. 293, is constructed as follows: The natural crown is ground down, banded, capped, and pivoted as in Fig. 294. The gold forming the top of the cap is made perfectly flat and left projecting a little at the sides. A contoured*

FIG. 292.

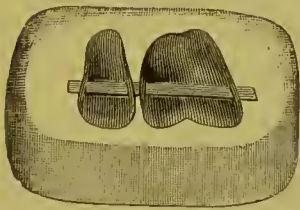
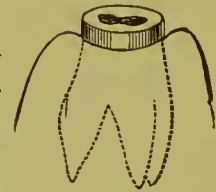


FIG. 293.

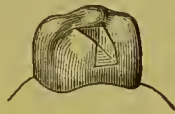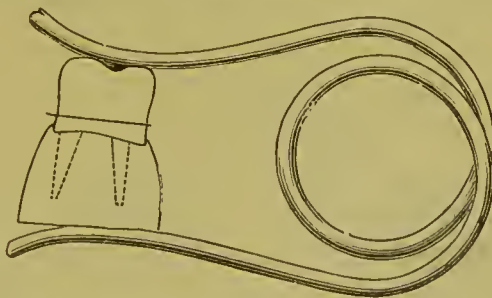


FIG. 294.



crown of pure gold, or gold lined with platinum as a precaution against melting, is shortened sufficiently to represent the absent coronal section of the tooth, and with a corundum-disk the orifice of the anchorage cavity is formed. A shell of thin platinum of the size and shape of the anchorage cavity is then inserted and cemented with wax on the inside of the crown. The crown is

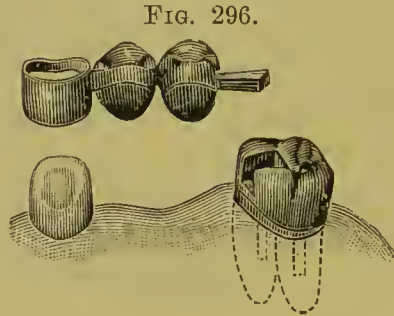
FIG. 295.



then invested and filled with 18-carat gold solder, which should be cut into small pieces, and be placed successively in the crown and melted by maintaining a uniform heat with the large flame of a blow-pipe. The base of the crown is next ground level and

accurately fitted to the cap and articulated to the antagonizing teeth. It is then clamped in position to the cap, the pivots of which are protected with investing material (Fig. 295), and soldered, making a perfect joint. This is an easy method of constructing an otherwise difficult form of crown.

Fig. 296 illustrates from the palatal side a bridge of two solid



gold bicuspid dummies supported by a bar-anchorage in a solid gold crown on the roots of a molar, and a shell crown on a cuspid.

*All-gold Hollow Dummies* are recommended in a large proportion of cases in preference to solid ones. They are formed as follows: Take a gold seamless contour crown of suitable size, with a thick grinding-surface, or one which has been reinforced

FIG. 297.

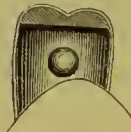

FIG. 298.



with solder or gold plate and with the flux removed, and cut away the gold forming the palatal section of the collar to the form termed self-eleansing; or shape the neck of the crown to the exact contour of the portion of the gum the dummy is to rest on, and scrape a little from the surface of the model to cause pressure and insure closeness of fit. Melt a small quantity of solder with flux to a ball form. Fit a piece of platinum plate, about No. 32 gauge, over the aperture, and place the ball of solder on the platinum within the gold cap (see Fig. 297). Hold cap and platinum in a Bunsen flame, and heat slowly

until the solder melts and appears under the edge of the cap ; then instantly remove from the frame, trim the platinum, and stone the edges. This gives a hermetically inclosed dummy tooth of gold, from the interior of which the air has been exhausted by the heat. The dummy can then be placed in its position on the bridge and soldered in the usual manner. Fig. 298 gives the palatal aspect of a bridge, the dummies of which were constructed in the manner described. The bicuspid dummy is given a self-cleansing form, and the molar is shaped to rest on the gum.

*Connecting Bands or Bars for Bridges*, which obviate the

FIG. 299.

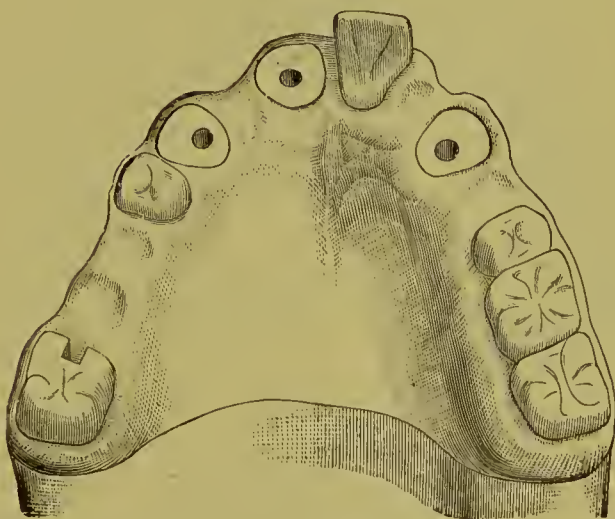


FIG. 300.

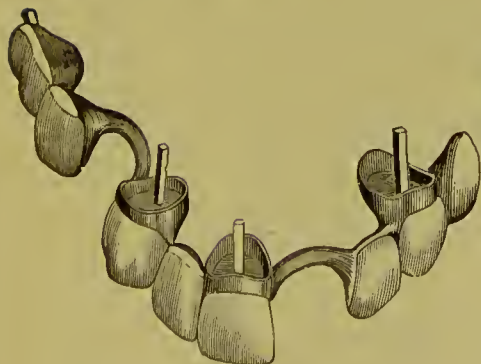
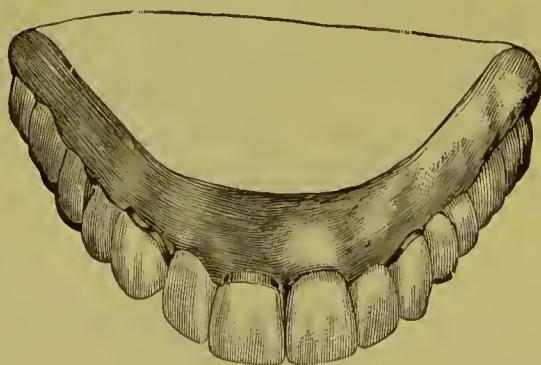


FIG. 301.



removal of crowns of intervening natural teeth between the sections of a projected bridge, are formed by passing a heavy

band of oval-shaped gold or iridio-platinum wire around the intervening teeth, close to but not touching them, and resting

FIG. 302.

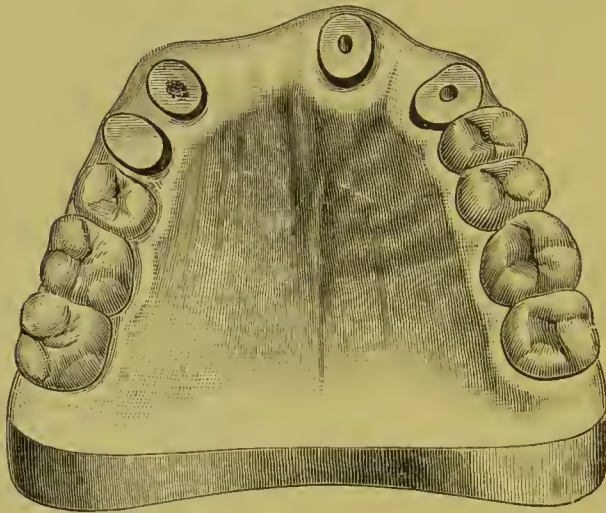
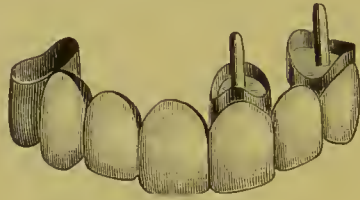
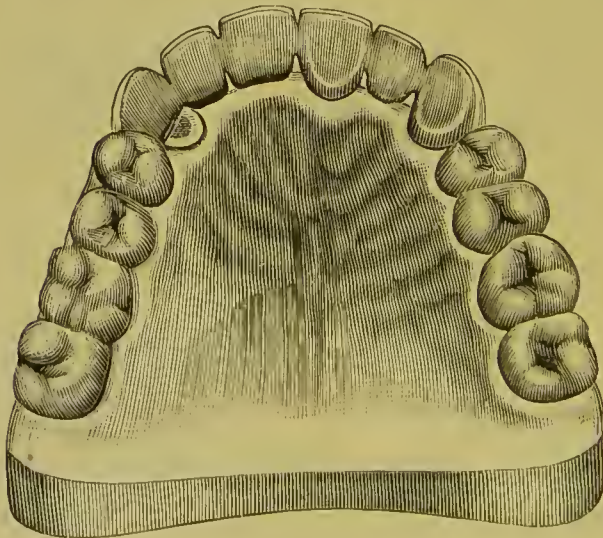


FIG. 303.

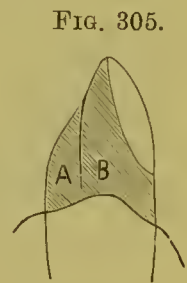
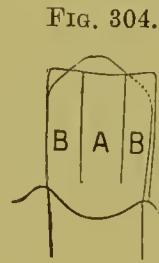

lightly on the gums. The application of this device was first illustrated by Dr. J. L. Williams, Figs. 299, 300, and 301.

*Intervening Roots* between the abutments of a projected bridge should not be extracted, but whenever practicable they should be treated, filled, and trimmed level with the gum, as they can usually be made to afford some support for the bridge, which may rest upon them. Figs. 302 and 303 represent a case in which the root of the cuspid on the right side has been so treated and utilized.

*Shell Anchorage or Crown.*—A shell crown or anchorage for a cuspid to support bridge-work is preferably used instead of a gold collar crown with porcelain front, where the insertion of such a form of crown involves the excision of a natural crown with a living pulp. A convenient method of construction is the following: Shape the natural crown parallel on the sides. Construct and adapt to the cervix,

and slightly under the gum-margin of the natural crown, a gold collar wide enough to extend a little below the incisive edge. Remove a portion of the gold from the incisive labial section, and slit the palatal surface on both sides of its



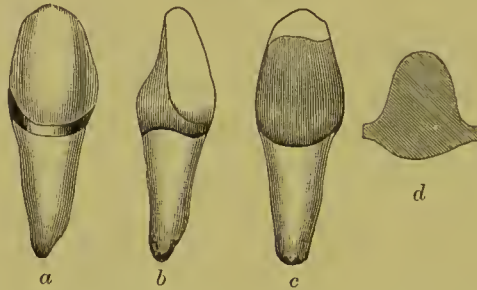
center, as represented in Figs. 304 and 305. The part at A is bent back, and the parts at B, B beveled, bent in on the crown, and burnished close to its surface. The piece A is next brought down in position, and adapted to the crown and over the parts B, B.

The collar has now assumed the form of a gold crown having an open face and seams. The seams are next united by placing, melting, and flowing solder into each of them, a little at a time, by holding the crown with tweezers in a Bunsen gas-flame. The seams will hold and retain solder sufficient to join and fill them without its flowing over the adjacent parts, unless there is an excess of heat or solder. When the soldering is completed, the crown is adjusted, a line showing the exact portion of the labial aspect to be exposed marked on the gold, the crown removed, its edges trimmed to the mark, and the soldered parts smoothed with corundum-wheels and points on the engine.

Another method for the construction of a shell crown prefer-

ably practiced by some is: Fit a gold collar around the natural crown, and remove the gold at the labial aspect as shown at *a*, Fig. 306. In the vacancy between the collar and tooth at the

FIG. 306.



palatal side, fit and burnish a piece of pure gold or thin platinum, which will cover the exposed surface of the tooth at that part, and fill in the space between the collar and piece of plate with wax cement. *d*, Fig. 306, shows the form generally of the piece of plate before it is fitted in the collar. Remove the collar, invest, and flow solder into the space between the piece of plate and collar, and remove the surplus gold of the collar extending above the crown; *b* and *c* show the finished shell crown.

*A Seamless Shell Anchorage* is formed as follows: From an impression of a natural crown taken in plaster, gutta-percha, or moldine, a die of fusible metal is formed, and from it a counter-die in lead is made. (See chapter on "Gold Seamless Cap Crown.") On the die a crown is stamped from a seamless cap of

FIG. 307.

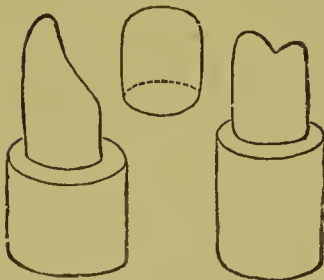
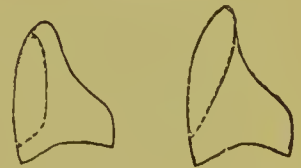

FIG. 308.



gold (Fig. 307). This crown is then fitted on the natural tooth, the labial aspect of which is exposed by the removal of the section of gold covering it in either of the forms shown in Fig. 308. A shell for a cuspid can be made from a gold collar as well as a cap. The shell formed in either manner is then filled with



investing material, and strengthened by flowing 20-carat solder over the surface.

For cuspids this process has decided advantages in the easy formation of a perfect-fitting crown or shell for bridge-work.

Fig. 309 shows the forms usually given shell crowns for bicuspid. When the gold is removed at the labio-cervical part, the crown should be additionally secured by a pin introduced and soldered at the point A.

FIG. 309.

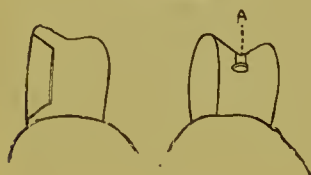

FIG. 310.

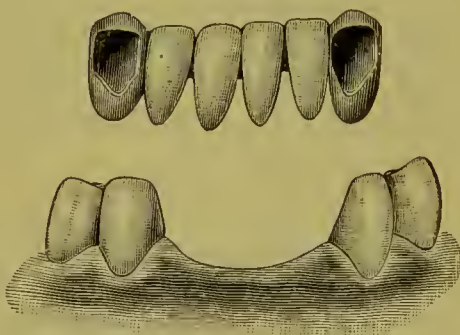


Fig. 310 illustrates a bridge in which the lower incisors are supported by shell crowns on the cuspids.

In cases where this form of crown is expected to *sustain a great strain*, the gold at the cervico-labial section should be reinforced by the addition of a strip soldered across it and extending around on the sides.

Fig. 311 represents the restoration of the inferior bicuspid and molar on the right side, by a bridge with a shell crown on the cuspid and an all-gold crown on the second molar as abutments.

FIG. 311.



To secure a better adhesion of the cement, the surface of the enamel should be cleaned with pulverized pumice wet with aromatic sulfuric acid. The tooth is then washed and dried perfectly. The cement should be thoroughly mixed to the consistence of a thick cream, the inside of the band covered with it, and then the surface of the tooth and the bridge brought to position.

## CHAPTER III.

### EXTENSION BRIDGES.

THIS term is applied to bridges which are chiefly supported by one abutment. In relation to the anterior teeth, it consists in attaching a dummy to an artificial crown, to replace an adjoining absent tooth. A bridge of this style replacing two or three of the posterior teeth is formed by using two of the teeth

FIG. 312.

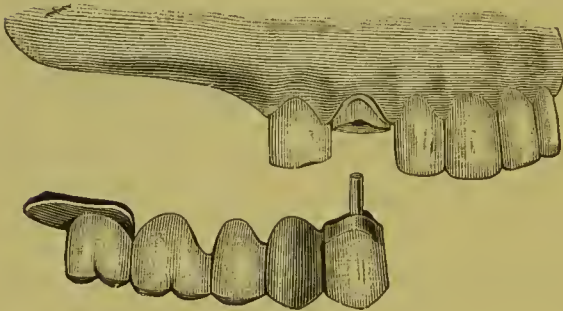


FIG. 314.

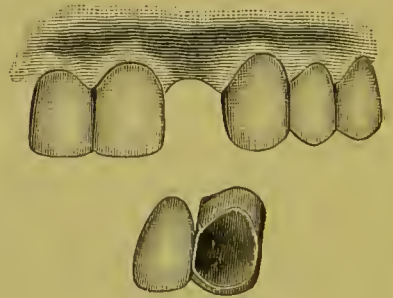


FIG. 313.

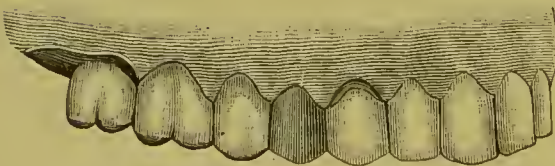
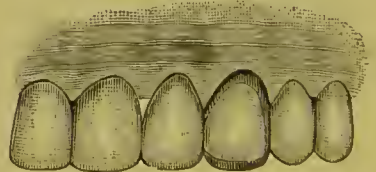


FIG. 315.



anterior to it as one abutment, with a saddle for the other. A saddle is an oval-shaped piece of gold, of the form of the gum and a little larger than the base of the tooth, placed under the posterior tooth of the bridge.

Figs. 312 and 313 represent an extension bridge. A crown on the euspid, an all-gold crown on the bicuspid, and a saddle, are the abutments. In constructing this bridge, the teeth forming the abutments were first crowned. The crowns were then adjusted in position, and an impression and articulation taken in

plaster, in which the crowns were removed. From this impression a model was made of plaster and marble-dust, and an articulation in plain plaster. With the crowns in position on the model as in the mouth, the bridge was then constructed by the methods described on page 152. The part of the model on which the saddle rested was marked, and enough of the surface of the plaster removed to cause the saddle to press tightly against the soft tissue when the bridge should be completed and inserted in the mouth.

A shell crown on a cuspid can be used as an abutment in this style of bridge, instead of excising the natural crown and mounting an artificial crown on the root for the purpose (Figs. 314, 315).

FIG. 316.

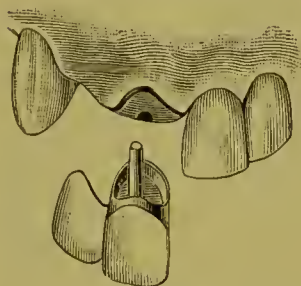


FIG. 317.

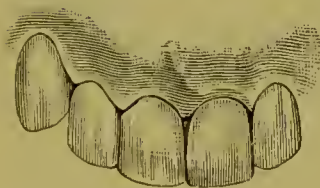

FIG. 318.

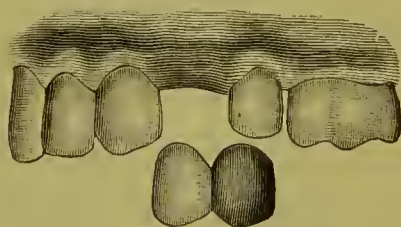



FIG. 319.

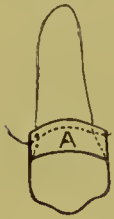


Figs. 316 and 317, 318 and 319, represent small extension bridges of frequent construction, the former to repair losses in the anterior portion of the mouth, the latter to replace posterior teeth.

Dr. T. Fillebrown's method of constructing a bicuspid or molar all-gold crown when the sides of the natural tooth have not, for some reason, been reduced in dimensions to that of the cervix, is to first form and fit a full-sized collar of thin pure gold, then adapt and solder over it a second and narrower collar of thin 22-carat gold plate, extending only from the occluding sur-

face about half the distance to the gum-margin. The cap for occluding surface is then added in the usual manner. When the finished crown is cemented in position, and while the cement is yet quite soft, a burnisher is passed around the neck of the crown, and the pure gold forming that part, as represented by A, Fig. 320, is brought close against the neck of the natural

FIG. 320.



tooth. This method of forming a gold crown may be advantageously practiced in these cases of bridge-work.

Fig. 321 shows a pin shell crown which can be made to support a porcelain front representing a cuspid or bicuspid. By forming two grooves, respectively in the mesial and distal sides of the natural tooth, for the reception of platinum pins passing through the grinding-surface of the cap and fastened with a little solder on the outside, great security of attachment is obtained with a partial cap, and without the least exposure of gold (see Fig. 322).

FIG. 321.

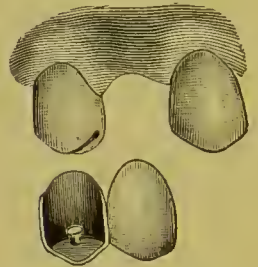
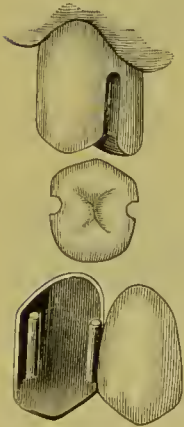


FIG. 322.



The same result can be obtained by first forming the grooves in the sides of the natural tooth, then making a collar of pure gold, about No. 33 gauge, and burnishing it well into the grooves, and then removing and flowing 20-carat gold plate over the outer surface of the collar. The grinding-surface is next added. The gold is then removed from the labial surface of the cap sufficiently to expose the natural tooth.

Figs. 323, 324, and 325 represent an extension bridge. The anterior abutment consists of the six front teeth, which were all crowned and joined together, the pulps being preserved in the incisors. A saddle on each side forms the posterior abutments. In cases similar to this, when the dummies are extended to such an extreme distance posterior to the abutments, if antagonizing molars are present, a mere saddle is insufficient to equalize the strain, especially as absorption goes on to some

extent under the saddle. An extension of not over two teeth on each side, resting on a plate or saddle extending from the cuspids back beyond the bridge teeth or dummies, is suggested instead.

FIG. 323.

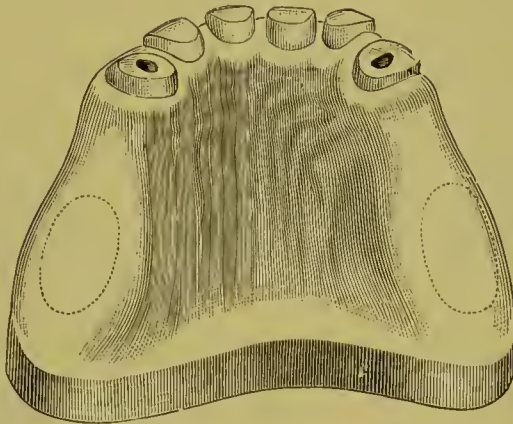


FIG. 324.

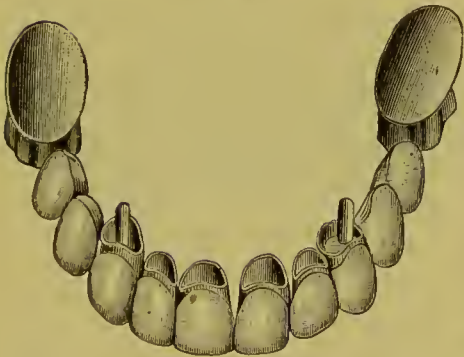
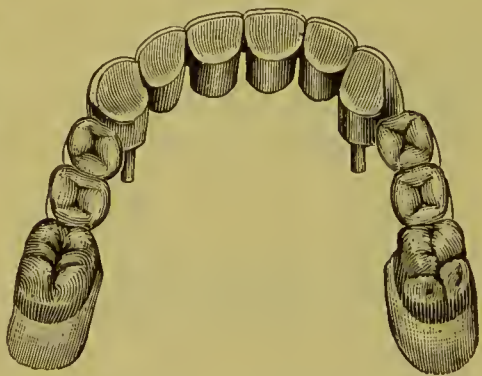


FIG. 325.



A *Spur Support* consists of a flange formed at the end of an extension bridge, affording support by resting on the palatal wall of either an incisor or a cuspid, or in the sulcus between the cusps of a bicuspid or molar, as shown in Fig. 326. Fig. 327 illustrates a case with a spur resting against a cuspid. In the case represented in Figs. 328 and 329 the spur rests in an indentation in an amalgam filling in the molar. This form is termed a cantilever bridge.

In extension bridge-work, the portion which constitutes the bridge exerts on the abutments, in resisting the force of occlusion, an action like that of a lever. The ratio of the force exerted is

proportioned to the length of the bridge or lever from the abutment or fulcrum. This principle must receive consideration in the employment of this form of bridge. A flange or spur support, if attainable, should as a rule be applied. More than one tooth should not be extended from an abutment without ample alveolar support besides. When two approximal crowns support an extension bridge tooth or dummy, the force is

FIG. 326.

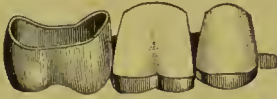

FIG. 327.

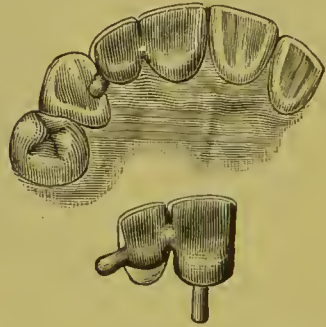


FIG. 328.

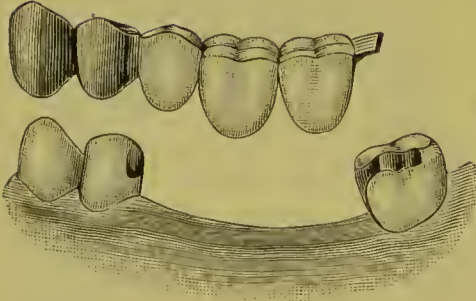
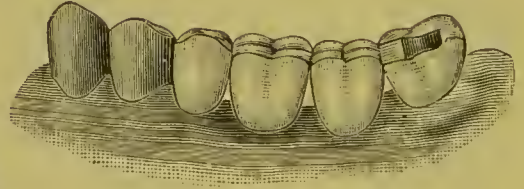


FIG. 329.



counterbalanced by the resistance of the farthest anchorage crown from the bridge, the pressure on which is in a direct line from the socket, the approximal crown acting as a fulcrum, the force on which is upward in the line of the root. The occluding surfaces of the bridge teeth should be made unusually narrow from labial to palatal side, to offer less occluding surface to those antagonizing.

## CHAPTER IV.

### BAR BRIDGES.

THIS style of bridge receives its name from the fact that the teeth or dummies forming it are supported by bars anchored in the natural teeth on either side by means of fillings. Failure to appreciate its limitations and faults of construction are responsible for disappointments in its use which have militated against its more common application.

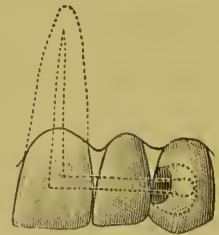
In the first place, its successful employment is confined to the insertion of one, or at most two teeth. An attempt to support more than two teeth by this method will almost certainly result in failure.

The most glaring fault of construction is insufficient anchorage for the bars. If the anchorage tooth is alive, the bar should extend in a suitably shaped cavity two-thirds or three-fourths the width of its palatal or occluding surface, according as it is an incisor or a cuspid, or a bicuspid or molar, and be thoroughly secured by the filling-material. Thus anchored, the bar is capable of supporting the bridge and resisting the leverage exerted on it in occlusion and mastication, which it cannot reliably do when simply anchored in a shallow filling inserted in the side of a tooth,—an incorrect method too often practiced.

In a pulpless tooth the bar should be bent and inserted into the root-canal, as shown in Fig. 330.

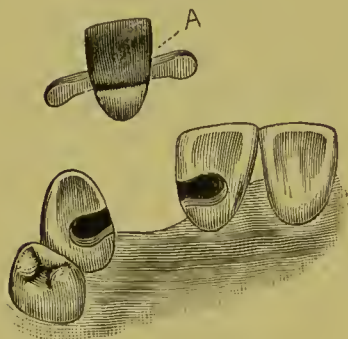
*In the incisors and cuspids* the anchorage cavities or slots are formed in the palatal portion of the teeth, extending from the approximal surface contiguous to the space to be bridged, two-thirds to three-fourths the width of the tooth, and usually about one-third of its length from the gingival margin (Fig. 331), direct access into the cavities being afforded through the palatal

FIG. 330.



wall. The slots or cavities having been formed, a model of the ease is made. Should the cavities to receive the bar be imperfectly represented on the model, they should be trimmed and shaped to correspond to those in the mouth. The exact alignment of the porcelain tooth in the mouth having been determined with the aid of wax, it should be adjusted on the model and secured in position by a matrix of plaster.

FIG. 331.



The base of the tooth should rest firmly on the gum, to accomplish which a small portion of the plaster should be removed from underneath the tooth on the model.

The bar is best constructed of iridio-platinum wire, 14 to 16 gauge. The wire can be extended in one piece entirely across the bridge from one anchorage to the other by bending, or by removing a portion of its bulk back of the porcelain tooth; or the bar can be cut and made in two sections, if the position of the anchorage cavities so suggests.

The ends of the bar should be flattened with a hammer, annealed, and shaped as shown at A, Fig. 331. The remainder of the section of the bar which is to rest in the cavity is best filed on the sides, so as to give it a somewhat triangular form, the broad base of which is toward the bottom of the cavity. This form favors the ready impaction of the filling-material which is to secure the bar.

The porcelain tooth having been backed, the bar, whether in one piece or two sections, is attached to it with wax cement, then removed from the model and soldered. Enough gold should be added to properly contour the tooth and securely fasten the bar.

*Anchoring the Bar.*—Gold and amalgam are the only filling-materials suited for securing bars. Amalgam is objectionable only when the position of the cavity renders it visible. Under such circumstances, however, the exposed portion can be cut away when set, and covered with gold. Fastening one end of



the bar temporarily with oxyphosphate, while the other is being secured, will sometimes facilitate the operation of anchoring with amalgam, but the best plan is to fasten the ends of the bar with gold-foil pellets and then fill flush the remainder of the cavities with amalgam. The amount of gold used need only be sufficient to secure the bridge against the slightest motion until the amalgam sets.

When the anchorage tooth is pulpless, the end of the bar which extends into the canal should be cemented first. Frequently, when bicuspid and molars containing large cavities of decay are used for anchorages, it is advantageous to first insert the anchorage fillings, and then drill out sufficiently to admit the bar, which can then be secured with additional filling-material.

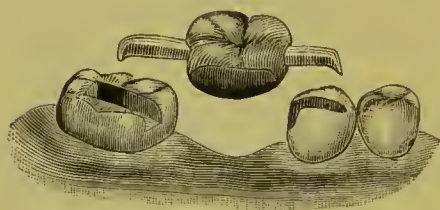
When gold is the filling-material used, the rubber-dam, which must be thin, is first adjusted on the natural teeth, and the bridge then pressed to position over it. In anchoring with gold, the best way is to first fill such portions of the cavities as are inaccessible when the bars are in position, how far to proceed being determined by occasionally trying in the piece as the gold is inserted. The bridge is then pressed to place, and held firmly while the ends of the bars are secured by condensing around them a few pellets of foil, after which the gold is carefully impacted around the bar, the filling of one of the cavities being carried to completion before going on with the other.

In the preparation of the cavities, their sides should be given an undercut form with strong edges. When only sufficient tooth-structure has been removed at the approximal portion to just admit the bar, it is a doubtful expedient to attempt to fill the narrow seam around it with gold. In such cases, this portion of the filling is better made with amalgam, which is inserted at the sides and along the floor of the cavity before the bridge is fixed in position. Then, beginning at the interior end of the cavity, gold can be inserted and gradually condensed toward the amalgam, with which it will unite when brought in contact. Any surplus of amalgam can be removed subsequently when it has set. Amalgam placed around the bar as

here described is seldom visible from the labial side, and the quantity required is insufficient to materially discolor the tooth.

*In Bicuspid and Molar Bar Bridges* the bar should be carried well across the occluding surface, and the end bent and imbedded in the line of the sulcus toward the side opposite to that from which the bar enters, as shown in Fig. 332. Forming the end of the bar in this way affords the greatest security, when it is properly anchored with the filling-material, by preventing any rotatory movement, or any loosening of the bar by force applied in a forward direction.

FIG. 332.

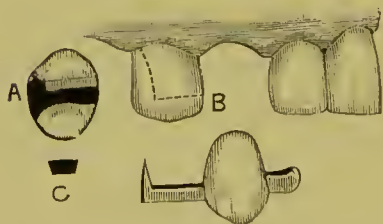


The principles involved and the method described for shaping and securing the ends of bars apply equally well to cases where one end of the bridge is supported by a bar and the other by an artificial crown, as has been previously illustrated.

*An Extension Bar Bridge.*—In this form of bridge the artificial (dummy) tooth is supported by a bar anchored in a natural tooth at one end only. At the other end of the bridge the bar is either made in the form of a spur to rest against the adjoining natural tooth, or it is not extended beyond the dummy.

In the case represented in Fig. 333, an upper cuspid, the patient, a lady, declined to have the bicuspid capped or crowned in any way for the purpose of supporting the cuspid.

FIG. 333.



The posterior approximal side of the bicuspid at the time contained a large filling. This filling was removed, and a cavity of proper shape to receive a bar was extended forward from it between the cusps to the anterior side. A suitable bar for the cavity was formed to support the cuspid in the manner illustrated at A and B. The angular form (C) given the bar rendered it, when anchored with the filling-material, very secure, and fully capable of supporting the cuspid.

The filling-material, which was gold, occupied most of the space of the occluding surface between the cusps. The oc-

cluding tooth was trimmed off proportionately. A spur extended from the anterior side of the artificial tooth resting on the lateral incisor. The occlusion was favorable to the insertion of the bridge tooth in the form presented, and it has been comfortably and satisfactorily worn, now at the date of writing eight years. When recently examined it showed no change, except that the force of occlusion on the cuspid had slightly bent the bar and caused the tooth to assume a deeper position in the jaw than at the time it was inserted, though this was only to the extent of the absorption of gum-tissue under the bridge. In some instances the bar of a bridge of this kind can be extended across the occluding surfaces of two teeth, and additional support thus obtained.

*Cast Fillings*, as described on page 127, can be used in some instances to support the end of a bar. In such a case, a short piece of wire to form the bar is inserted in position in the wax in the matrix of platinum before it is removed from the cavity, and soldered in it. The attachment of the bridge is then made to the bar.

The practical application of bar bridge-work is limited. It frequently affords advantages for artificial restoration, in many cases where a single tooth has been lost, not presented by other methods. Its practical success depends chiefly upon the character of its supports and the skillfulness with which it is anchored.

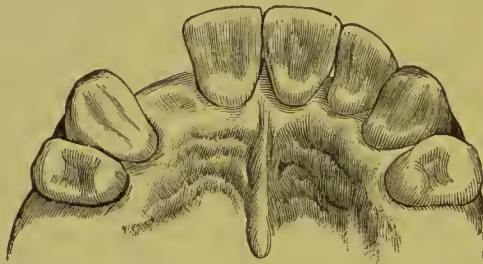## CHAPTER V.

### PARTIAL CAP AND PIN BRIDGE.

THIS style of bridge is used only in ease of loss of a single front tooth.

Fig. 334 represents a typical ease, in which a lateral incisor (crown and root) had been lost, the cuspid and central incisor, fully vitalized, and without approximal carious cavities, remaining in position.

FIG. 334.



*To Make a Pin and Plate Bridge.*<sup>1</sup>—1. Take in plaster an accurate impression. From this obtain a plaster model of the parts.

2. Make from pure gold, rolled to the thinness of No. 26, standard gauge, base-plates, to be carefully adjusted to the palato-approximal surfaces of the cuspid and incisor. These can be made by swaging on dies and counter-dies obtained from the model, but more conveniently by bending the gold into shape upon the plaster model and pressing and burnishing it into perfect adaptation upon the natural teeth.

3. Select a plain plate porcelain tooth of suitable length that will fit easily into the interspace; back with gold or platinum; adjust in position to the gold base-plates on the model, and attach with wax cement. Remove and fit in the mouth,

---

<sup>1</sup>Dr. W. F. Litch, *Dental Cosmos*, vol. xxviii, No. 3.

and chill with ice-water. Next remove from the mouth, invest, and solder tooth and plates together, as shown in Fig. 338.

4. For the purpose of attaching the denture as thus far constructed, drill a small cylindrical opening through the palatal

FIG. 335.

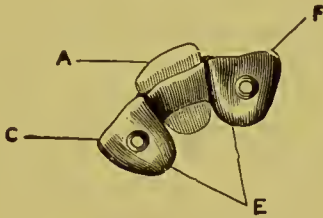
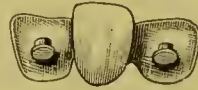

FIG. 336.



surface of the enamel of the cuspid and incisor respectively. These openings should usually be placed about as indicated in

FIG. 337.

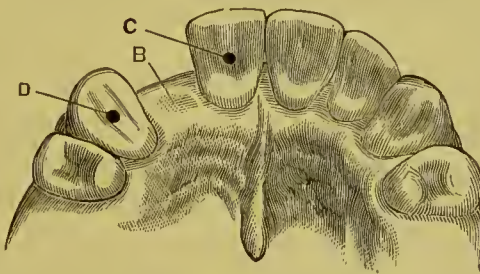
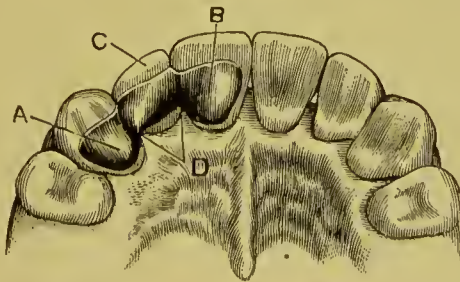


Fig. 337, at C, D. Sometimes, owing to a close occlusion or to the contour of the tooth, it is desirable that they should be located

FIG. 338.



a trifle nearer the neck of the tooth. Each opening should be well undercut, but must not encroach upon the dentine far enough to endanger the pulp. In size the openings need not be larger than will admit a platinum pin-head, in diameter cor-

responding to No. 13, standard gauge, with a shank of No. 18, standard gauge. Into each of these openings must be fitted a platinum pin of the size indicated. The head of each pin must be made thin and perfectly flat both upon its upper and under surfaces.

5. In each of the base-plates make an opening corresponding in position to those in the natural teeth. Pass through these openings and cement in them the free ends of the platinum pins. While the cement is yet plastic, place the denture in position in the mouth, carefully pressing the pin-heads into the openings made for them, and burnishing the base-plates into perfect contact with the palatal surfaces of the teeth; chill the cement, remove and invest. Next attach the pins, and also flow solder over the surface of the base-plates to stiffen them.

Fig. 335 represents the appliance without the pin. A is the porcelain tooth and backing; E, the base-plates; C and F, the openings for the pins.

Fig. 336 represents the appliance completed with the pins in position.

Fig. 337 represents the natural teeth and interspace B, with openings for retaining-pins, C, D.

Fig. 338, already described, represents the appearance presented when the bridge is cemented in position.

The bridge is attached by cementing in position with oxy-phosphate.

When the supporting teeth have vital pulps and very sensitive dentine, the difficulty of securing reliable anchorage for each of the plates seriously militates against this method. Loosening of the bridge, especially in "close bites," is apt to occur at the most inopportune moment, demanding its immediate re-cementation. Practical experience by the author in the use of this form of attachment shows that two pins in one, if not in each, of the plates are necessary. The exception is a pulpless tooth, which admits of considerable lengthening of a single pin.

## CHAPTER VI.

### REMOVABLE AND REPLACEABLE PORCELAIN FRONTS.

IN those forms of crown- and bridge-work in which porcelain fronts are used there is some liability of fracturing the fronts, either in the soldering processes connected with the construction, or subsequently, after the insertion of the piece in the mouth, by the patient in mastication. The replacing of a porcelain front after the work has been permanently fixed in position is frequently attended with great difficulty, and the result is often unsatisfactory or doubtful regarding its permanency. The desire to obviate such difficulties has prompted the introduction of various methods of construction in which the porcelain fronts are removed from their positions previous to the soldering processes, and afterward adjusted so as to be easily replaceable by means of duplicates in case of fracture when the work is being worn in the mouth. These methods applied to a bar bridge afford access to the cavities of anchorage.

A modification of Dr. I. F. Wardwell's method, which is simple in construction and application in comparison with most forms in use, is as follows: A thick, narrow piece of 18-carat gold plate, at least No. 18 standard gauge, is soldered to the tooth, and its two sides undercut with a very thin separating file (Figs. 339, 340). A very thin piece of platinum, covering the entire back of the tooth, is burnished against it, well into the undercut sides, the platinum being annealed several times during the operation. The platinum is held in a flame while a small quantity of pure gold is flowed over the outer surface and then refitted to the back of the tooth, to which it is again burnished. This operation is repeated until the platinum and gold form a moderately light backing which fits perfectly. The platinum surface is then covered with investing material, and on the other side 18- or 20-carat gold plate flowed until a suitable thickness is

obtained. When trimmed into proper shape and attached to the bar, this forms a substantial backing or socket (Fig. 341), in which, when the bar is anchored, the porcelain tooth can be fastened with a little oxyphosphate cement or gutta-percha (Fig. 342<sup>1</sup>).

FIG. 339.

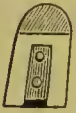

FIG. 340.

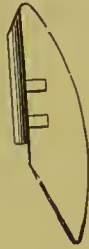

FIG. 341.

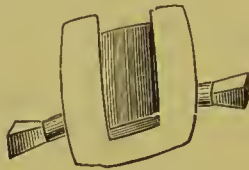
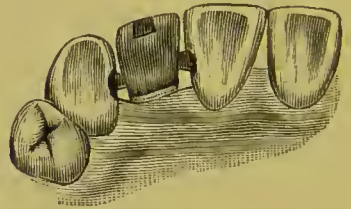


FIG. 342.



Any ordinary porcelain front to a bicuspid or molar dummy can be made on the removable or replaceable plan, by backing the porcelain in the usual manner with gold or platinum plate without bending the pins, adjusting the gold cap in position, attaching the cap, and backing with wax cement, then, removing the porcelain front (Fig. 343), investing and soldering the cap and backing together. The backing must be made thick with solder, the holes in it deepened with a drill, and the pins of the porcelain front serrated and fitted therein. After the final soldering, the porcelain fronts are cemented in position with oxyphosphate.

FIG. 343.

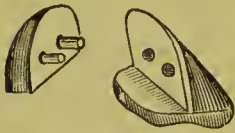



FIG. 344.



Dr. C. L. Alexander's method is to use teeth having long pins, as in Fig. 344. The facings are fitted in proper position and cemented with hard wax. The wax around the pins is then heated with the points of a hot instrument, and the facings are removed without disturbing the backings. Half-inch pieces of fine iron binding-wire are bent to form staples, their ends heated and pushed through the pin-holes from the facing side in the backings, leaving a loop on that side and projecting ends on the

<sup>1</sup>Dr. F. T. Van Woert has introduced pliers with combination points which much simplify the construction of a socket of this form and the replacement of the porcelain front in case of fracture by the patient.

Porcelain fronts or dummies of the character described can now be purchased ready-made under the name of "Mason's Detachable Tooth."

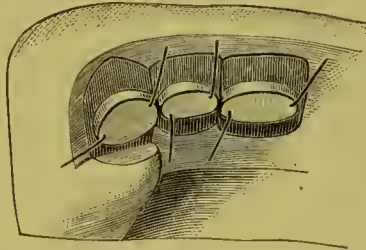


other, which are twisted. The wax is removed from the backings and little ferrules of pure gold placed around the pin-holes (Fig. 345). Hard wax is next applied on the outside of the ferrules, the ends of the iron wire brought down to hold them in position, and the inside of the ferrules filled with investing material. Fig. 346 shows an invested case ready for the solder-

FIG. 345.

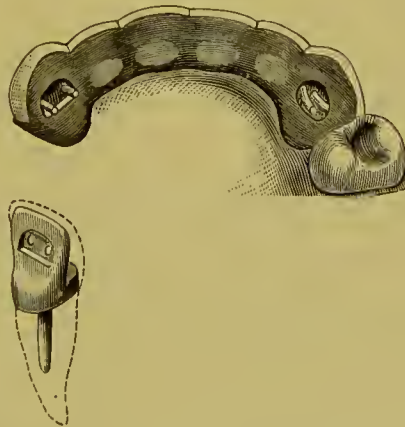


FIG. 346.



ing process, which will unite the ferrules to the backings, and at the same time join the backings to each other and properly shape them. When soldered and trimmed, the facings are put in place with a very thin oxyphosphate cement between fronts and backings, the pin ends are bent down on the backing within

FIG. 347.



the ferrules, and the ferrules filled with amalgam packed moderately dry. The bridge is then put aside until the amalgam has set, when it is ready for insertion. Fig. 347 shows a central crown ready to receive the porcelain front, and a piece of bridge-work with the cuspid ferrule chambers as yet unfilled.

Dr. Low has invented for use in crown- or bridge-work a

ready-made metallic socket or shell, into which fits a corresponding porcelain front, which can be replaced in case of fracture.

Fig. 348 shows a socket shell; Fig. 349 the same with por-

FIG. 348.



FIG. 349.



FIG. 350.



FIG. 351.




FIG. 352.



celain in position; Figs. 350 and 351 a porcelain front, a socket for incisors and cuspids, and Fig. 352 the same with porcelain in position.

## CHAPTER VII.

### GENERAL APPLICATION OF CROWN- AND BRIDGE-WORK.

THE construction and general application of bridge-work, as explained in the foregoing chapters, are additionally explained and illustrated in applying them to the following typical cases:

*Central or Lateral Incisors, Cuspids or Bicuspids.*—Figs. 353, 354 illustrate a method of replacing a superior central or lateral.

FIG. 353.

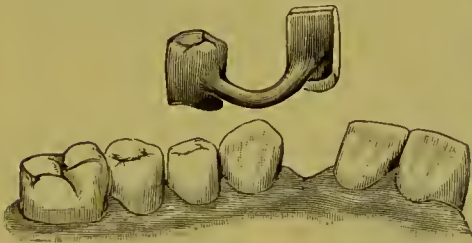
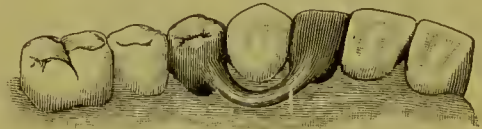

FIG. 354.



The central or lateral is formed with a base of gold or platinum resting closely on the gum. A gold cap-crown on the first bicuspid is used to support it in position by means of an iridio-platinum bar. A small spur placed on the mesial side of the bridge-tooth is suggested in such cases.

Figs. 355, 356 show a case in which two centrals are supported in position by bars extending from gold crowns on bicuspids. The method of construction in these cases is: First cap the bicuspids; then fit and back the bridge-tooth or teeth and fasten in position in the mouth with hard wax. Next take a plaster impression. Remove and make plaster and marble-dust model, showing teeth and crowns in position. Mark and slightly groove the line of the bar on the model. Fit the bar in position in groove, and wax ends to cap and tooth. Fasten the center of the bar and cover the teeth and caps with investing-material, and solder bar or bars and cap or caps together.

Fig. 357 shows the form of bridge-work suitable for replacement of one or two inferior incisors. The labial section of the shell crowns which form the support for the artificial tooth should be removed only sufficient to avoid any considerable exposure of the gold in the movement of the lips.

FIG. 355.

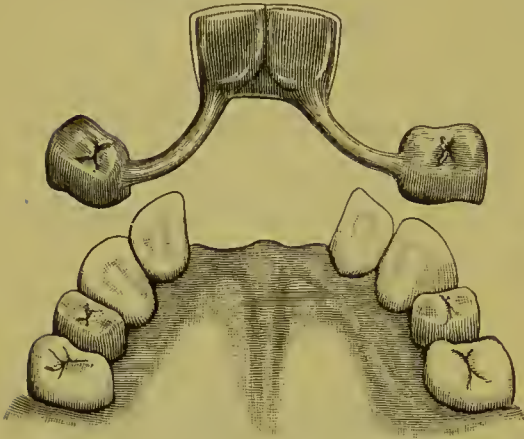
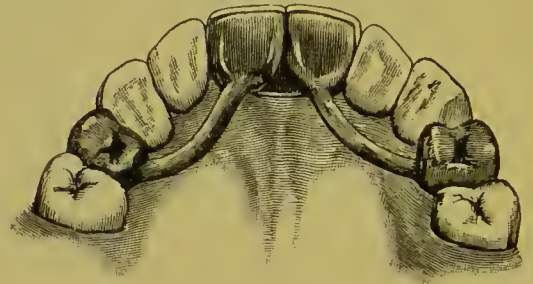


FIG. 356.



Other cases illustrating methods for single centrals and laterals, cuspids and bicuspsids, are shown in Figs. 314, 316, 318, 321, 327, 331, 333, and 342.

Fig. 358 explains and illustrates a method of restoring an incisor and supporting the adjoining loosened teeth with successive cemented connecting collars of gold in cases of pyorrhea

FIG. 357.

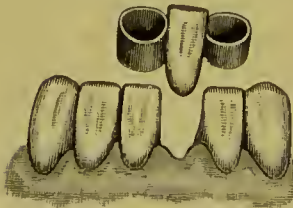


FIG. 358.

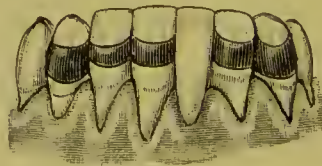
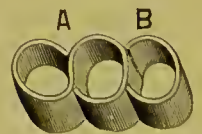


FIG. 359.



alveolaris. When the natural teeth are all present, but very loose from this disease, connecting the teeth together with a succession of bands steadies each tooth in its socket and consequently permits of much more effectual treatment. For the application of such collars the teeth generally need to be slightly separated. The collars may be formed of a strip of

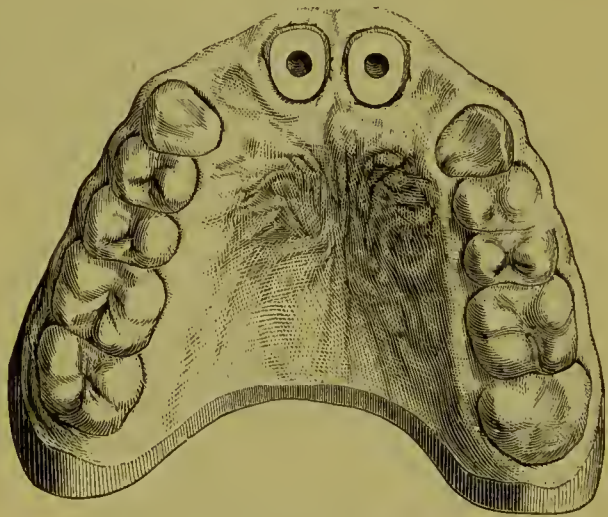
pure gold plate, about No. 32 to 33 gauge, by bending and fitting the strips to the forms of any two teeth in the shape shown in Fig. 359, A. This leaves but one thickness of the plate between the teeth. An additional loop can then be added as shown at B, for one adjoining tooth. All the soldering can be done quickly with the Bunsen burner without investing.

*Centrals, Laterals, or Cuspids Combined.*—Two laterals supported by two central crowns are illustrated in Figs. 360, 361. Spurs might be additionally formed on the laterals to rest on the cuspids. When approximal crowns, as in this case,

FIG. 360.



FIG. 361.



are united to support bridge-work, a free space should be preserved at the neck between their respective collars to admit the gum septa.

Figs. 362, 363, 364, and 365 show a bridge of the incisors supported by two collar crowns on the cuspid roots. Shell crowns can also be used for this purpose, according to the preference of the operator. Figs. 366, 367, and 368 illustrate a case with shell crowns for supports. In its construction the best method of procedure is to form and fit the caps or crowns to the cuspids, remove them in plaster impression and bite, make models, and then bridge between the shell caps or crowns with the incisors. The edges of the bands of these shell caps should be beveled and burnished close to the teeth. If properly done they will

FIG. 362.

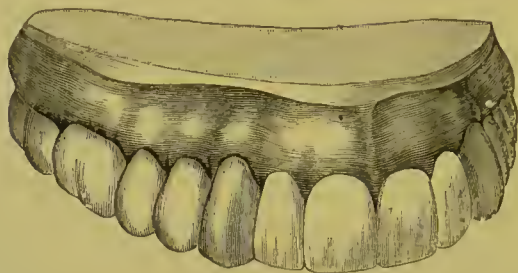

FIG. 363.

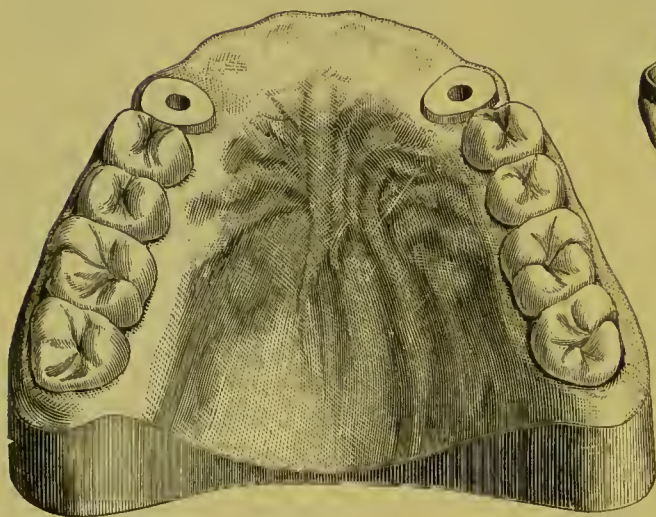
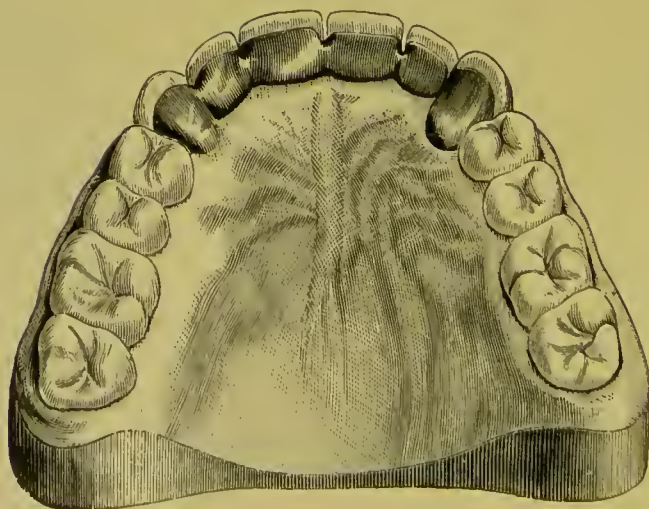


FIG. 364.



FIG. 365.



resemble gold fillings. When these shell caps become loose from disintegration of the cement they should be immediately reset. It would be well if cases of this style could be removed once a year and re-cemented. Other cases of this character are illustrated in Figs. 289 and 302.

FIG. 366.

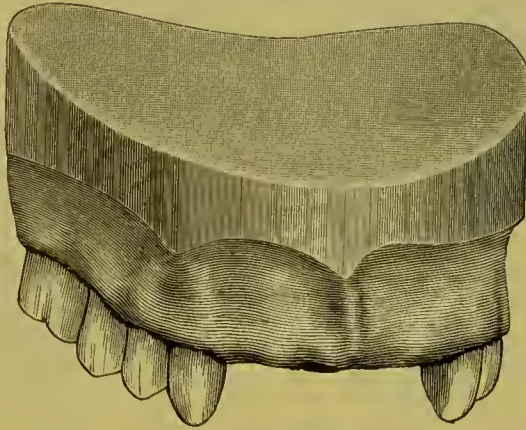
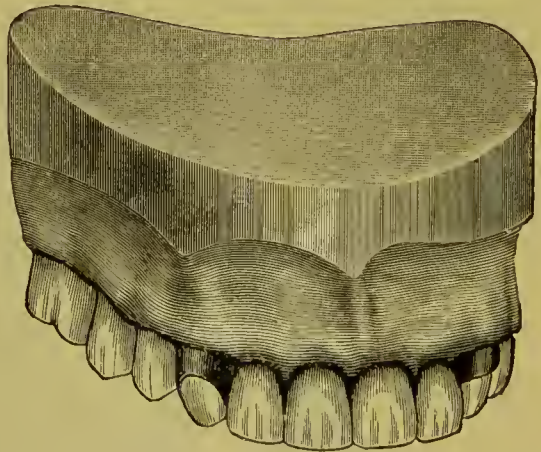


FIG. 367.



FIG. 368.

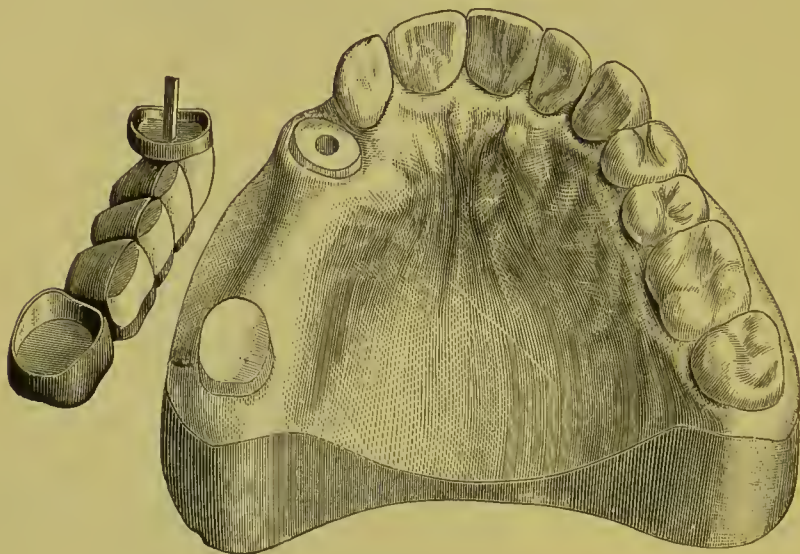


*Cuspid, Bicuspids, and Molars Combined.*—Figs. 369 and 370 show bridge-work supported by cuspid and molar cap or crown. If the cuspid contains a living pulp the natural crown should be preserved, and an all-gold or shell crown should be used in preference to the form illustrated. Figs. 311 and 312 illustrate other cases.

*Bicuspids and Molars Combined.*—Fig. 371 represents a bridge

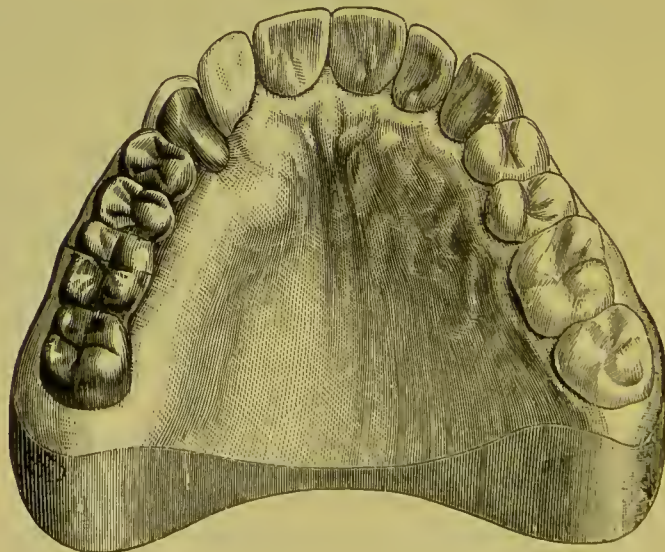on the lower jaw from the first bicuspid to the second molar. The inclination of the teeth toward each other suggests the construc-

FIG. 369.



tion of the bridge in the form illustrated. The molar is covered entirely with a cap, the bicuspid only on the occluding surface,

FIG. 370.

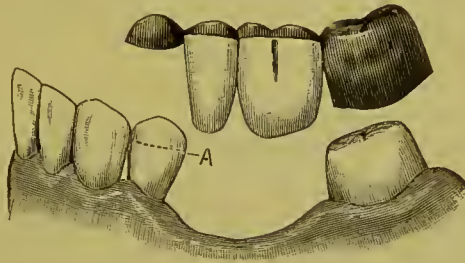


with the gold extending only half down the coronal section of the natural crown (A). A pin inserted in the cap fitting a hole drilled in the sulcus of the occluding surface of the bicuspid



will secure this cap in position. This method is very suitable to a case where the crown of the bicuspid is long and the root slightly exposed. Molars under similar circumstances can be capped for bridge-work in like manner.

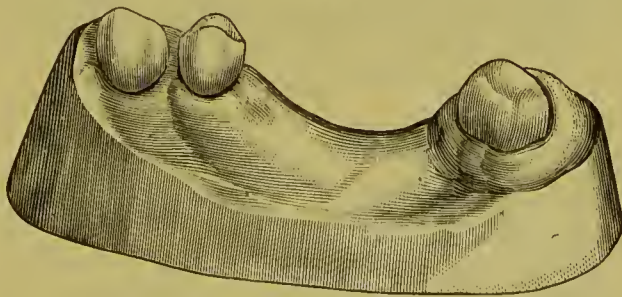
FIG. 371.



“ Fig. 372 represents a practical case in which the upper third molar and the first bicuspid (both without antagonizing teeth) were utilized for the attachment of a bridge made of gold crowns with porcelain facings, to supply the loss of the intervening teeth.<sup>1</sup>

“ Fig. 373 represents the case as prepared for the bridge. A, the inner cusp of the bicuspid cut down to allow the placing of a sufficiently thick crown-plate; B, a cylindrical undercut opening between the cusps for a retaining-pin; C, the third molar,

FIG. 372.



made uniform in size from neck to grinding-surface, the latter also being considerably retrenched; D, the crown-plate of a partial cap, made of pure gold, soldered with 20-carat gold, and so constructed as to cover every portion of the tooth except its buccal surface, the free edge passing up under the gum; E, a

<sup>1</sup> Dr. W. F. Litch.

retaining-pin adapted to the opening B; F, the gold cap for the molar.

“Fig. 374 represents the bridge anchored in position with oxyphosphate cement.

“In the above case it will be observed that there is a considerable space between the bicuspid and cuspid. This made it

FIG. 373.

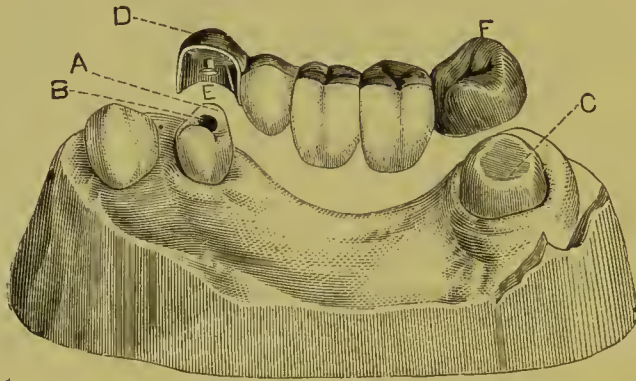
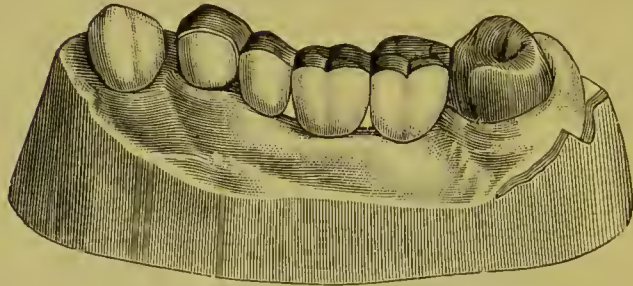


FIG. 374.



readily practicable to give so considerable a thickness to the mesial wall of the partial cap as to hold it securely against the side of the tooth. Had the space been less, contact with the cuspid would have afforded the desired security.

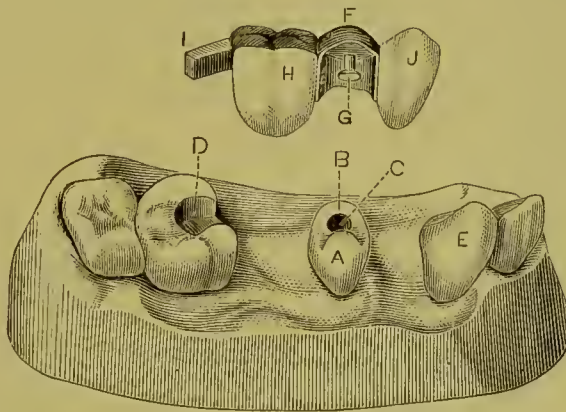
“Fig. 375 represents another case in which a bridge was attached by a bar, partial cap, and retaining-pin. A is an upper second bicuspid (without antagonist); B, its inner cusp, cut down; C, opening for retaining-pin; D, second molar, with slot for bar; E, cuspid; F represents the partial facing; G, the retaining-pin; H, a molar crown of gold, with porcelain front; I, a platinum bar attached to the crown (H) and made to fit into

a slot (at D); J, a plain plate cuspid, heavily backed and strongly soldered to the partial cap, but left without attachment to or contact with the cuspid.

“ Fig. 376 shows the bridge anchored in position.

“ This case, after two years of wear, was still in perfect condition and doing good service. As it was possible to keep the

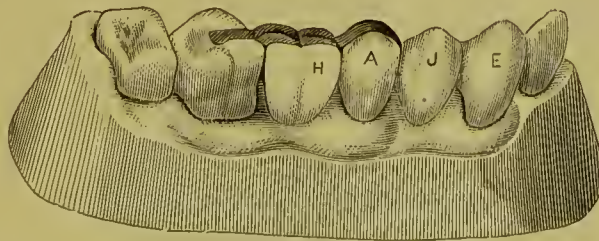
FIG. 375.



gold attachments, backings, etc., out of sight, the appearance presented is very natural.

“ The absence of antagonizing teeth for the bicuspids in each of these cases was a favorable condition, as a considerable thickness could be given to the crown-plate without any interference with occlusion. When the conditions are not so favorable,

FIG. 376.



cutting down the inner cusp to the required extent and sinking the opening for the retaining-pin to the necessary depths are processes certainly to be, as a rule, preferred to the entire removal of the crown for the purpose of ferruling the root for the mounting of a crown of gold and porcelain,—a procedure, however,

not by any means to be indiscriminately denounced, for in many cases it is in the highest degree advisable.

“There is this fact to be considered in regard to the use of the partial caps here figured,—that many patients can be induced to consent to their employment who would refuse to submit to more radical measures, and thus, even when the latter would be advisable, the former may be employed as a compromise, or even as a temporary expedient. Having once tested the advantage of a well-fitting bridge, the wearer is much more likely to consent to whatever measures are necessary to give it security and permanence.”

FIG. 377.

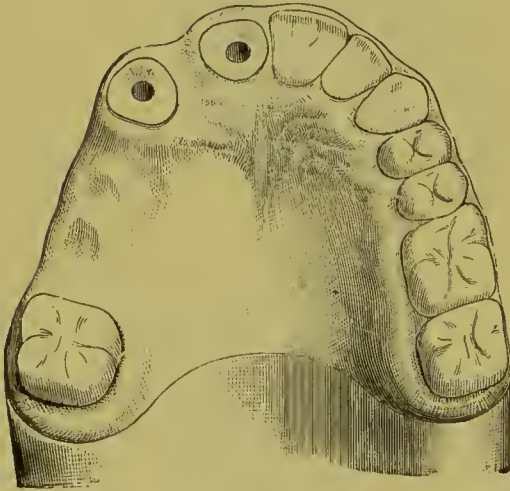
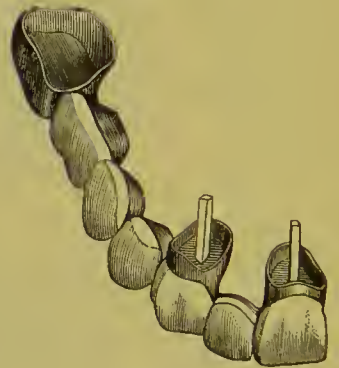
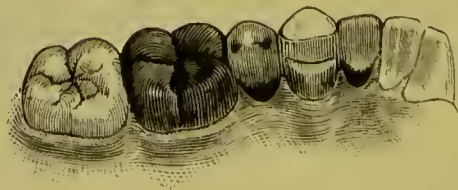


FIG. 378.



*Incisors, Cuspids, Bicuspid, and Molars* combined.—Figs. 377 and 378 represent a piece of bridge-work extending from a central incisor to a molar. In such a case the best method of pro-

FIG. 379.



cedure usually, and specially the one most likely to prevent misfit from warping, is, construct the front section, consisting of the central, lateral, and cuspid; next form the molar cap.

Fit the molar cap and front section of the bridge in position in the mouth, remove in plaster impression and bite, and construct the bicuspid and molar dummies between the cuspid crown and molar gold cap. In a bridge of this character, if the natural cuspid is intact, a shell crown may be used. Fig. 379 gives the palatal view of a piece of bridge-work consisting of a gold cap on the molar and shell cap on the crown of the cuspid, supporting a single bicuspid and a lateral incisor. Fig. 300 illustrates bridge-work similar in principle.

#### EXTENSIVE APPLICATIONS OF CROWN- AND BRIDGE-WORK.

The following illustrations of cemented bridge-work by Dr. H. A. Parr show extreme cases in the way of large operations in which the system has been applied.

Figs. 380, 381, 382, and 383 represent a case in which the roots of the two superior centrals, a partially decayed right first molar, and a badly decayed, pulpless left first molar were all that remained of the upper natural teeth. On the two central roots were mounted collar crowns, and on the two molars all-gold cap-crowns. These four crowns, acting as abutments for the bridge denture, bore between them, proportionally on each side, the force and leverage of occlusion. The contour of the arch in the region of the cuspids was restored by a skillful and artistic placing of the artificial teeth, which are prominent and long.

Figs. 384, 385, 386, and 387 represent a case in which two large and firm superior cuspid roots, and a right pulpless molar, with a saddle on the left side, support a large bridge.

In the case illustrated by Figs. 388 and 389, two superior molars and a second bicuspid on the right, and a first bicuspid and a saddle under the "dummy" representing the first molar on the left side, form the abutments. Prior to the insertion of the bridge-work, the patient had worn artificial teeth on a plate. The advisability of extensive permanently cemented bridge-work, such as is illustrated in this and the case illustrated in Fig. 391, is questionable. The permanency of the latter probably, and most certainly that of the former, cannot be assured.

The lateral force of mastication, exerted on the bridge, will

FIG. 380.

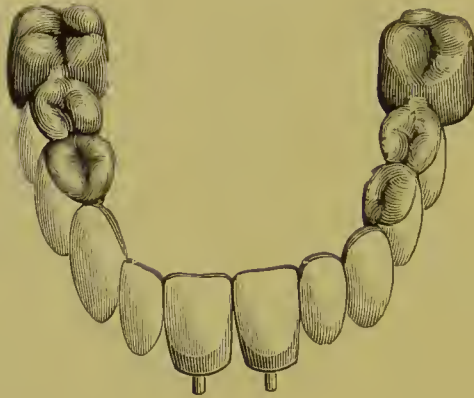

FIG. 381.

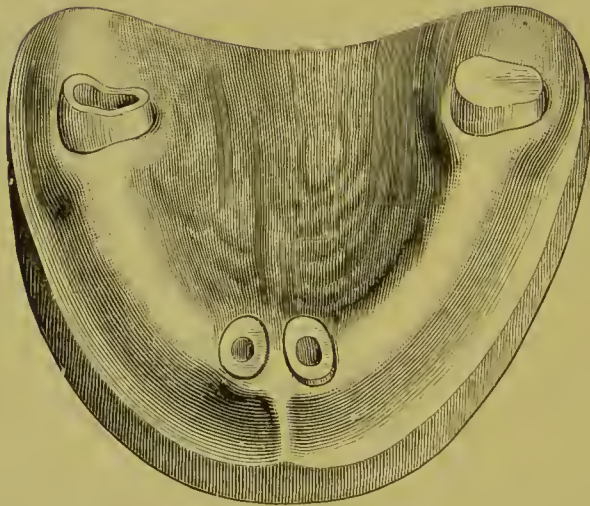


FIG. 382.

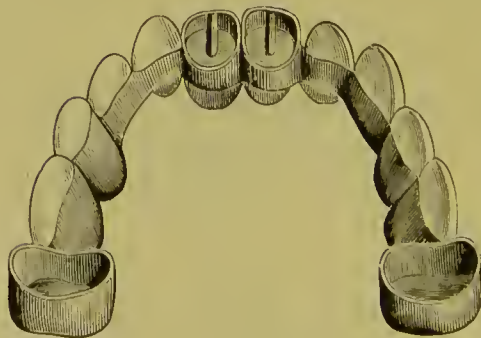


FIG. 383

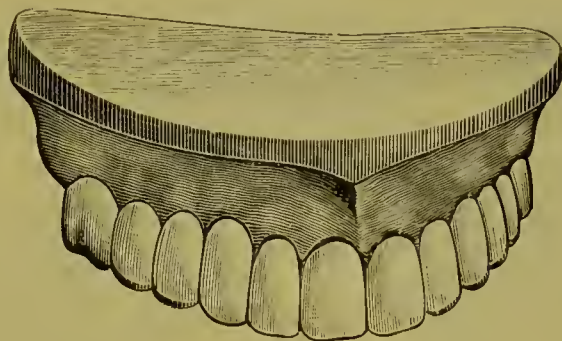


FIG. 384.

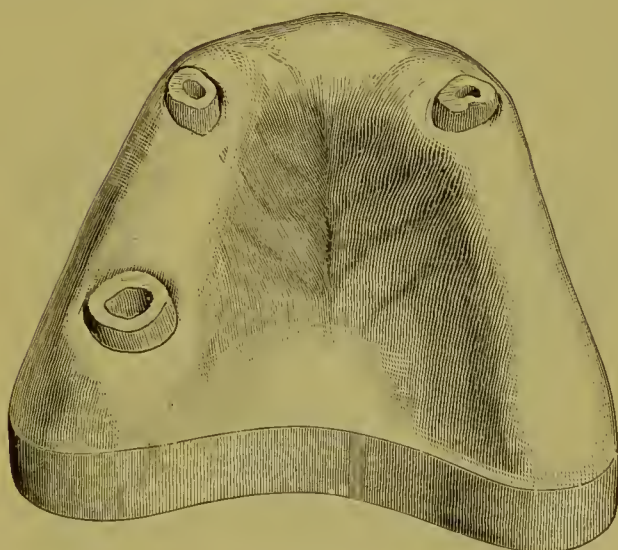


FIG. 385.

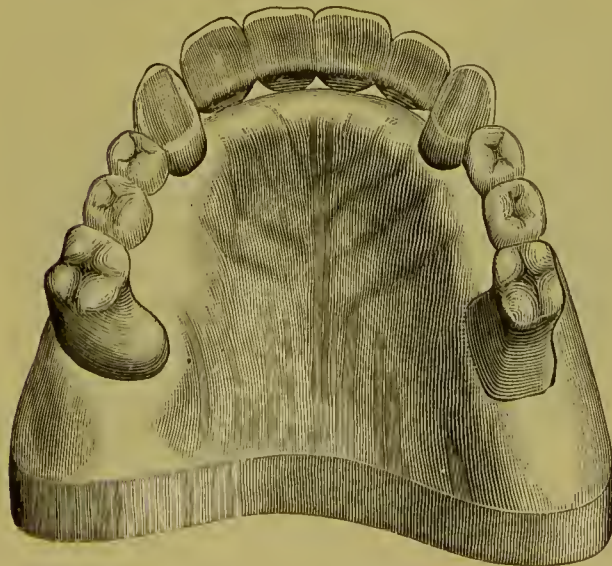

FIG. 386.

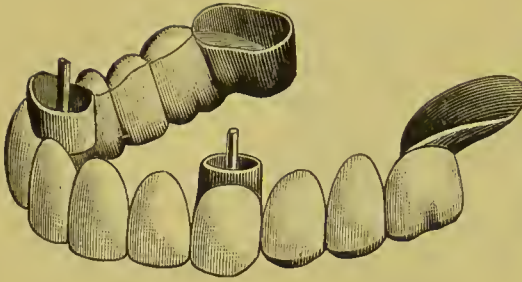


FIG. 387.

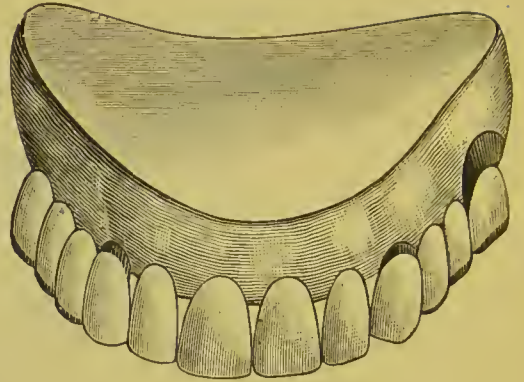


FIG. 388.

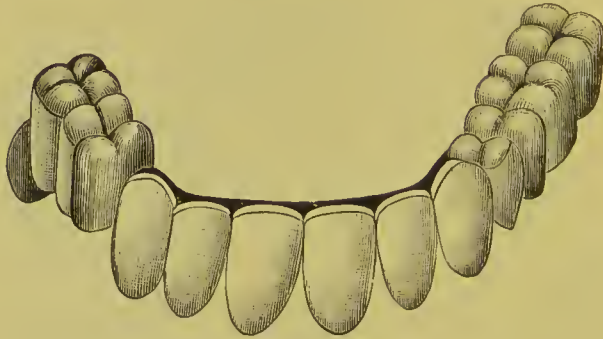


FIG. 389.

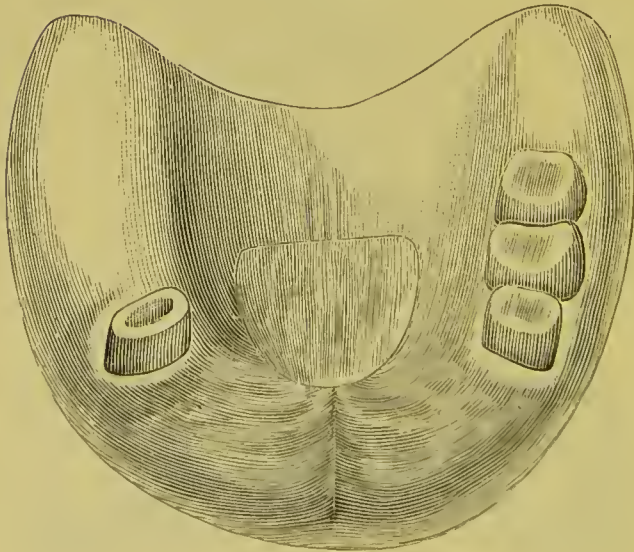




FIG. 390.

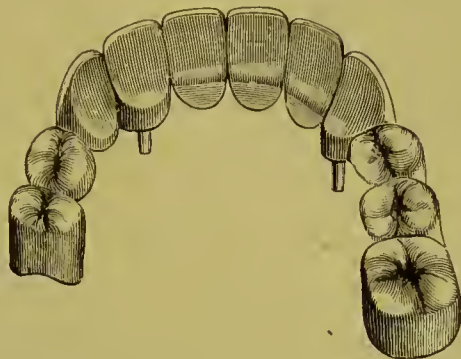


FIG. 391.

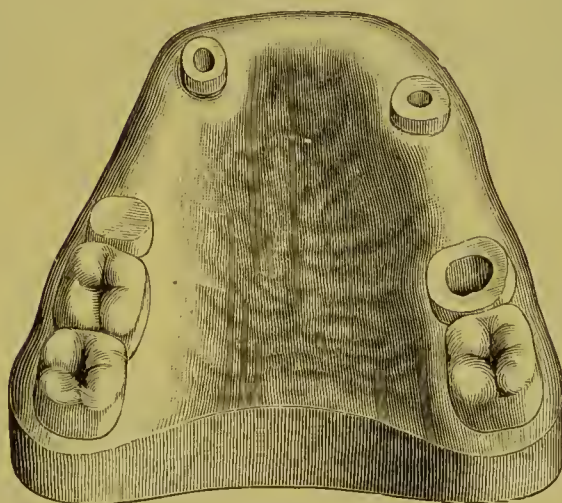
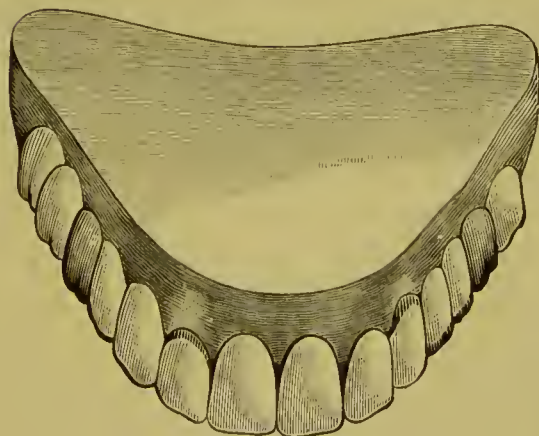


FIG. 392.



especially affect the side on which the saddle is used, and in time is certain to loosen and destroy the abutments. Cases such as these, where the bridge is so extensive and the abutments so few, are more properly served by inserting what are

FIG. 393.

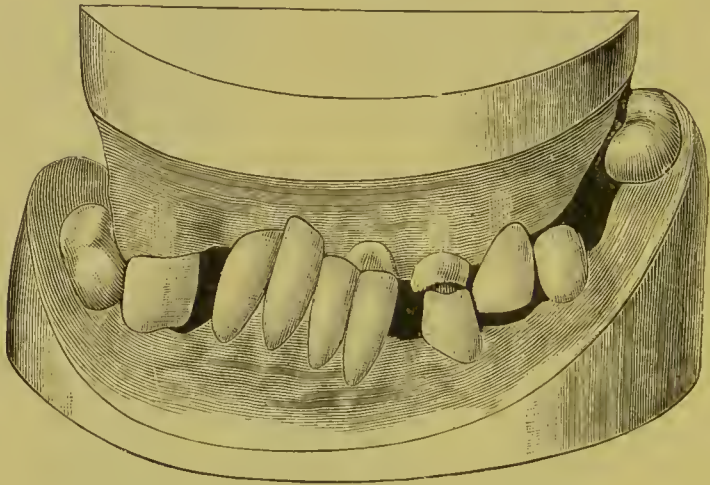
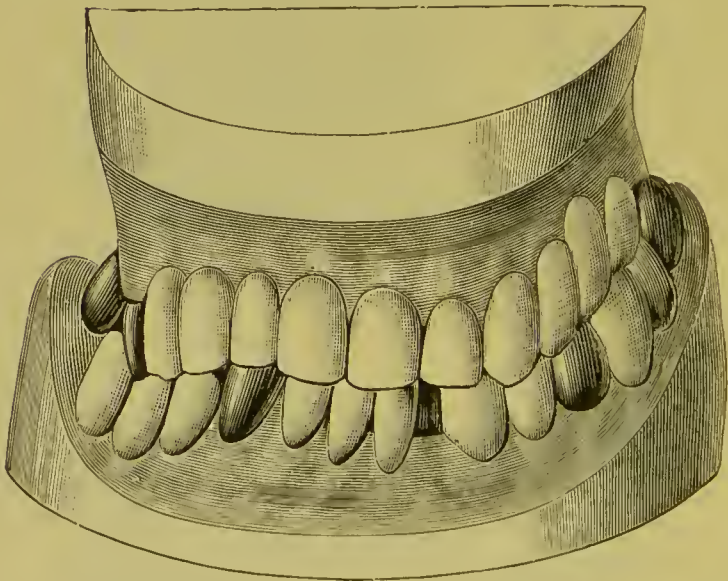


FIG. 394.



termed removable plate-bridges, which have alveolar support in addition to the abutments. The insertion of bridge-work in cases of this character to avoid the presence of a plate can only be regarded as a temporary expedient to afford a respite from that annoyance. It is therefore an expedient not to be in-

dorsed, as the patient in a short time will again have to resort to a plate and again experience the initiatory unpleasantness attending its insertion.

In the bridge-work illustrated in Figs. 390, 391, and 392, crowns on a second bicuspid, a pulpless molar, and the roots of a cuspid and lateral constitute the abutments.

Figs. 393 and 394 illustrate an extensive case of artificial replacement by crowning and bridging operations. Fig. 393 represents the case as presented for treatment. The few remaining superior and inferior natural teeth had no corresponding antagonists, which caused the interlocking and abnormal condition in regard to occlusion shown. The superior right bicupid, the left central, and the left cuspid were crowned, the bicupid being shortened and the cuspid lengthened in the operation. The intervening lateral root between the central and cuspid, having been treated and filled, was allowed to remain. With the three crowns to serve as abutments the intervening spaces were bridged with artificial teeth, the extension on the left side being supported by a saddle. The spaces between the inferior cuspids and molars on both sides were bridged, the bicupid on the left supporting the bridge, instead of the cuspid, as on the right; the left cuspid was crowned and the incisive edges of the incisors trimmed even.

Fig. 394 illustrates the finished case, and shows the complete artificial restoration of the parts.

Figs. 395 and 396 represent a case in which crown- and bridge-work has been extensively applied. The occluding surfaces of the teeth were affected with abrasion. Gold crowns with porcelain fronts which presented laterally the form illustrated in Fig. 395 were mounted on the incisors and cuspids, the pulps of which were preserved. The posterior teeth were crowned with all-gold crowns. The missing teeth, except those on the inferior left side, were artificially restored with bridge-work.

Permanently cemented bridge-work of the extensive style illustrated in some of these cases is now seldom practiced. Removable forms affording alveolar support are adopted in preference. Where the abutments are numerous and offer suitable supports to permit the bridge-work to be constructed in sections around the arch, permanently cemented bridges are permissible.

FIG. 395.

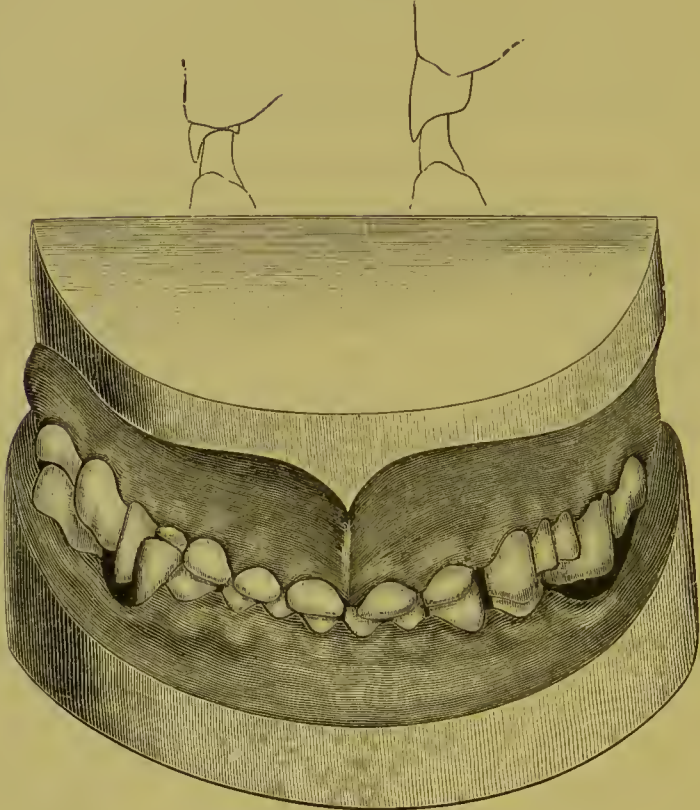
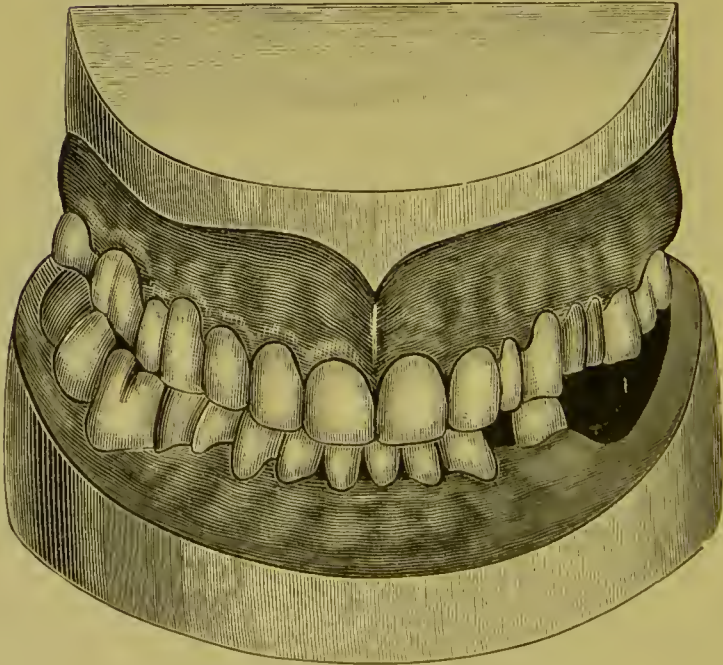


FIG. 396.



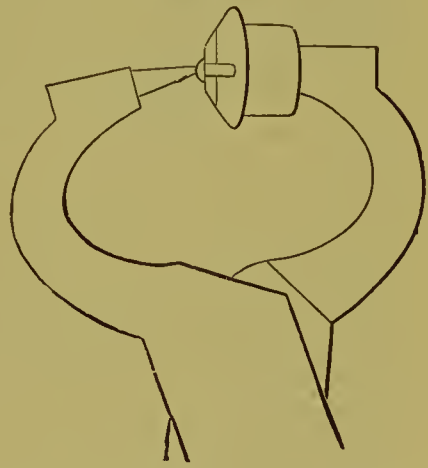## CHAPTER VIII.

### REPAIR OF CROWN- OR BRIDGE-WORK.

THE fracture of a porcelain front to a permanently attached bridge is an annoying incident for both patient and dentist. It is usually attributable to failure to properly protect the incisive edge or occluding surface of the porcelain with metal, a precaution rendered necessary by the rigid character of the resistance offered the antagonizing teeth through the abutments. In most cases the porcelain can be replaced without the removal of the bridge, but the attachment is not usually so reliable as in the original piece. The following is the method commonly adopted with incisors or cuspids.

The surface of the backing to the porcelain is trimmed level, the platinum pins drilled out, and the holes slightly countersunk on the palatal side. A tooth similar to the one fractured, with long pins, is ground and fitted to the backing. If a suitable long-pin tooth is not procurable, the short pins of an ordinary tooth can be lengthened by

FIG. 397.



bending a piece of platinum wire in the form of a semicircle, and soldering its ends to the ends of the pins with pure gold. The wire is then cut in the center, and the lengthened pins trimmed as required. The pins are then riveted on the palatal side into the countersunk holes of the backing. The riveting is best done with punch forceps having a large punch, the porcelain front being protected by a piece of lead placed against the labial aspect (Fig. 397). The heads of the pins should then be burnished smooth with a revolving burnisher. In case of the

fracture of the porcelain front of a bicuspid crown or dummy, a corresponding front is selected with very long pins, and ground to fit. Holes are drilled in the gold, in proper positions, to receive the pins their full length. The pins are then roughened a little with a sharp instrument, and pins and front are cemented to the gold. Should the holes extend through the gold at the palatal side, the cement and the ends of the pins should be covered with gold foil or amalgam. If any gold is present to protect the occluding edge of the porcelain, it should be burnished against the surface.

Another method to replace a porcelain front is the following: Back the porcelain front around the pins with platinum foil, bend the pins down together on the platinum, and hammer them flat. Invest and flow a little gold plate over the pins and platinum, and file the metal down close to the porcelain. Drill a hole in a strong part of the backing on the bridge at a central point, square the hole, and fit to it a piece of square platinum wire. Attach the end of the wire to the backing of the porcelain front with an atom of wax cement, and while warm insert the wire through the hole in the backing on the bridge, and adjust the porcelain front in correct position. Chill, and remove front and wire. Invest, and solder wire to backing on porcelain front with 18-carat gold solder, and then remove all metal from back of porcelain, except what is necessary to secure the end of the wire to the pins. Countersink the gold backing on the bridge sufficient to permit the front to come in position. Slit the end of the wire, cement the porcelain front in position to the backing, and bend the ends outward into two slightly grooved places on the backing. Fill the slit in the wire with gold or amalgam, and smooth the surface.<sup>1</sup>

Dr. R. W. Starr's method differs from the preceding, in that he uses round instead of square wire, cuts the pins of the porcelain front off short, making corresponding depressions in the backing on the bridge to receive them and prevent rotation, and solders the end of the wire to retain the front between the pins. He then cuts a screw thread on the wire, and secures it in the backing with a nut on the palatal side screwed into a

---

<sup>1</sup> Dr. W. W. Williamson's method.

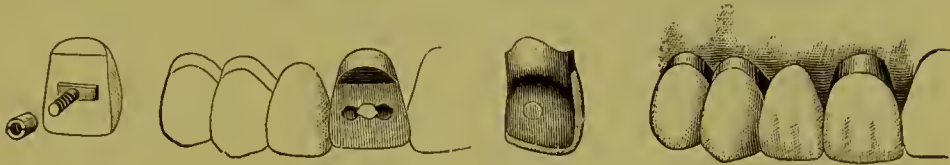
depression reamed to receive it. Figs. 398, 399, 400, and 401 illustrate this method.

FIG. 398.

FIG. 399.

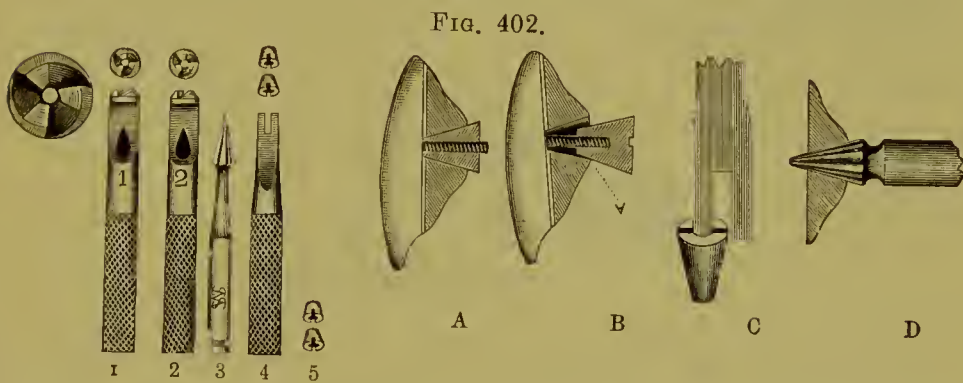
FIG. 400.

FIG. 401.



Dr. E. A. Bryant describes a method<sup>1</sup> of repairing bridge-work by the aid of a set of tools, now made and sold for the purpose, which easily accomplishes the results obtained in the preceding example.

Dr. Bryant's method and tools are briefly described as follows:



Each pin of the selected tooth-facing is to be screw-threaded with die No. 1, Fig. 402, first oiling the pin and finishing it with die No. 2. The pin-holes in the bridge backing are countersunk from the rear with the right-angle engine reamer No. 3 (see A). With the nut-driver No. 4, one of the gold nuts No. 5 is caught on one prong (see B), and started on one of the pins (see C), and then the other nut is likewise started. Turning one after the other, the nuts are screwed tightly on, and then with engine points the projecting pins and nuts (see D) are ground flush with the backing.

Bridge-work can be made with replaceable porcelain fronts which can be easily substituted in case of fracture. A description of their application will be found at page 184.

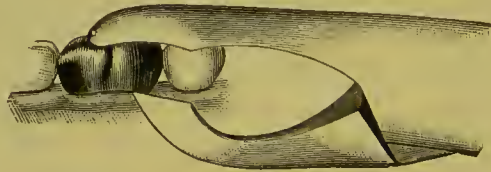
<sup>1</sup> *Dental Cosmos*, June, 1894, page 370.

If the character of the breakage is such as will not permit its repair in the mouth, the bridge must be removed for the purpose and then reinserted. Under such circumstances the advantages of bridge-work in a detachable form are most evident.

The results following the repair of single crowns in the mouth will seldom repay the labor attending it.

*Removal of Cemented Crowns and Bridges.*—When it becomes necessary to remove an artificial crown, whether inserted singly or as a support for a bridge, incisors or cuspids are detached by grinding the gold or porcelain away at the palatal section over the post, which when exposed is severed, and the attachment of the cement broken up. The collar can also be slit and bent aside if found necessary. If previous to cementation the post of the crown is covered with a film or sheath of gutta-percha, as described in process of cementation on page 137, the detach-

FIG. 403.



ment of the post when the crown is well heated is usually easily effected. In an all-gold cap-crown on a posterior tooth a hole drilled in the grinding-surface will give access to the cement, a sufficient quantity of which can then be removed to loosen the attachment; or, the collar can be divided and pried up from the root by first making a groove with a small rubber and corundum disk, and then cutting the gold with a sharp instrument. A crown-cutter, an instrument made for the purpose, will facilitate this part of the operation (see Fig. 403). With care and patience in the operation, the crowns will not usually be injured beyond repair.

When gutta-percha is the cement that has been used, a hot instrument or crown-setter (see Fig. 263) can be placed against the metallic part of the crown, or the crown seized with the beaks of heated forceps, the gutta-percha thereby softened, and the crown removed.



A hole or slit in a gold collar or crown is repaired easily by first placing a piece of soft wax in the hole or slit on *the outside of the gold*, adapting a piece of platinum foil larger than the aperture on the *inside* close against the gold, and fixing it to the wax. The interior of the crown is next filled with investing material, and solder flowed over the platinum and gold on the outside of the collar or crown. The crown should be heated slowly, to allow the plaster to dry out before the soldering is begun.

## CHAPTER IX.

### THE HYGIENIC CONDITION OF THE MOUTH AS AFFECTED BY BRIDGE-WORK.

THE probable future condition of a mouth in which a piece of bridge-work is permanently fixed is a matter of the deepest interest to both patient and operator. There is no valid reason why an artificial structure in the mouth should be more hurtful than that which is natural, provided that correct conditions are observed in its construction and proper measures are taken for their maintenance. The natural teeth demand care on the part of their owners, and all forms of artificial dentures require attention to secure their cleanliness and thus preserve the health of the adjacent tissues. What will result from the wearing of a permanently fixed bridge is almost wholly dependent, in the first place, on the proper application of principles and correct formation in every detail of construction of both crowns and bridge-work; and in the second place, upon the maintenance of cleanliness. Neglect of a single requirement will so far detract from the usefulness of the work, and may influence the final result disastrously.

Firm, properly selected abutments will not redeem incorrect conception or faulty construction; neither will the best construction remedy that which is wrong in principle or application. Self-cleansing spaces, if improperly formed, have exactly the contrary effect from what is intended, by becoming receptacles for particles of food *débris*, instead of preventing their accumulation.

Inaccessible spaces or interstices, which are always apt to cause uncleanness, should be avoided. Continuity of structure of the several parts is also essential to fully insure perfect hygienic conditions.

The health of a mouth containing a piece of bridge-work constructed under these precautions can be readily maintained. For this purpose a suitably formed brush and a dentifrice are necessary. Floss silk can be passed through apertures around the necks of crowns, in places out of reach of the brush, and drawn along the gum under the bridge by the aid of a slightly curved blunt-pointed needle, to remove accumulations of *débris* otherwise inaccessible. A solution of a detergent and disinfectant mouth lotion in water, injected with a dental syringe, can be used advantageously to wash out such places and maintain a healthy condition of the gums. In addition to these measures, the crown and bridge should be thoroughly cleansed by the dentist at regular intervals.

So cared for, a permanently fixed bridge will not militate against the absolute wholesomeness of the mouth; but it can hardly be expected that the insertion of bridge-work will insure a state of the mouth which for cleanliness will be superior to the presence of the natural teeth. Neglect on the part of the patient to perform such duties as are necessary to preserve the natural teeth in a healthy state will have about the same effect on an artificial denture. The attention required to be given to bridge-work is not greater than is commensurate with the advantages which it confers on the wearer.

## CHAPTER X.

### REMOVABLE AND DETACHABLE BRIDGE-WORK.

THE evident advantages of bridge-work early stimulated the inventive genius of dental mechanists to improve the methods and forms of its construction and to extend its application. With these objects in view, methods have been introduced by which bridges are so constructed as to be removable by the patient or detachable by the dentist.

The construction of bridge-work in either of these forms overcomes the chief objections argued against the system. Large bridges are much more easily made in a detachable or removable form than are the smaller pieces, which present some of the best features of the permanently attached methods.

In all kinds of removable bridge-work a prime requisite is that the posts and collars, or other form of attachment used, shall be so constructed that the piece shall move evenly on or off the supporting roots or crowns in adjustment and removal. To secure this, the post-cavities and the gold crowns should be so shaped that the lines of the cavities and of the sides of the gold crowns shall be as nearly as possible parallel to one another. To facilitate this, a post of wood or metal may be first accurately but loosely inserted in any root-canal intended to receive a post, and left protruding a quarter of an inch, and an impression taken. On the model made from this impression the post will be found placed as in the mouth. The position and shape of the natural teeth or roots can be thus studied, and their plaster forms trimmed as a guide. Gutta-percha or impression compound, fitted to the model and removed with the posts in position in it, can then be used to guide the operator and gauge the preparation of teeth or roots in the mouth. Posts, or the tubes inclosing them, should be placed as nearly as possible in

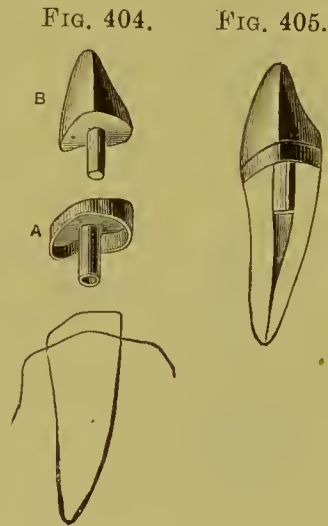
the lines of the root-canals to avoid weakening the side or sides of the root.

When a molar leans forward, the removal of a portion of the anterior approximal side usually restores its perpendicularity sufficiently, as does the cutting away of the posterior side of a bicuspid which inclines backward.

The methods and forms of attachments most commonly used in the different styles of removable bridge dentures are very similar. A preliminary description of these and of their constructive details is therefore first in order.

#### REMOVABLE INCISOR OR CUSPID CROWN.

A removable gold crown with a porcelain front is frequently used in connection with removable bridge-work where incisors or cuspids form abutments. The *cap and tube crown* is the style (Fig. 404) preferably applied. It consists of a cap for the end of the root with a tube attached extending up the root-canal, and on the cap the crown with a post fitted tightly to the tube is adjusted. To the crown so formed (Fig. 405) the bridge is joined in the usual manner. The end of the post can be formed with a slit which will permit this portion to be slightly expanded, making what is termed a spring-post. The constructive details of this crown are as follows: The root is first prepared and capped the same as for a collar crown. The collar can be formed of gold and the cap section of platinum, No. 32 gauge (A, Fig. 406). A substantial piece of gold and platinum wire, from No. 16 to No. 18 gauge (the number being regulated by the size of the root), is slit for about one-eighth of an inch to form a spring-post. This is easily done by placing the wire in a vise and steadily cutting it downward from one end through the center to the required depth with a saw-edged strip of very thin steel (Fig. 407). This takes only a few minutes, and is preferable to the method sometimes adopted of partially joining two pieces of half-round wire.



The wire is then tapped together at the slit, burnished smooth, and rounded just at the end (B, Fig. 406). The tube for this post is formed by once encircling the post with a piece of iridio-platinum plate, No. 34 gauge, the edge of which is beveled and cut to meet the plate even and close (C). The post is then withdrawn, and the seam is touched along its length with the smallest possible quantity of borax. The proper way to use borax in fine work is to grind it, mixed with water, on a slab, to a cream-like consistence, and apply on the point of a camel's-hair brush. A very small piece of pure gold is placed in the seam, and the tube is held in a Bunsen flame. When a sufficient degree of heat is reached, the gold will flow along the seam and form a joint without obstructing the inside passage

FIG. 406.

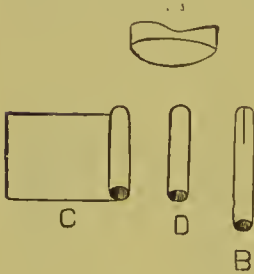


FIG. 407.

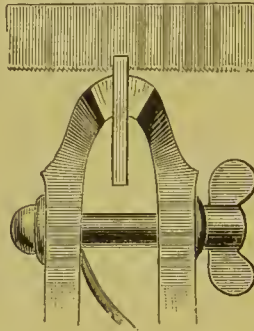
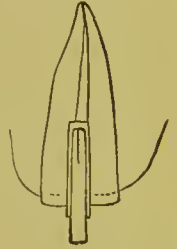


FIG. 408.



for the post. The post is then inserted, and the tube trimmed (D), and gauged in a gauge-plate. With a drill just the size of the tube the root-canal is enlarged so that the tube will fit tightly (Fig. 408). This plan prevents weakening of the root by too great enlargement of the canal. A hole the size of the tube is made through the cap, and cap and tube are then adjusted, waxed together, and, the post being withdrawn, they are removed, invested, with the investing material inserted in the tube, and soldered. The second or outer cap is then constructed for the root-cap, of a piece of platinum about No. 34 gauge. It is perforated in the center, and the post fitted in proper position. At the palatal and approximal sides, if desirable, the platinum can be slit and bent over the edge of the root-cap to form an inner partial band or flange, or a half band can be formed of a piece of

plate, the open space at the labial side being filled with the porcelain tooth. The outer cap and the post, having been cemented with wax, are removed and soldered together. As the point of the post may have to be filed, it is well to place it so that the line of the slit shall cross the tooth from mesial to distal side. On this outer cap the porcelain front is fitted and soldered. The end of the tube is closed with a little gutta-percha, and the root-cap cemented on the root with oxyphosphate and the crown placed on it, which helps to bring the root-cap to its place and insures the intended position of the crown. When necessary, the split post can be tightened in the tube by slightly springing it open. Fig. 405 represents the finished crown. The incisive edge of the porcelain does not necessarily require to be protected with metal as in fixed bridge-work.

A square tapering post, either solid or split in some cases, is preferred to the form above described, especially in a root of a cuspid. When a split post is used, the points should be soldered together. The lower section of the post can then be alone expanded and tightened in the tube (Fig. 409). To receive the tube and post, the canal should be carefully deeply opened and then shaped with a reamer, such as is illustrated at Fig. 72.

FIG. 409.



FIG. 410.

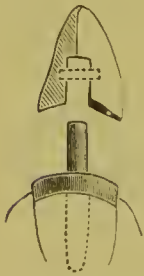


Fig. 410 illustrates a removable cuspid crown which can be used in removable bridge-work. It is constructed as follows: The end of the root is first capped, and a post attached fitting the root-canal. A porcelain cross-pin tooth, the pins of which are set well apart, is then ground and adjusted in position, cemented with wax to the cap, and both removed. Enough plaster to form a matrix is placed on the labial aspect of the porcelain and collar to hold them in relative position when the wax is removed. A flat post is then formed on the root-cap, extending from the palatal edge forward between the pins of the tooth, the porcelain of which, between the pins, should be slightly cut out to receive it. To this is soldered the piece A, which is to act

as a spring. The post is formed of gold plate No. 18 gauge, and the spring of elasp or spring gold No. 26. The post is soldered to the cap from the opposite side to the spring by investing without the tooth. The tooth is then lined with very thin platinum, and with the aid of the matrix is adjusted in position on the cap, and a thin piece of platinum plate is slit at the edges and adapted over the post, cap, and edge of the collar, with its inner edge meeting the backing of the tooth. The platinum plate is then cemented with wax to the backing on the tooth, removed with it from the cap and post, and invested, the slot for the post being carefully filled with the investing material. Twenty-carat gold solder is then flowed over the plate and backing so as to consolidate the parts in one piece.

This crown when finished will fit on to the cap and post, the spring of which can be bent to securely retain it. The line of the post on the cap as it fits in the slot in the crown should be such as will favor the insertion and removal of the bridge.<sup>1</sup>

In the form shown in Fig. 411, which is a sectional view, a square or round iridio-platinum wire is used as a post on the cap instead of the form above described.



The post having been soldered to the cap, a thin piece of platinum is first perforated and fitted over the top of the cap, next a tube of platinum over the post and between the pins of the porcelain. The porcelain front is then lined with platinum foil, and cemented with wax to the tube and the platinum at the base, and removed and soldered together. Where one end of a bridge is securely attached to a molar, the form of crown here described is ample support for the other end on a cuspid.

#### REMOVABLE BICUSPID AND MOLAR ATTACHMENTS.

Bicuspids and molars, especially the latter, in all cases where possible, are the teeth selected and most depended on to support all forms of removable bridge-work.

*Removable Partial Cap and Collar.*—This is a form of attach-

<sup>1</sup> Dr. Parr's method.



ment made to fit over a natural tooth, or more frequently a gold crown.

The sides of the natural tooth have to be first trimmed as nearly as possible straight or parallel to the sides of any other supporting crown or line of attachment. If the tooth is to be first capped, a straight-sided gold crown is made and fitted. A fusible-metal die of the gold crown is then made; or, better still, the gold crown is removed, a strip of damp paper wound around it, and fusible metal melted and poured in crown and paper tube. This forms a die of the crown, with a shank as seen in Fig. 412. When the natural tooth is not crowned with gold, a die of the tooth is made in a manner similar to that described on page 93, and in chapter on "Molds and Dies." The crown is then encircled with a strip of pure gold about No. 30 gauge, one part of which will extend above the rest in the form shown in Fig. 413.

FIG. 412.




FIG. 413.

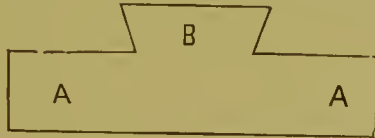
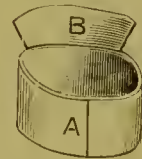


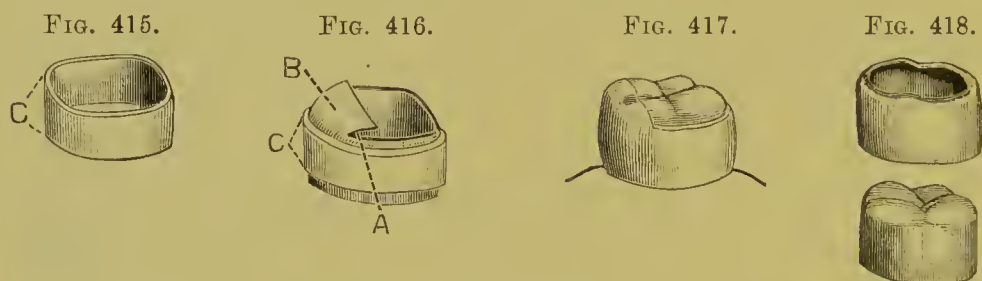
FIG. 414.



The sections of the gold at A, A are to reach from the edge of the neck of the crown to or slightly above the occluding surface. The gold is fitted evenly, but not tightly, around the crown, the ends being placed at the side opposite to that where the collar will be joined to the bridge if the space permits. The collar is then removed and the ends soldered together (Fig. 414). The collar is readjusted on the crown, and the part at B, Figs. 414 and 416, bent down over the occluding surface, so that it nearly meets the collar section A. On the outside of the collar a slightly narrower strip of gold clasp plate, No. 30 (Fig. 415), is next adjusted in the position shown at the lines C, Fig. 415, then removed and the seam, which had best be located at the point C, Figs. 415 and 416, soldered together. It is readjusted on the

gold collar, removed with it, and soldered to it. The collar can be invested for this purpose, but the work is more easily done by holding the collar in a Bunsen flame and placing small pieces of solder in position in the seam. Only enough solder should be used to unite the parts, any surplus being carefully avoided. Painting the inner surface of the collar with whiting will prevent the solder flowing there.

The collar section of the removable cap is then trimmed smooth. The cap section at B can be adjusted and soldered to the collar now, or preferably after the cap has been united to the bridge, and its relative position on the gold crown accurately determined. Fig. 417 shows the gold crown and the finished removable partial gold cap over it.



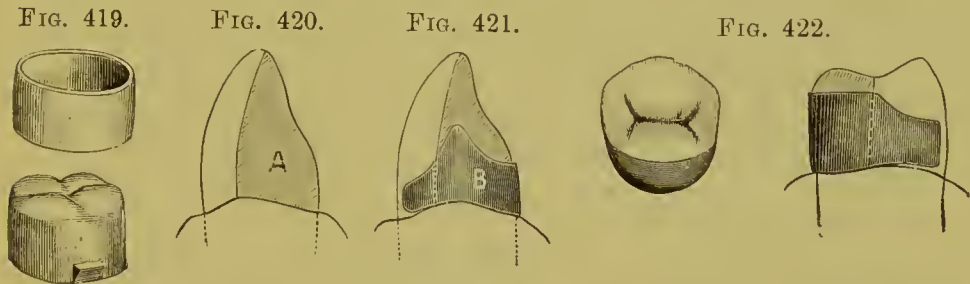
The gold crown is freed from the fusible metal by dropping it with the die into a ladle containing a quantity of melted fusible metal. The portion within the crown will melt in with that in the ladle and leave the crown, which should then be removed and immersed in nitric acid to remove any traces of the fusible metal still adhering to the gold.

*Flanged Collar Attachment.*—Fig. 418 shows another form of removable partial cap. In this the entire edge of the collar is bent over on the occluding surface of the crown, and thereby supported in position. In the construction the edge of the pure gold collar should be shaped to form the flange.

This form of collar may also be made entirely of clasp gold, No. 28 gauge for molars, and of No. 29 to 30 gauge for bicuspids. The process is: An accurately fitting collar is first made. The collar is then, by tapping with a small horn or copper hammer, aided by frequent annealings, shaped on the gold crown or die of the tooth. The flange section can be slightly thinned with

a small corundum-wheel, and then or subsequently brought to position over the gold crown, or the tooth, and stiffened with solder. When the collar is shaped over the gold crown, the crown should be first filled with fusible metal as previously described.

*Spur Collar Support.*—Fig. 419 illustrates a form in which a straight-sided removable collar is maintained in position by a lug or spur on the side of a gold crown.



*Removable Partial Cap and Clasp Attachment.*—In this form a partial cap in combination with an elastic gold clasp, encircling only a portion of the crown, is used instead of a collar. Its application is principally confined to a cuspid or bicuspid tooth or an artificial crown.

The attachment is best constructed on a metallic die, either of the natural tooth or of the artificial crown mounted on a model. In the case of a cuspid a piece of pure gold, No. 31 gauge, is adapted to the palatal surface and partly over on the approximal side, in the form shown at A, Fig. 420. In some cases it may be extended to the incisive edge. A gold clasp of at least 24 gauge is fitted over the gold partial cap in the position shown in Fig. 421, the cap being beveled to an imperceptible edge on the sides at the points where the clasp passes forward, to assure perfect adaptation. Cap and clasp are next cemented with wax, then removed and joined at the approximal sides with a very small quantity of solder. The attachment is then ready to be connected to the bridge denture, which should be done by soldering the clasp portion only at the point B, Fig. 421. This method allows the soft gold of the cap portion to be again adapted to suit any position the clasp may assume in the final adjustment of the denture in the mouth. The bridge and

clasp should then be invested again, and solder flowed over and between the cap and clasp.

*A Bicuspid or Molar Partial Cap and Clasp Attachment.*—Fig. 422 illustrates the form the attachment just described usually assumes in cases of bicuspids and molars. The dotted line marks the boundary of the partial pure gold cap. The construction follows similar lines to those laid down in the case of a cuspid. If preferable, the cap section can be burnished down against the crown; and if necessary, it can be slit, and solder can be flowed over it at the final adjustment of the bridge. This form of attachment is especially useful in cases where a natural tooth tips out of line so as to render it difficult to entirely encircle it with a continuous band.

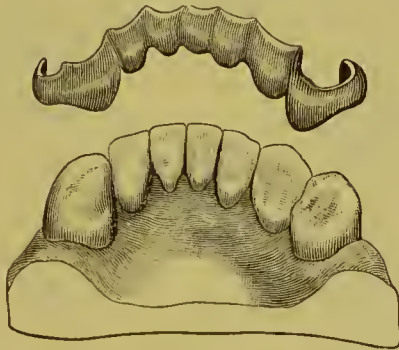
Pure gold has been given the preference to thin platinum in the construction of these partial caps, for the reason that the form and the position of the former are less liable to be altered in soldering, an advantage which is relatively more important than the non-fusible quality of the platinum.

The forms of attachments described for removable bridge-work are those most generally applied in practice. The methods for their construction, which as given are the results of practical experience, may in some respects differ from those followed by others. In application, as will be shown, they enable the operator to avoid difficulties often encountered in obtaining a proper adjustment of removable bridges on the abutments and alveolar border. Special forms of attachments not in general use will be described in the succeeding chapters, in their application to practical cases. Their use in combination with the forms already explained may at times prove advantageous.

*Connecting Bars.*—Connections between the different sections of a removable bridge are formed in the following manner: An impression of the case or of the part to be spanned is taken in plaster, and a cast made by pouring into it fusible metal which melts at a point less than or not over two hundred degrees (see chapter on "Molds and Dies"). The cast must correctly represent the lingual or palatal surfaces of the teeth. Upon this cast a strip of pure gold, No. 30 gauge, about one-quarter of an inch in width and of the proper length for the required connecting-

bar, is burnished over the palatal or lingual surface of the teeth intervening between sections of the bridge or attachment to be connected. Wax is placed on the surface of the gold, and the gold is removed and invested. The wax is next removed, and a piece, or pieces, of gold clasp plate, a trifle narrower than the strip of pure gold, is bent and shaped to fit over its surface. Twenty-carat solder is then flowed over the gold in quantity sufficient to join the parts, level the surface, and make a rigid bar capable of resisting such force in use as would tend to destroy its shape in the slightest degree. When the bar is formed on the metallic cast it can be transferred to the plaster model, and then, or in the subsequent construction of the work, connected to the attachments; or the bar can be adjusted

FIG. 423.



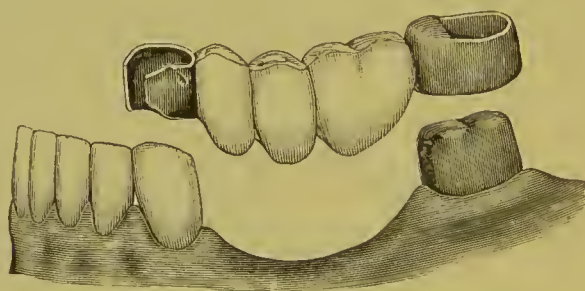
in the mouth, cemented with wax or ligatured on the teeth, the attachments placed in position, and the bar and attachments removed in their relative positions in a plaster impression. On the model made from this impression they will be found the same as in the mouth. The construction of the bridge can then be continued. Fig. 423 represents a bar of this character to span the lower front teeth and connect attachments on the cuspid and bicuspid.

*For the Upper Front Teeth.*—Where a bar narrower than the one described is required, the strip of pure gold should be cut proportionately, and pieces of half-round iridio-platinum or gold clasp wire used to form and stiffen the bar, instead of gold clasp plate. Iridio-platinum wire may be used without the pure gold base, but in such a case the sections of the wire are

best soldered with either pure gold or 22-carat plate. Methods for connecting sections of a bridge are illustrated in Figs. 300, 353, 355, 428, 436, 447, 482, 611, and 615.

*Construction of Removable Bridge-Work.*—In removable, as well as other styles of bridge-work, the method of procedure is governed entirely by the conditions presented in each case. Therefore directions given regarding bridge-work embracing certain teeth and attachments in one instance may vary considerably from what is required for the same tooth in another; consequently the process of construction can only be outlined in somewhat general terms.

FIG. 424.



A case frequently presented, involving the loss of a portion of the lower teeth, as shown in Fig. 424, will be taken to illustrate the method generally adopted for the construction of removable bridge-work.

The molar is shaped to receive a gold crown. The anterior approximal side is trimmed parallel with the line of the posterior side of the cuspid. Removing a little of the enamel on the distal side of the cuspid will assist the operation and straighten that part of the tooth. A straight-sided gold crown is made for the molar. A bite is first taken in wax for articulating model and then a plaster impression, which will remove the gold molar crown in position, and a cast is made as follows: The form of the cuspid is first filled with fusible metal, and the remainder of the impression with pure plaster, as described in chapter on "Molds and Dies."

A die is then made of the gold crown and a removable cap for the gold crown on this die, and a gold partial cap and clasp attachment are made on the metallic form of the cuspid. Dum-

mies are then fitted and soldered together, placed in position, and joined to the attachments with wax cement. The bridge is then removed from the model, invested, and soldered together. In the removal of this style of work from the mouth or from a model, should the wax not hold the parts reliably together, plates should be placed over them, so that when removed they can be accurately readjusted in the plaster. Connection with the attachment is only to be made at the collar section. The gold crown and fusible metal are then separated from the model and the fusible metal removed from the crown in the manner described on page 218.

The molar crown and the bridge are then fitted to the mouth. The crown is next cemented on the molar and the bridge immediately adjusted over it, pressed into position, and allowed to remain until the cement has set. The partial cap section of the attachments is burnished down on the bicuspid and the gold crown on the molar, while the bridge is kept firmly pressed against the gums. The bridge is then removed, invested, and the partial cap sections made rigid by flowing gold solder over them. The final trimming, finishing, and polishing of the bridge are then performed, and it is ready for insertion.

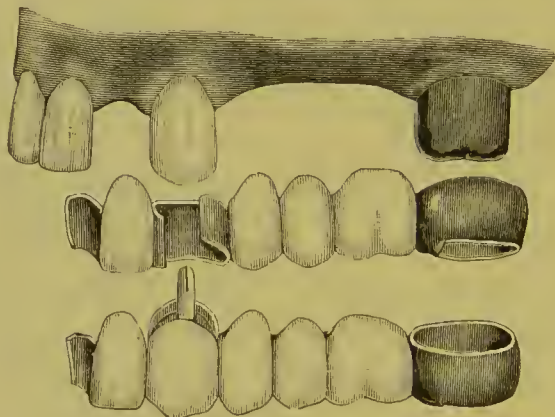
The procedure in the case described can be varied by making the entire model of fusible metal, or by placing a little wax in the interior of the grinding-surface of the gold crown, making a plaster model, removing the gold crown and filling it with fusible metal, making the attachment and replacing the gold crown on the model. The cuspid attachment can be formed on a fusible metal cast of the tooth.

The methods of construction as above given may be still further varied by first forming the gold crown and attachments to it and the cuspid, fitting them in position in the mouth, taking a plaster impression which will remove them in position, and then making a model of plaster and calcined marble-dust. On this the dummies can be fitted and soldered to the attachments. The gold crown is to be removed from the model after the position of the attachment on it is secured by the investing material, and the cavity in the investment is then to be filled with more investment material.

Removable bridge-work is best constructed with the bases of the dummy teeth pressing firmly on the tissue of the gum. If the collar of the molar attachment should prove difficult to remove when first inserted, it should be slit at the posterior section, slightly expanded, and reunited with solder, when the cap sections of the attachments are stiffened in the final process of soldering. A small piece of gold plate can be inserted in the aperture of the collar to aid the gold to unite the ends.

In Fig. 425 are illustrated the two forms of removable bridge-work that could be constructed for the same case. In the one a clasp attachment is placed on the natural cuspid, in the other the natural crown is excised and a removable cuspid crown con-

FIG. 425.



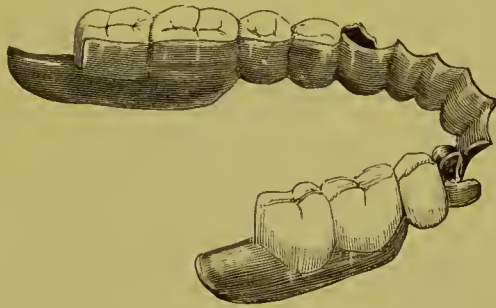
structed. In the construction of either style, a gold crown is made for the molar, with a removable gold partial cap and collar attachment. A removable partial cap and clasp attachment is made for the cuspid, or, if the natural crown is excised, a removable cuspid crown, and the cap and tube section cemented in position on the root. The crown or crowns and attachments are adjusted in position in the mouth. If the cuspid attachment is used, and it seems liable to become misplaced, it can be ligatured to the natural crown. An impression and bite are then taken in plaster, and when removed from the mouth the crowns and attachments are to be replaced in position in the impression, and a model of plaster and calcined marble-dust made, and also an articulating model in plaster. The lateral and bicuspid and molar dummy teeth are next fitted in proper position on the



model. A piece of pure gold is adapted against the lateral, and burnished over the palato-approximal side of the central to form the flange. The case is then invested, the gold crown slipped out of the attachment, the place it occupied is filled with additional investing material, and the parts are all soldered together. The construction can be varied by first making the bridge from the molar to the cuspid, and then adding the lateral and flange. When finished, a suitable quantity of cement is placed in the gold crown, the crown is fitted on the molar, the bridge adjusted in position, and the teeth occluded and so allowed to remain until the cement sets.

The denture illustrated in Fig. 426, a case of Dr. A. S. Richmond's, was made to restore a loss of teeth which is frequently

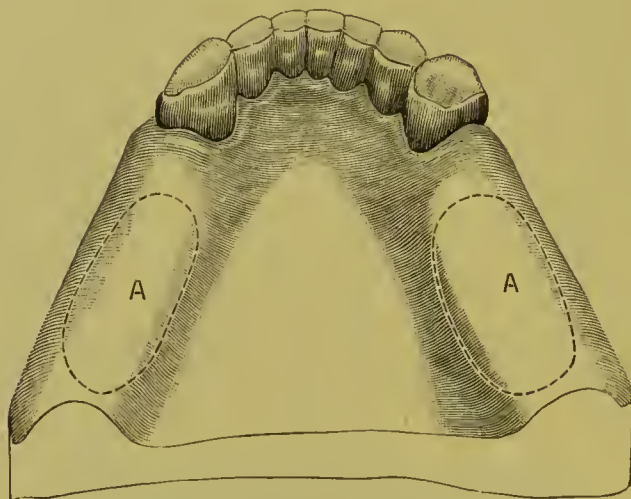
FIG. 426.



met with, but one not suitable for the insertion of cemented bridge-work. The application of a removable denture combining bridge- and plate-work is a method possessing advantages over those ordinarily practiced. In brief, the constructive details are: A connecting bar is formed as described on page 220. In the case in hand, when the pure gold to form the connecting bar was adapted to the cast, it was extended around and over the cuspid and bicuspid. Gold clasps were then adapted over the pure gold on these teeth, and attached with solder. The bar and clasp attachments were inserted in the mouth, an impression taken in plaster, and a model made with the attachments and bar on it in position. Metal casts were also made of the parts at A, A, Fig. 427, and two gold plates struck up. The teeth were then arranged in position, the bicuspids resting on the gums and the molars on the two plates or saddles, and the denture completed as shown in the illustration.

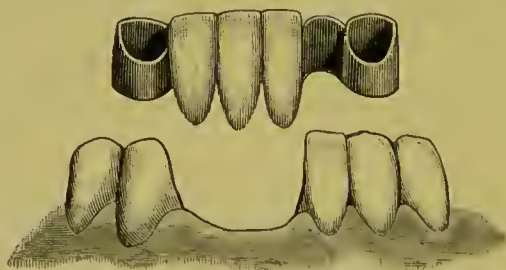
Removable bridge-work offers peculiar advantages for artificial replacement of lower incisors in cases similar to that

FIG. 427.



illustrated in Fig. 428. A portion of the contour of the approximal sides of the right cuspid is removed. Shell caps for the right and left cuspid are then formed of crown gold, reaching nearly to the margin of the gum. The caps are encircled with a narrow strip of stiff gold plate or clasp metal, about No. 35 gauge, which is soldered to the caps as described on page 220 in the construction of molar partial caps. The caps are next adjusted in the mouth, and an impression and bite taken in plaster and the caps removed in it.

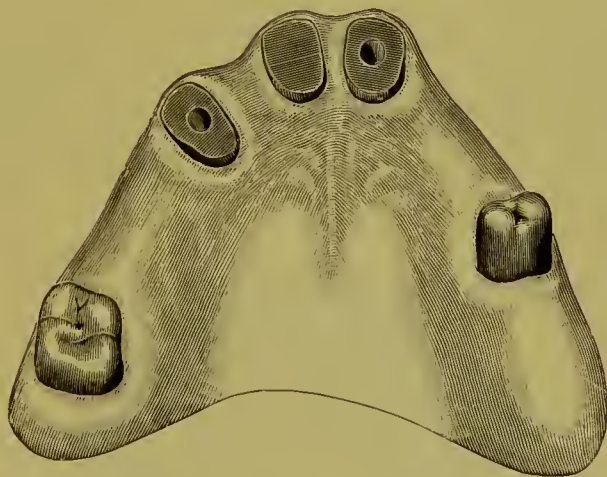
FIG. 428.



A model of half each plaster and marble-dust and an articulation in plaster are then made. Porcelain incisor teeth with straight pins are fitted in position, backed, and a broad bar extending from the lingual-approximal side of the gold cap on the left cuspid around to the mesial side of the lateral is formed of a

strip of pure gold, adapted to the parts, overlaid, and soldered to a slightly narrower strip of gold clasp plate. The different portions are then cemented together with wax, invested on the model, and properly united with solder. When finished and inserted in the mouth, it constitutes a denture that can be worn without inconvenience by the patient, and removed daily and cleansed, which last especially is a great advantage, as in a case like this the teeth replaced have usually been lost by pyorrhea alveolaris and those remaining are affected by the same trouble. The natural teeth, if loose, are in a measure steadied and supported by the appliance. In some cases, especially if the teeth tip, one or both of the attachments on the cuspids can be made of thick elasp metal in the form of a clasp attachment, as described on page 220.

FIG. 429.

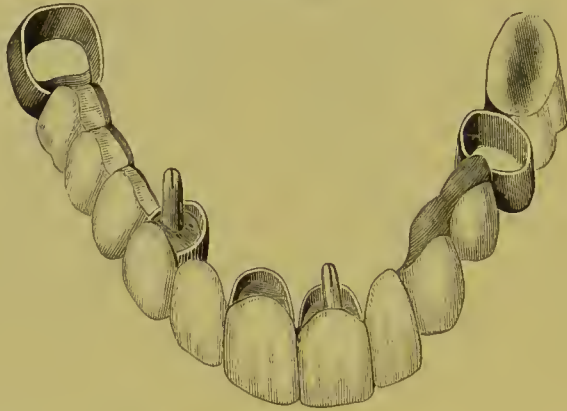


In the case represented in Fig. 429, gold crowns with removable partial cap and collar attachments are made for the molar and bicuspid, and removable crowns with flanges of the metal on the palatal sides for the centrals and cuspid. The right central is capped and the crown fitted over it without a post, as the posts in the other two crowns afford ample security.

After the crowns are made, the root-caps are cemented on each root. The central crowns are cemented together with wax, adjusted in position, covered with a small quantity of investing material, removed, more investing material added, and the crowns soldered together.

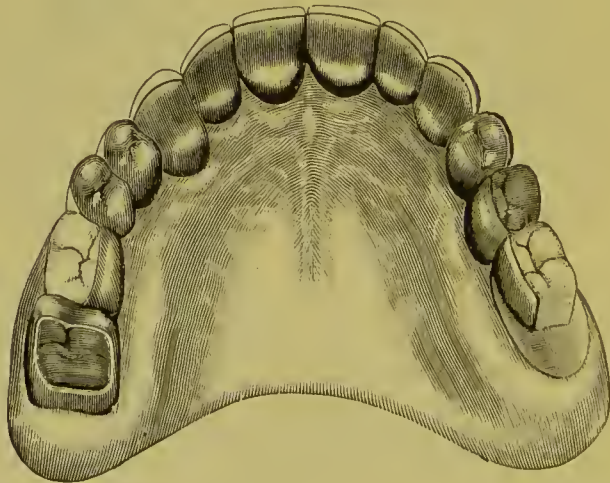The centrals and the cuspid are then adjusted in the mouth, a lateral is backed, fitted, and waxed between them in position, the whole removed in investing material, and the process of investing and soldering proceeded with to join the parts as

FIG. 430.



before described. This bridge of four teeth is fitted to the mouth, and the points of the posts trimmed on the side and in the direction which will best favor their entrance into the tubes in each root, so that the bridge will readily slip into position.

FIG.



The dummy bicuspid and molar on the right side between the cuspid and molar are then added by first taking an impression and bite of that section, and then proceeding with the construction as described in previous cases. The section of the bridge with the extension on the left side is next added in a similar

manner by taking an impression of the part while the portion of the bridge already constructed is in position, removing bridge and impression together, and making a model. A piece of pure gold is shaped to the model by alternately burnishing and annealing, to form a base for the molar. The one molar will exert as much leverage on the abutment of the bridge in mastication as can safely be borne.

Fig. 430 shows the bridge completed, and Fig. 431 the piece in position.

## CHAPTER XI.

### REMOVABLE PLATE BRIDGES.

IN this style of bridge a plate is used to span the space and support the artificial teeth between the abutments. An essential requisite of this class of dentures is that the plate portion shall rest closely and firmly on the alveolar border, and at the same time receive support from the abutments. Attachments similar to those used in connection with removable bridge-work are also applicable to removable plate bridges. The methods to be given describing their application will differ in some respects, which will be advantageous in a practical way.

FIG. 432.

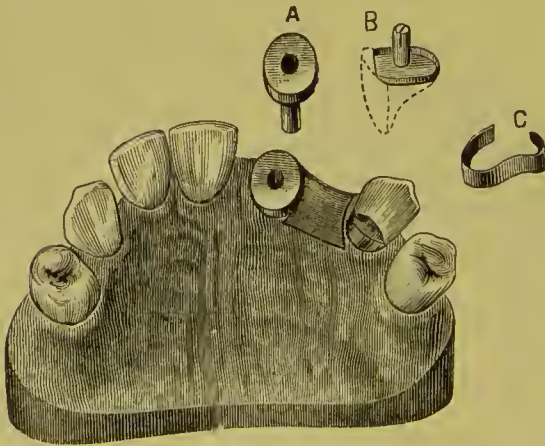
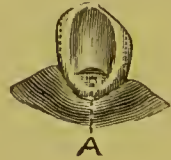

FIG. 433.



The case shown in Fig. 432 will be taken to describe the constructive details of a denture of this class. In the root of the central a tube is inserted, attached to a cap on the end of the root. Over this cap is placed an outer cap which has a split spring pivot or post fitting the tube. A narrow plate between the teeth connects the outer cap to a clasp attachment which fits around and rests upon the cuspid.

The cuspid, which because of its conical form is one of the most difficult teeth in the mouth to clasp, is trimmed sufficiently to partially square its approximal sides, and the palatal portion is notched slightly (A, Fig. 433), to form a shoulder for the clasp to rest upon. This notch can be safely made, as the enamel is very dense at the point indicated.

A gold plate is swaged to fill the space between the central root and the cuspid as shown in Fig. 432. The cap and pivot are adjusted on the central root, and the plate is then fitted in the mouth, pressed tightly in position against the gum, and retained there with a little wax, which is cemented to the plate and pressed against the cuspid and side of the cap. An impression of the parts and an articulation are then taken in plaster. The cap, pivot, and plate being removed in the impression, they will be presented on the model made from it in exactly the same position as in the mouth. A second or outer cap is then fitted over the root-cap, the band being made very narrow at the approximal and palatal sides, and open at the labial side, as the porcelain tooth to be attached will serve in its stead (B). The pin is then soldered fast in the outer cap, and a clasp of clasp gold (C), No. 23 to No. 24 gauge, is formed to extend well around the posterior approximal portion of the cuspid. The outer cap having been placed in position on the inner one, the plate extending from the central to the cuspid is cemented to it and to the clasp with wax, removed, invested, and the parts soldered together. Aided by the plaster articulation, teeth are ground and fitted on the model, backed, attached to the plate with wax, and inserted in the mouth. Platinum foil is then burnished to the form of the notch on the cuspid, the clasp fitted over it and attached with wax, removed with the plate, and soldered to it simultaneously with the teeth.

When the piece is finished and fitted in the mouth, the inner cap—the end of the tube having been closed with gutta-percha—is first cemented on the central root. A very small quantity of oxyphosphate is used, and while it is yet soft the plate is adjusted in position, and allowed to remain there until the cement has set. The split pivot is sprung open a little and forced to place. With the aid of the clasp around the cuspid it

will be found to perfectly secure the plate. Figs. 434 and 435 show the bridge finished and in position. If the plate forming the bridge is tightly adjusted against the soft tissues, and removed in that position in the impression taken with the caps, it will always be found to fit in a similar manner when the bridge is finished. Should the clasp cause decay or abrasion of the cuspid, the tooth can be excavated to a slight depth under the clasp, and filled with gold. This is best done by making a few retaining-

FIG. 434.

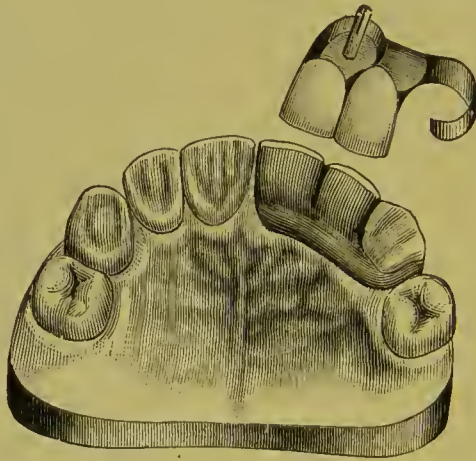
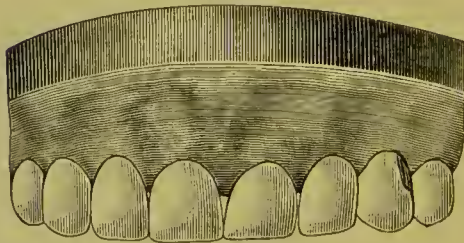


FIG. 435.



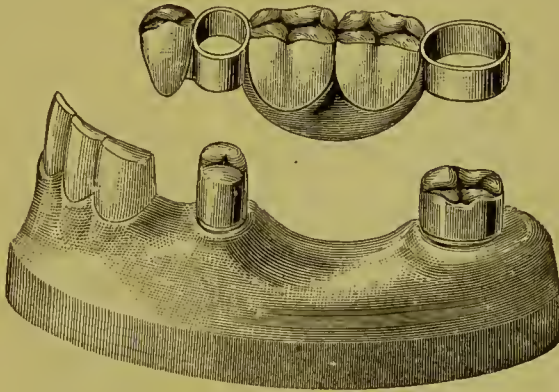
pits, filling them with a hand-plugger, and then inserting the main body of the gold in the ordinary manner, the Herbst method being useful in condensing the foil. Such a filling inserted at any time will prevent injury from a clasp. A denture of this style can be made to pass intervening teeth.

In the artificial replacement of the lower teeth in a case such as is illustrated in Fig. 436, a plate bridge possesses many advantages. In the construction of such a denture, the teeth are first properly shaped. Gold crowns (Fig. 437), with sides as nearly



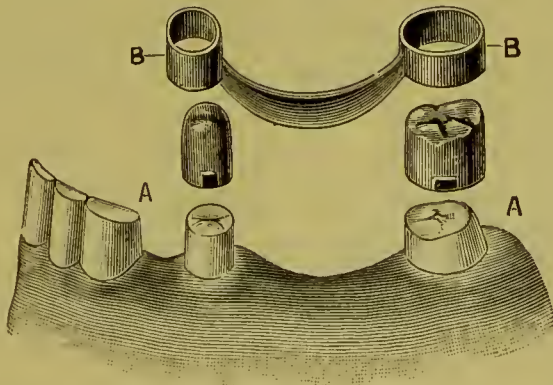
as possible parallel the one with the other, are then made and fitted to the bicuspid and molar. This operation is frequently facilitated by shaping the external surface of the crown with metal. On the crowns, at the buccal sides, a narrow shoulder (A) is constructed to sustain the collars and bridge in position. In some

FIG. 436.



cases this shoulder is placed on the approximal side to better advantage. The crowns are then adjusted in the mouth, a small quantity of wax being applied inside of the crowns when necessary to retain them in correct position. A piece of plate is next

FIG. 437.

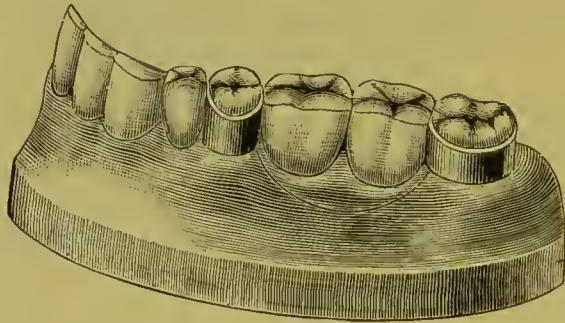


swaged and fitted between the crowns and attached with wax as described in the previous case. An impression and articulation of that part of the mouth are then taken with plaster and the crowns and plate removed in it. On the model made from this impression the crowns and plate will appear in position. Collars

reaching from the cervical to the occluding edge are fitted to these crowns.

The collars, though fitting accurately, should move easily over the crowns, as they can be readily tightened when the case is finished. If the collar is troublesome to adjust and remove, cut the side opposite to that attached to the plate, and spring it open a little. After fitting the teeth it can be again united when they are being soldered. This collar and shoulder form a support in some respects preferable to a partial or an entire double cap, being less difficult to keep clean. A collar is more easily constructed, and also permits the position of the bridge to be altered by the removal of a little of the shoulder or of the upper edge of the collar, and is a secure but less rigid attachment than is provided by other methods.

FIG. 438.

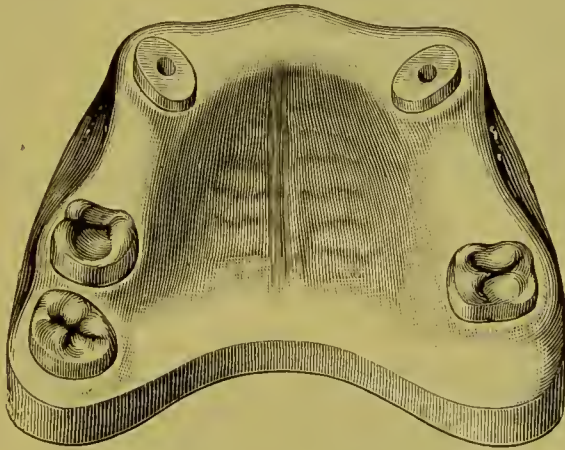


The collars and plate are next cemented with wax, removed, invested, and strongly soldered together (B, B, Fig. 437). The artificial teeth are fitted in proper position on the plate by the aid of a plaster articulation, attached with wax, and, if preferred, the piece may be adjusted in the mouth without the gold crowns. The bridge is then invested and finished.

The attachment of the artificial teeth to a plate of this kind can be of either gold or rubber. Whichever is adopted, the first bicuspid is best supported by being soldered to the collar. If iridio-platinum is used in the construction instead of gold plate, and the soldering done with pure gold, porcelain body can be used. When ready to be inserted, the crowns are adjusted with cement, and then the bridge, which is left in position until the cement sets. By burnishing the collars they can be made to clasp the crowns as firmly as desired. Fig. 438 shows the denture in position.

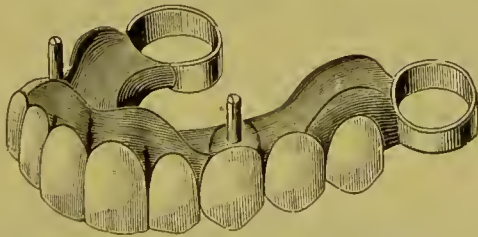
Figs. 439 and 440 represent an upper removable plate bridge. In its construction the cuspid roots were first capped, tubed, and pivoted, and the molars crowned, with shoulders formed on the buccal sides. The plate intended to connect the abutments was then adjusted in position as has been described. An impression was next taken and a model and articulation made. The cuspids were then double-capped and collars formed on the molar crowns.

FIG. 439.



The double caps, pivots, collars, and plate were next soldered together. The artificial teeth were attached with vulcanite, the gum section being formed with pink. In order to avoid any warping, which might readily occur in the construction of so large a denture as this, the plate may at first be swaged up,

FIG. 440.



as in ordinary artificial dentures, to cover the entire hard palate. A shallow groove can be made around the palatal surfaces of the teeth, and after the final soldering the plate can be cut along the line of this groove, the portion covering the palate being removed. The groove will insure a close fit for the palatal edge of the plate.

In the case represented in Fig. 441 the natural teeth were very short. The posterior approximal side of the molar was

FIG. 441.

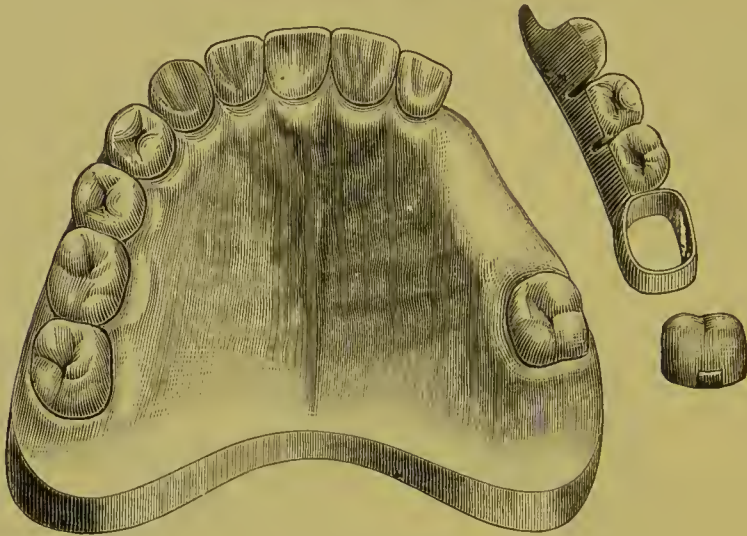

FIG. 442.

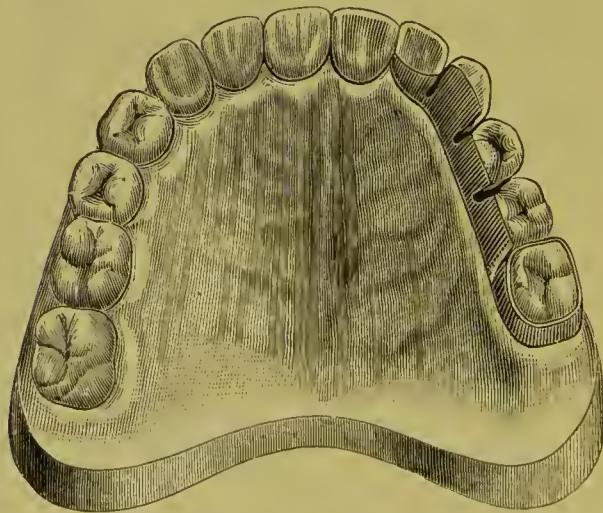
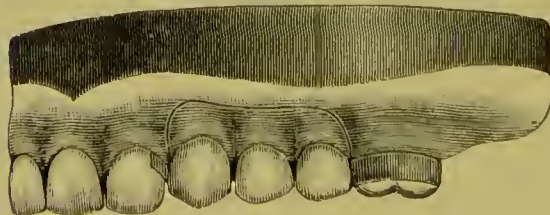


FIG. 443.



decayed to such an extent that the pulp was nearly exposed, and considerable irritation of the investing gum-tissue had been

caused by the clasp of a plate worn by the patient working upward against it. The patient declined to have a plate made which would extend across the palate. The lateral was hardly strong enough to support a permanent bridge. The molar was capped, and a removable appliance constructed with a band which slipped over the cap and rested on a shoulder on the mesial side to form the posterior abutment. The lateral was notched and clasped for the anterior support. Figs. 442 and 443 are two views of the appliance in position.

FIG. 444.

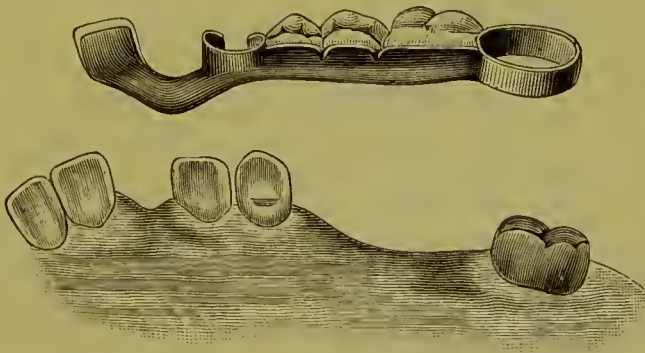


FIG. 445.

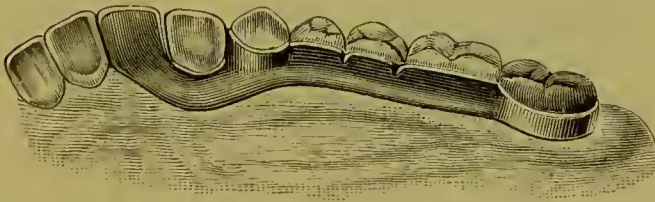


Fig. 444 represents a case in which the bicuspids and a molar are replaced, and also a central, on an extension of the plate, the cuspid being partly encircled by a clasp with a shoulder resting on the palatal section of the tooth. Fig. 445 shows the denture in position.

Fig. 446 represents a case in which a bridge-plate was inserted without crowning either of the abutments. The clasp of a plate which had been worn for some years had worked upward and abraded the distal section of the cuspid to such an extent as to expose a large portion of the root and superinduce decay. The cavity was filled with gold, and the gingival border, by

treatment, brought nearly to its normal position on the tooth. A plate bridge, such as is represented in Figs. 447 and 448, was then constructed. Clasps, with flanges resting on little shoulders formed at A, A, Fig. 446, support and retain it. A flange such as was used in this case is best made subsequent to the construction of the plate and clasps, by burnishing a piece of platinum foil in the mouth to the form of the shoulder and the side of the tooth upon which it is to rest, adjusting the elasp

FIG. 446.

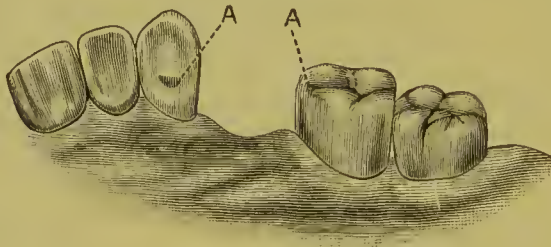


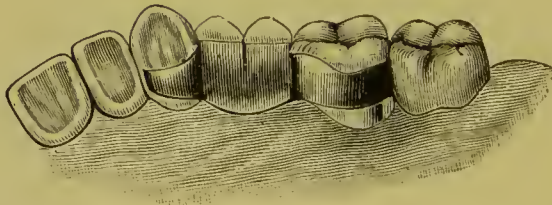
FIG. 447.



FIG. 448.

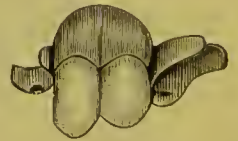

FIG. 449.



over it, and cementing with wax, then removing, investing, and soldering. Wherever the platinum is placed, the solder will flow and fill all the space between it and the clasp. This gives the elasp the exact form of the tooth.

Fig. 449 shows the denture finished and in position. If the teeth are dense in structure, an attachment of metal held in proper position against the lower portion of a crown will be worn a long while before it causes injury to the parts. Filling, or crowning, if necessary, can be resorted to subsequently.

By a correct application of the methods just explained and

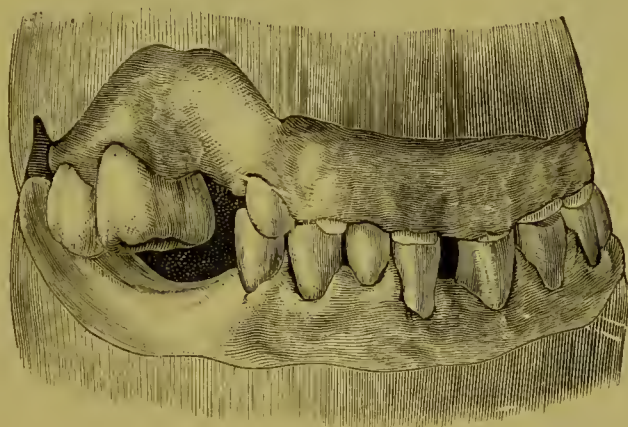
illustrated, a piece of removable bridge-work of this style can be devised for many cases.

Dr. J. L. Davenport describes the methods he adopted in the application of plate bridges to the following case :

“The patient was a gentleman about fifty-five years of age. The upper jaw contained the six front teeth, the three molars on the right side, and the first bicuspid on the left. The lower jaw contained all but the left central incisor, the second bicuspid, the three molars on the right side, and the first and third molars of the left.

“In consequence of this lack of occluding back teeth, mastication had been performed solely by the front teeth, causing attri-

FIG. 450.



tion so great on the upper ones as to entirely obliterate their crowns, while the lower ones suffered but little loss, as will be seen by reference to Fig. 450.

“The patient had managed for a long time to masticate, though imperfectly, upon these stumps, but latterly could eat scarcely anything but soups and soft foods.

“The restoration of the lower teeth being completed to the extent of about one-eighth of an inch on an average, to make them of uniform height, my attention was directed to the upper incisors and cuspids, nearly all of which I found with dead pulps, and some of them in a condition of active abscess.

“The two superior cuspid roots were dressed down nearly to the gum, and fitted with 22-carat gold cap-crowns. After these

had been placed in position, a hole was drilled through each cap of a size suited to that of the pulp-canal, and a tube of iridium and platinum was adjusted in the root and cap and waxed in position. The cap and tube were then taken off and soldered, great care being taken to have the tubes enter both roots perfectly parallel. These were permanently secured in the roots with gutta-percha, and to prevent the caps being pulled off the top of each tube was slit down a trifle, and after insertion was bent back into the gutta-percha with a warm instrument.

“The incisor roots having been dressed down even with the gum and filled, a plaster cast was taken and a narrow 20-carat gold plate was swaged to fit over the ends of the incisors and the capped cuspids, making it a little broader where it had to rest on the gum back of the first left bicuspid root. A hole in the plate was then made to expose the root of the first left bicuspid. This was fitted with a bifurcated iridio-platinum pin, having notched sides and a hammered head upon its lower end, which came down below the root about three-eighths of an inch.

“A thin iridio-platinum band was then made to encircle the root, passing just under the gum and being slightly longer than the headed pin. This band was perforated with two rows of holes, from without inward, giving the inner surface a roughness similar to that of a nutmeg-grater. The band and pin were then made secure to the root with a non-shrinkable copper amalgam.

“Fig. 451 shows the upper jaw ready for the plate.

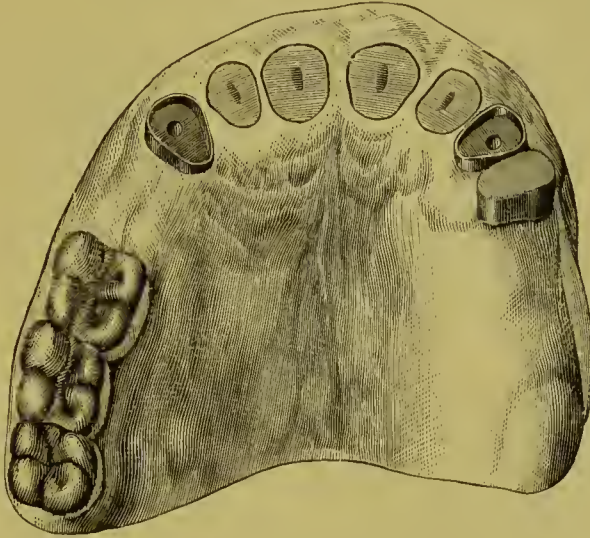“After the amalgam had become hard and the end and sides had been polished, a gold crown was fitted over all just up to the margin of the gum, and in close contact with the end of the band and amalgam. This crown was loose enough to admit of its sliding on and off, though with just enough friction to hold it in place when at rest. This gold crown was then placed in position, the plate also inserted, and hard wax used to firmly join the two in the mouth. They were then removed and soldered.

“Gold pins were then placed through holes drilled in the plate into the tubed cuspids; then soldered to the plate, the pins being of a size to fit the tubes accurately. The plate was also provided with a wide clasp encircling the first molar on the right.



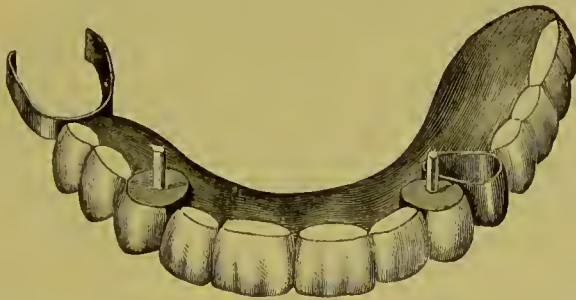
“The plate was then provided with a gold bar about one-eighth of an inch wide, occluding perfectly with the lower teeth, and plain teeth soldered in place, hiding the bar, and just meeting the gum in front of the incisor roots. The plate rested squarely

FIG. 451.



against the capped cuspid, each of which showed a narrow band of gold when the plate was in position. As finally completed (see Fig. 452), this was the most perfectly fitting piece I ever inserted, requiring great care in its removal, and yet by a little practice the gentleman was able to remove and replace it quite

FIG. 452.



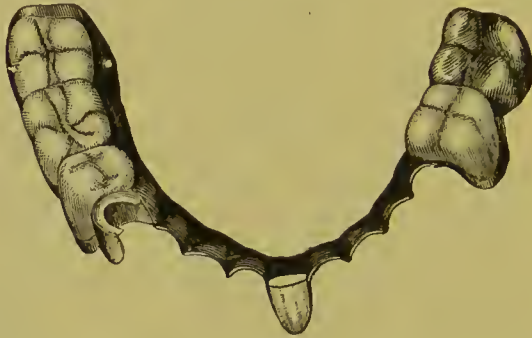
easily. It was also as firm as any permanent bridge could have been, though it had no support on the left side back of the first bicuspid.

“The lower jaw was supplied with a double 20-carat gold plate, having a wide clasp on the first right bicuspid, which, after being

built up, presented a cone-shaped top, about which the clasp fitted so as to rest firmly upon the end of the tooth, thus preventing injury to the gum during mastication.

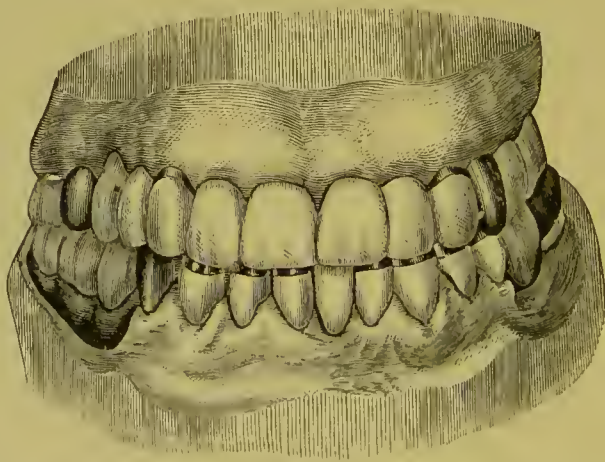
“The only other peculiarity was that the second left inferior molar, being abnormally short, though well formed and standing

FIG. 453.



straight upright, was fitted with a wide clasp, extending almost one-eighth of an inch about the tooth, and a piece of gold plate with gold cusps was soldered into this clasp, covering the molar crown and occluding with the molar on the upper plate (see Fig. 453). This not only prevented the plate from being bitten

FIG. 454.



down unpleasantly on the gums during mastication, but enabled me to use a shorter molar upon the upper than I otherwise could have done, and allowed better the antero-posterior and lateral movements of the jaws.

“Fig. 454 shows the case as completed.”

## CHAPTER XII.

### SPECIAL FORMS OF DETACHABLE AND REMOVABLE BRIDGE-WORK.

A DESCRIPTION of special forms and methods of constructing detachable and removable bridge-work is given in the following pages, as practiced by the introducers or as adopted in general practice.

#### DR. WINDER'S SECTIONAL CROWN METHOD.

This method presents the novel feature of constructing the crowns and forming the abutments in sections, the bridge being attached to the detachable section.

FIG. 455.

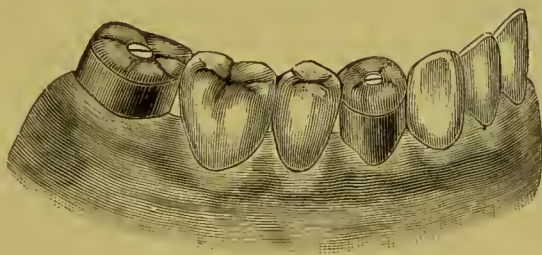
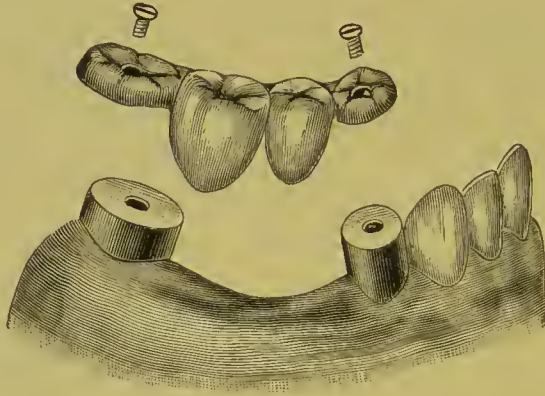


Fig. 455 illustrates a case of bridge-work made in this manner. The collar section of the artificial crown is capped and cemented on the natural crown or root, the gold forming the occluding portion of the crown, when the bridge is adjusted in position, being secured to it with a screw. The screw may be made to enter the body of the crown as in Fig. 456, or it may be soldered to the cap on the collar, passing through the occluding section of the crown, and being secured by nuts on the screws (Fig. 457).

In constructing a bridge of this style, the crowns forming the abutments having first been made, are removed from the mouth

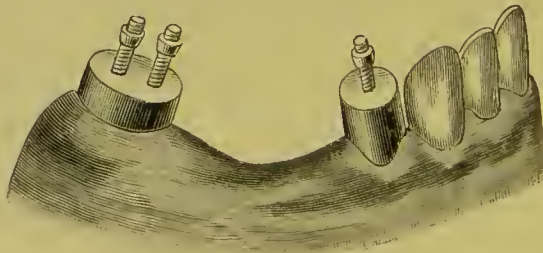
in a plaster impression and articulation, from which a model is made, showing the crowns in position. Each section of the bridge between the crowns is then constructed, and the crowns adjusted in the mouth. The bridges are next inserted in position, and cemented with resin and wax to the detachable sections

FIG. 456.



of the crowns. The whole is then removed in investing material, in an impression-cup, or by placing the investing material in position on the bridge. After being removed from the mouth more investing material is added and the bridge and crown sections soldered together. Only the detachable sections of the crowns should be in the investment at the time of soldering.

FIG. 457.



The incisive edges can be protected and the occluding surfaces of the porcelain capped with gold as in permanently attached bridge-work, or they can be formed of the porcelain, which latter lessens the labor of construction, as the bridge is easily detached from the abutments for the purpose of repair. When the

occluding surfaces of bicuspid or molars forming the bridge are to be capped with gold, the collar sections alone are first made and removed in the impression. The caps for the crowns and the bridge teeth are then formed of one continuous piece of gold plate. This is made by laying the strip of gold on a piece of lead and stamping along its length with suitable dies representing the occluding surfaces of the different teeth. The gold is then properly fitted to the collar sections on the model, conforming to the occlusion of the antagonizing teeth.<sup>1</sup> The cusps are filled with solder, and the porcelain fronts, backed with platinum plate, are fitted in position to the gold forming the caps and the backings, cemented with wax, removed, invested, and soldered to the caps. When the bridge is finished the root and collar section of each crown is first cemented on in position in the mouth; the surface of the detachable section of the crown approximating the section fastened to the bridge is then heated and the surface covered with a mere film of gutta-percha. The bridge is then adjusted in position and secured by the screws or nuts. The gutta-percha prevents the secretions invading the interstices between the sections of the crown.

FIG. 458.

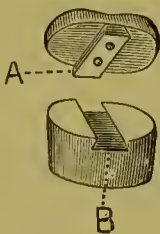


FIG. 459.

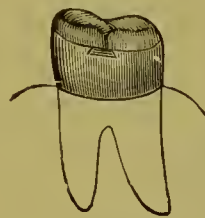


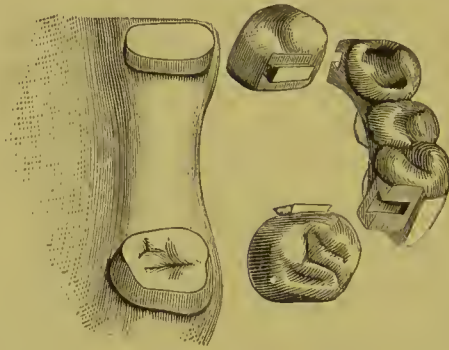
Fig. 458 illustrates another method, devised by Dr. W. R. Spencer, of constructing the sections of the crowns in this style of bridge-work. The part A slides in the groove B. The dove-tail flange A is made of a thick piece of plate, fitted to the groove B, and riveted to a piece of platinum adapted transversely across the cap and then soldered to the removable section of the crown. Fig. 459 shows the section of the crown in position.

<sup>1</sup> In the Hollingsworth System will be found another method of constructing the grinding-surfaces of a number of crowns and dummies of one piece of plate.

Fig. 460 illustrates a bridge made by Dr. C. L. Alexander, in which dovetail slides are placed on the sides of the crowns.

In either of these forms gutta-percha can be used to securely attach the bridge so that it shall be detachable only by the dentist.

FIG. 460.



An advantage possessed by these styles of bridge-work is the facility they afford for the ready utilization of irregular teeth as abutments, no matter how much they converge or diverge, or lean in and out of the line of the arch.

#### DR. LITCH'S METHOD.

Dr. Litch's method of constructing detachable bridge-work consists in forming a shell anchorage over posts permanently fixed in cuspid roots, and anchoring the ends of the bridge with bars in slots formed in natural or artificial crowns.

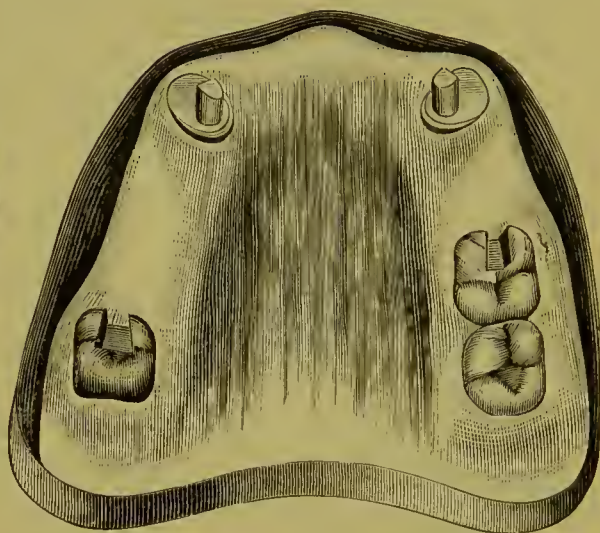
Figs. 461, 462, and 463 illustrate a bridge similar to the one illustrated in Fig. 285 (page 157) with this style of attachment applied. The anchorage for the cuspids is constructed as follows: The root is first capped and pivoted as for a collar crown. On the palatal portion of the collar is soldered a flange (A, Fig. 464) made of gold, No. 16 U. S. standard gauge, beveled off to the upper edge of the collar under the free edge of the gum, the object being to give a larger surface to the top of the cap. On this cap, which covers the end of the root, the anchorage post B, which is formed of iridio-platinum wire, No. 9 U. S. standard gauge, is soldered, over and back of the pin (C) which enters the root-canal, so as to allow room for the porcelain front D. The porcelain front is ground in proper position on this cap, backed, attached with resin and wax, and removed with the cap.

The cap is next invested in plaster to the edge of the collar, and a little plaster placed on the labial aspect of the porcelain front in the form of a matrix, so as to allow the porcelain to be

FIG. 461.

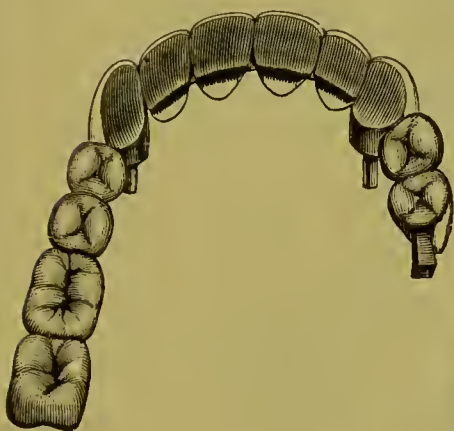

FIG. 462.



removed and replaced. A piece of heavy iridio-platinum plate (E), No. 16 U. S. standard gauge, is then shaped into the form of a half-ring, with the ends of the plate against the backing of

FIG. 463.

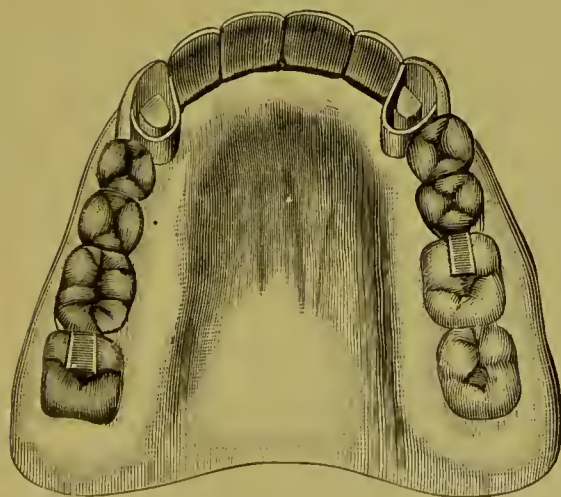
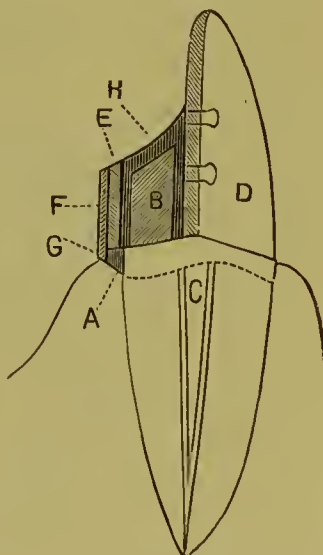


FIG. 464.



the porcelain front, and of sufficient size to rest on the flanged edge of the cap when completed. On the outside of this half-

ring is fitted and soldered a thin strip of gold (F) of No. 28 U. S. standard gauge, which will cover the half-ring and extend beyond its cervical margin, slightly overlapping the flange of the collar (G). This forms a brace or edge on the anchorage cap as it rests on the root-cap. The half-ring is then fitted to the tooth, attached with wax, and removed with the tooth out of the plaster matrix from the root-cap, invested, and securely soldered on the inside to the backing of the tooth. The tooth and half-ring are then adjusted to the root-cap, over the post of which the ring must slide easily (Fig. 465). To this ring the bridge is soldered the same as to a crown.



When the bridge is inserted, the cap for the root, with the post, is first cemented on with oxyphosphate. After the cement has set, the anchorage ring is filled with more cement and pressed into position upon the cap over the anchorage post. The surface of the cement (H, Fig. 464) can be protected by a metallic filling.

This form of attachment permits the bridge to be easily removed by affording access to the cement around the pin. The bar ends of the bridge are anchored in the crowns with gold or amalgam fillings, which likewise are not difficult to remove.

The anchorage cavity for a bar in a gold molar crown for use over a tooth with a living pulp is best made by cutting out the gold to the form of the slot required, and inserting in its place a piece of platinum of the shape of the walls of the anchorage cavity. The crown is then filled with investing material, and the metal forming the anchorage cavity soldered to the crown at the edges of the cavity.

#### DR. R. W. STARR'S METHODS.

Dr. R. Walter Starr gives the following descriptions of his methods in detachable bridge-work:

“The case of Mr. W. presented difficulties of an unusual character, as may be seen by inspecting the illustration (Fig. 466), which renders detailed description unnecessary.

“It will be observed that the molars and the left second bicuspid overhang to a degree that would make the taking of an accurate



FIG. 466.

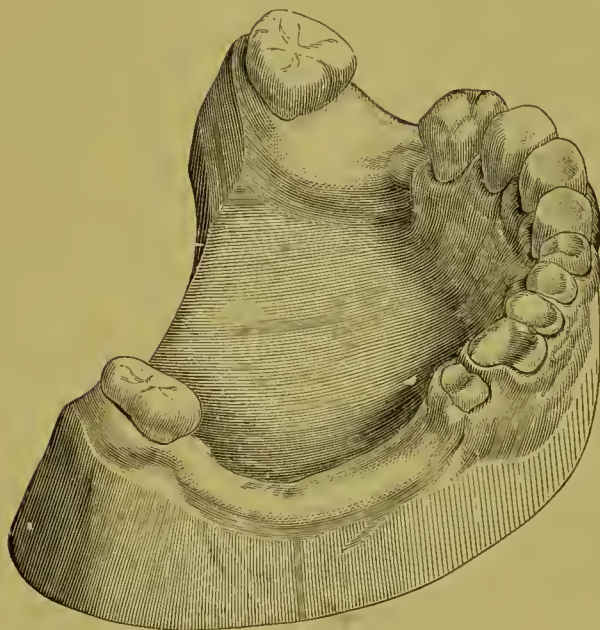
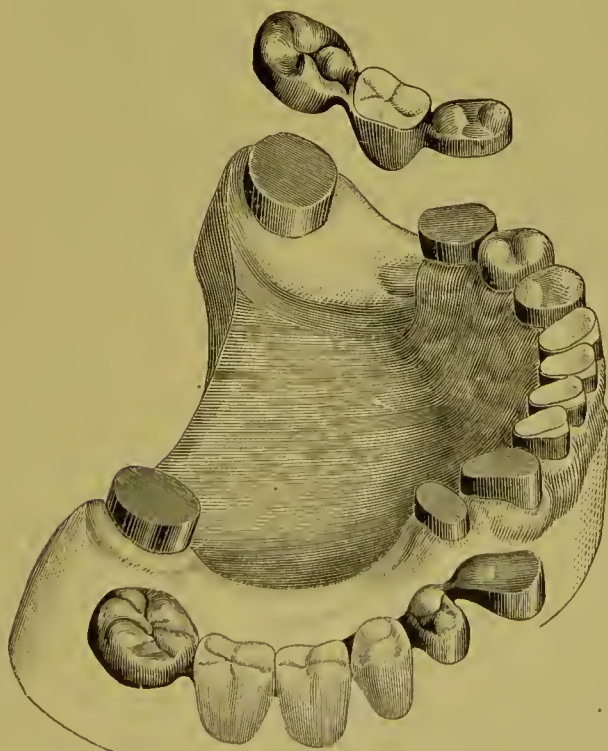
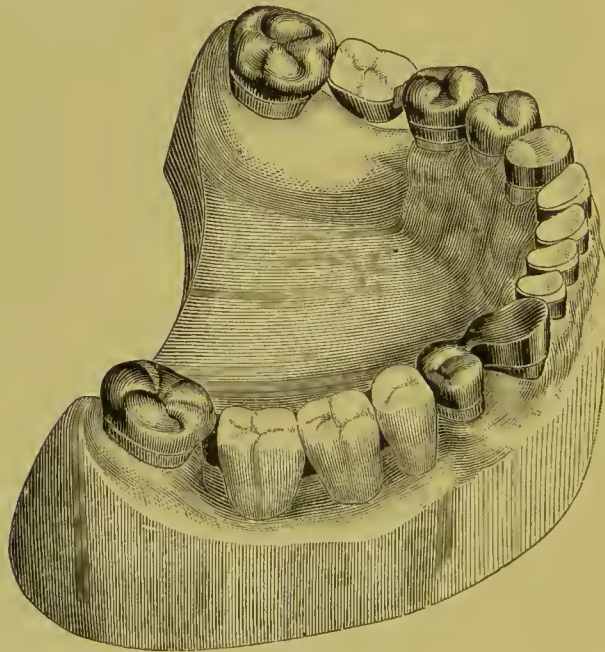


FIG. 467.



impression by ordinary methods well-nigh impossible. After a careful study of the case, it was decided that two separate pieces of detachable bridge-work should be attempted, and, as an essential preliminary step, the overhanging sides of the molars and bicuspids were ground with engine corundum-wheels and points until those sides were made much less inclined, when plaster impressions were taken, first of one half, and then of the other half, of the jaw. Gold cap-crowns were closely fitted over the molars, left second bicuspid, right first bicuspid, and cuspid stump. Gold crowns were made to telescope over all the caps, which were then, by means of oxyphosphate cement, fixed

FIG. 468.



firmly on the teeth. Suitable plate teeth were selected, fitted, backed, and hard-waxed in place between the telescoping crowns. After hardening the wax with cold water from a tooth-syringe, the pieces were carefully removed, invested, and soldered. The two completed bridges were easily replaced on or removed from the supporting capped teeth, and their appearance when detached is correctly shown by the illustration, Fig. 467, which also shows the capped teeth and stumps. The figure likewise shows the results of the novel method employed in crown-

ing the incisors. Gold collars were fitted tight on the necks of the incisor stumps, and the porcelain caps adjusted in the collars, and set in the oxyphosphate cement which had been packed into the collars; thus at the same time fastening the collars on the stumps and the caps in the collars, as shown completed in Figs. 467 and 468.

“ Fig. 468 illustrates the finished crowns and bridges, which latter were secured in position by placing a small piece of gutta-percha in each of the telescoping cap-crowns, which were then warmed and carefully pressed in place,—the gutta-percha filling only the spaces between the flat tops of the caps of the natural teeth and cusped caps of the bridges.

“ Whenever, for repair or for any other purpose, it shall become desirable to remove one of the bridges, that may readily be done by applying a hot instrument or hot air to the caps to soften the gutta-percha sufficiently to permit the telescoping bridge to be taken off.

“ A full upper vulcanite denture was made to replace the old one, which, by improper occlusion, had thrown the full force of mastication on the anterior teeth of the lower jaw, and produced the destructive action that resulted in the deplorable loss of tooth-substance shown in Fig. 466.”<sup>1</sup>

The next case also presented unusual difficulties. “The forward overhang of the inferior right second molar was so excessive that an impression could hardly be taken, until with corundum-wheels and points the sides of the tooth had been made parallel, or rather slightly tapering to form a truncated cone, with the neck as a base. The molar was alive and sound, but the crown was gone from the pulpless cuspid, which I suitably shaped by means of my root-trimmers (Fig. 469).

“ An impression was then taken, the cast from which is illustrated by Fig. 470. A seamless gold collar was, by means of a slightly tapering mandrel, made to exactly fit the tapered natural molar, the lower edge of the collar cut to conform to the gingival margin; a cap piece of gold plate soldered to the top edge of the collar, and a hole drilled through the center of the completed cap (A). Care was taken to so fit and proportion the cap

---

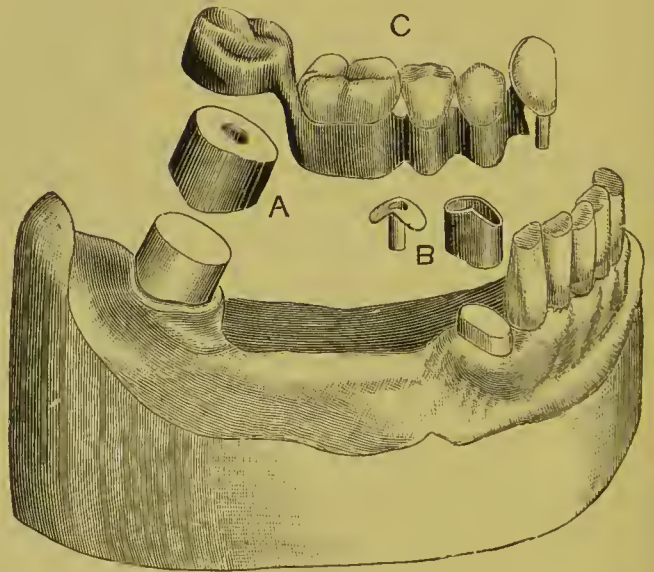
<sup>1</sup> *Dental Cosmos*, vol. xxviii, No. 1, page 17.

that it would require finally pretty hard driving to send it home on the tooth; but first there was fitted to the cap a telescoping seamless collar, on which was soldered a gold plate, with cusps, to form a molar crown as shown. The molar was then thoroughly dried, slightly painted with Agate cement, and the cap, A, driven hard down with a flat pine stick held upon it and struck with a mallet; the hole in the cap enabling me to see when the cap was quite down. The cuspid was then likewise fitted with a seamless gold collar, the top edge of which was given a roof-shape, as seen above the root in Fig. 470. A piece of gold received a corresponding roof-shape, had a short section of gold tubing soldered into it, and was trimmed to the outline of the collar,

FIG. 469.



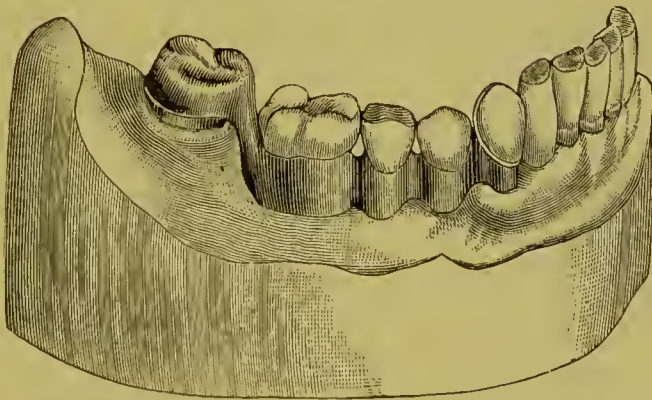
FIG. 470.



beside which, B, its form is seen, and to which it was subsequently soldered, after suitable investment to keep the parts in proper place. The root-canal had been previously prepared to receive the tube, which, with its roofed cap, was with stick and mallet driven hard down over the root. A piece of gold wire exactly fitting the tube had a roof-shaped piece of properly perforated gold plate slipped over it into position on the root; became fixed in such relation by a drop of melted hard wax: was removed, invested, soldered, and finished in such shape that, excepting the hollowness, it looked like the tube and cap B.

The relations of the occluding teeth had, of course, been determined by an articulating model, and by means of it a series of seamless gold collars and cusp-crowns were adjusted on a thin platinum plate fitted on the cast between the cuspid and second molar, and the collars soldered to the plate after investment. The truss thus formed received an appropriate finish by the rounding and smoothing of its basal borders. A plain plate cuspid was backed with gold plate and fitted on the roof-plate, to which, after determining its proper occlusion, it was secured by hard wax; removed, invested, and soldered. It was then put into the tube on the root; the telescoping cap put over the molar; the truss put in position in the mouth, and the whole covered with plaster and marble-dust, contained in a suitable sectional

FIG. 471.

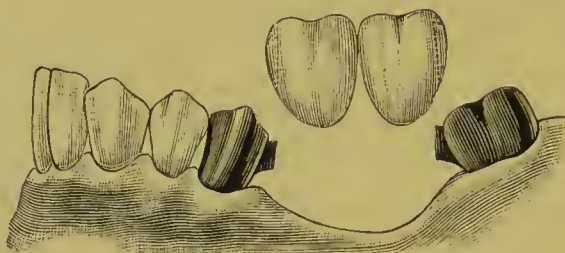


impression-tray, which enabled me to hold the mass steadily in place until the mixture was sufficiently hard to bring away cap and truss and roof-plate all in proper position. A second mixture of plaster and marble-dust, and a suitable trimming of the first mixture after all was hard, sufficed for the soldering process that resulted in the denture which, when finished, appeared as shown detached at C, Fig. 470, and mounted on the cast in Fig. 471. It went firmly to place in the mouth, and yet was removable in the possible event of accident to the denture, or for readjustment of the cusp-crowns, which latter could easily be done by warming the piece sufficiently to soften the gutta-percha, replacing the denture on its anchorages, and directing the proper closure of the occluding teeth."

## DR. PARR'S METHODS.

*Detachable.*—Fig. 472 illustrates a method of this style. The teeth forming the abutments lean toward each other posteriorly and anteriorly over the space to be bridged, as shown on the

FIG. 472.



original model, Fig. 473. The bridge is supported by two shoulders on the abutment crowns, which slide into grooves in the dummies (Fig. 474). These supporting shoulders and slots are made by shaping two pieces of platinum plate to the form shown in Fig. 475, so that one shall telescope the other. The inner one is then invested on the outside surface and filled in with gold plate. The outer piece is then filled inside with investing material, and gold plate is flowed over the outer surface. The shoulders are first soldered to the crowns, and afterward the slots are adjusted to them and soldered in position in the bridge.

FIG. 473.

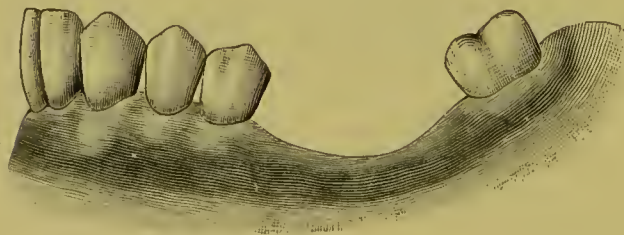


FIG. 474.



FIG. 475.



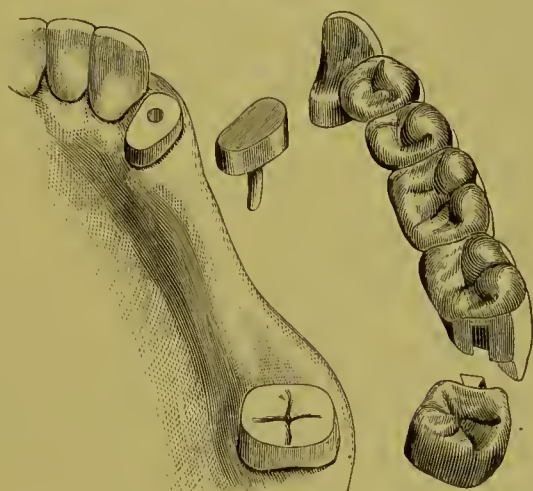
Fig. 476 shows a bridge constructed with the attachment described at one end and a double cap attachment at the other.<sup>1</sup>

*Removable Bridge.*—In this style the crowns forming the abutments are permanently cemented in position, each section of the bridge between them being removable. The case illustrated in

<sup>1</sup> Case of Dr. C. L. Alexander, described page 27, *Dental Cosmos*, vol. xxxiii.

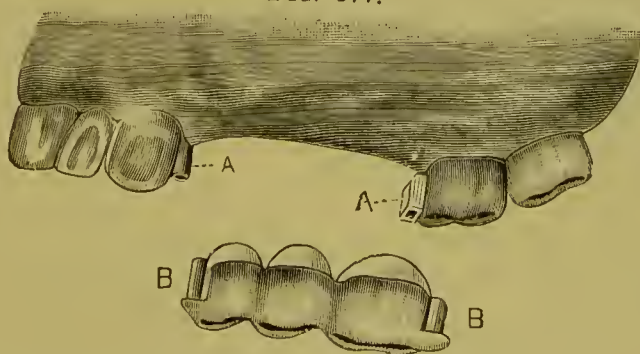
Fig. 477 will serve as a type to give the constructive details. The cuspid and molar crowns are first formed in the usual manner. A model from an impression is then made, on which the crowns will appear in the same position as in the mouth. A gold

FIG. 476.



and platinum bar (A, Fig. 478) is then formed between the cuspid and molar. The end for the cuspid is rounded, and that for the molar flattened. This last may be done by hammering the wire flat or by soldering a piece of clasp plate transversely

FIG. 477.



to it. The two ends of the bar are then fitted in sockets of platinum (B, B). The ends of the bar should be bent and the platinum sockets placed in such a position against the sides of the crowns that the bar can be easily adjusted and removed. The sockets are next soldered to the sides of the cuspid and

molar crowns (A, A, Fig. 477), for which purpose the sockets and crowns should be removed and invested. The sockets are held in position when the wax is melted out by pieces of iron wire, one end of which, covered with a portion of the investing material, is inserted in the socket, the other end being imbedded in the investment. If preferred, the slot on the side of the molar crown can be made with a piece of platinum adapted over the flat piece of gold forming the end of the bar, and then

FIG. 478.



soldering the platinum to the side of the crown, the platinum being stiffened by flowing the solder over it. At this point the crowns and bar may be adjusted in the mouth, as well as on the model, to insure accuracy. A piece of thin platinum or gold is then perforated and slipped over the ends of the bar, which is placed in position on the crowns, and the platinum or gold adapted to the form of the attachments, and to the immediately adjacent surfaces of the crowns. These shell forms are made to

FIG. 479.

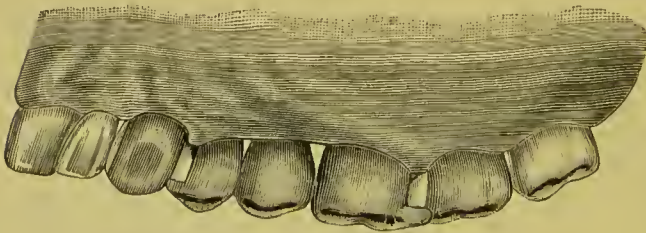
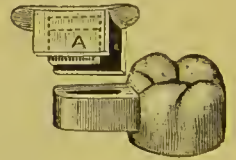


FIG. 480.



assure to the ends of the bridge a perfect fit by giving them the shape of the crowns and the attachments on the crowns. To this bar the teeth constituting the bridge are fitted in their respective positions and soldered. Bending either end of the bar slightly (B, B, Fig. 477), or sawing a slit in the cuspid end of it (Fig. 407), affords the means of holding the bridge firmly in position, although it may be removed and reinserted at the option of its wearer. Fig. 479 shows the inserted bridge.

Fig. 480 shows another method of forming a socket attach-



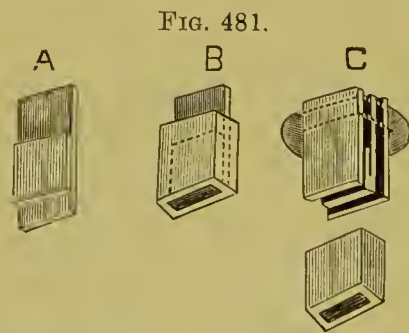
ment. In the figure, the socket section of the attachment is seen projecting from the side of the molar crown. The other section consists of a cap having a spring flange. The flange enters the socket, which the cap incloses on the top and at the sides. The spring is made by bending open a little the part of the flange marked A.

This form of attachment is constructed as follows: To make the *spring flange*, two pieces of clasp or spring gold plate about No. 23 U. S. standard gauge, one of them one-half and the other one-fourth of an inch long and from one-eighth to one-quarter of an inch wide, the exact dimensions being governed by the case in hand, are laid together, so that one end of the short piece is nearer one end of the larger piece than the other. The edge of the short piece nearest the end of the longer one is then soldered to it with a hard-flowing solder, the two being held during the operation in a blue gas flame with tweezers, and the end is trimmed square. A little whiting placed between the other edges will prevent the solder from flowing between or joining the pieces there. The short piece of plate is to form the spring, and is left unconnected at one end for that purpose (A, Fig. 481).

*To Form the Socket.*—The spring flange is first enveloped once around with a thin piece of platinum, a little deeper than the socket is required. The platinum is then enveloped with one thickness of coin gold plate, No. 32

U. S. standard gauge, about the depth the socket is to be, leaving a ledge of the platinum projecting. The platinum and gold are next removed and soldered, by holding them in a flame and using very little solder, of a hard-flowing variety, which is placed upon the ledge. The sides and ends of the sockets are then filed level and the socket given a square form (B).

*To Form the Cap.*—The spring flange having been inserted in the socket, two pieces of the spring gold plate of the same length as the socket are adjusted along its sides, the pieces being cut a little wider than the depth of the socket, so that when



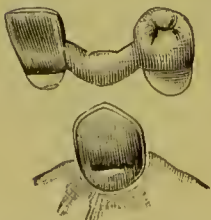
adjusted they shall project slightly above it. A piece of thin platinum plate is then adapted to the end of the flange, to the socket, and to the pieces of spring plate, first being perforated to allow the projecting ends of the latter to pass through it. The spring plates and the flange plate are then cemented to the platinum plate with wax, removed from the socket, invested, and soldered (C).

The sockets must be so placed on the crowns that the springs at the ends of the bridge shall enter them on parallel lines. Their proper relative positions to secure this movement are readily determined by attaching the tops of the spring flanges (either temporarily or permanently) to the ends of a piece of wire of the length of the space to be bridged, which will permit the necessary adjustment. The sockets are then soldered onto the crowns.

When the bridge teeth or dummies adjoining the sockets have been fitted in position, they are withdrawn with the caps and spring flanges, and soldered to the bar, in the manner described at page 256. The gold caps forming the occluding surfaces of the bridge tooth can usually be fitted over the cap. When the socket is attached lengthwise from labial to palatal side to a gold crown as at A, Fig. 477, the spring metal plate of the flange is best placed on the side toward the crown.

In a bridge of this style of the anterior teeth only,—where the abutments form the extremities of the piece,—the ends should be attached to the mesial sides of the crowns forming the supports; but when it also carries teeth posterior to the abutment, and the sections of the bridge are united together, the attachment should be made on the distal side, the bar supporting the anterior teeth resting in a slot formed on the palatal side of the abutment (Fig. 482). A shell crown on a cuspid can be utilized as a support for this form of attachment.

FIG. 482.



The attachment described can also be used in combination with removable plate bridges.

Fig. 483 shows the cast of a lower jaw in which only the left second molar, left cuspid, and right first bicuspid remained.

The molar and bicuspid were fitted with gold cap-crowns, and spring socket attachments (Dr. Parr's form) were soldered in

FIG. 483.

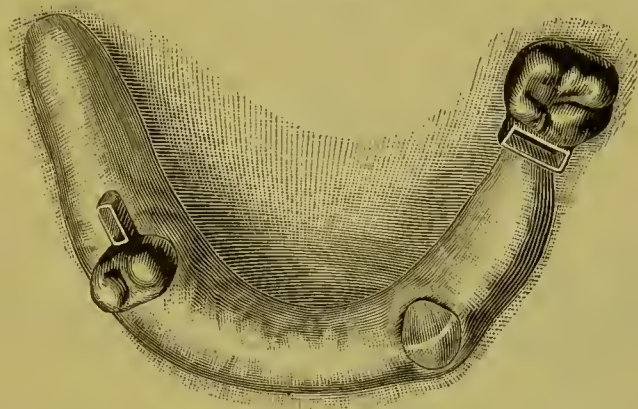


FIG. 484.

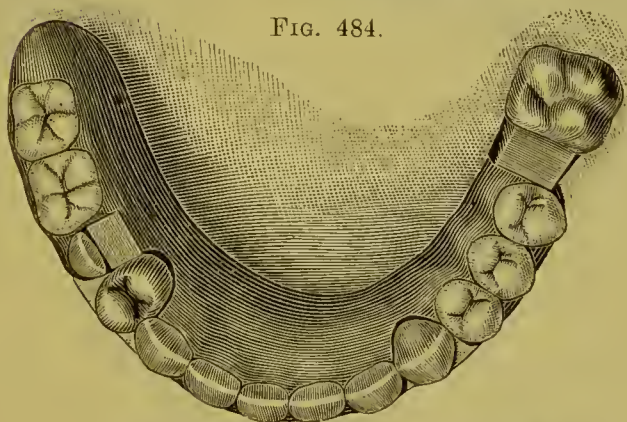
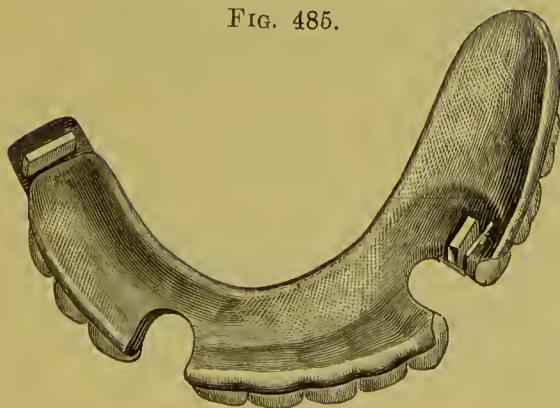


FIG. 485.



proper positions on the crowns, as illustrated. The completed denture in position supported by the attachments is seen in Fig. 484. The under side is shown in Fig. 485.

Fig. 486 represents the articulated cast of a case in which a similar form of attachment and a clasp were used. This is illustrated in Fig. 487, which needs no description.

Fig. 488 shows the denture in place. It was constructed of vulcanite, and made for and placed in the mouth of a patient exhibited at a clinic of the Odontological Society of Pennsylvania, at Philadelphia, in December, 1888.<sup>1</sup>

FIG. 486.

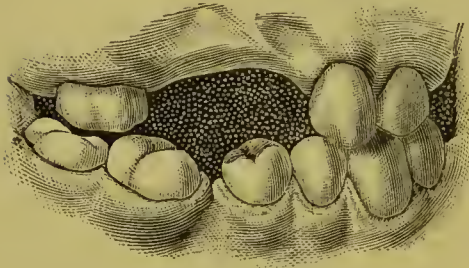


FIG. 487.

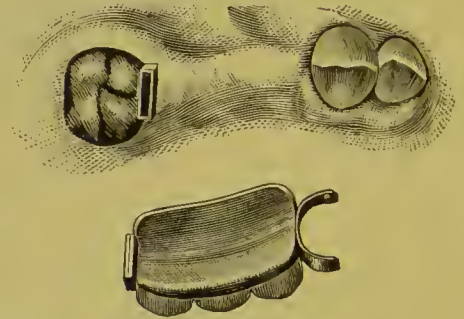
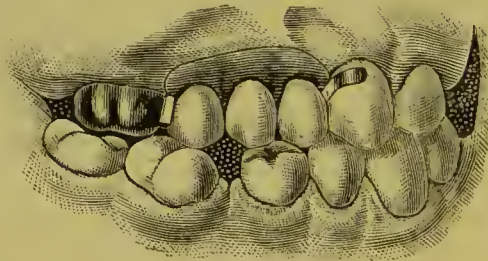


FIG. 488.



#### DR. WATERS'S METHODS.<sup>2</sup>

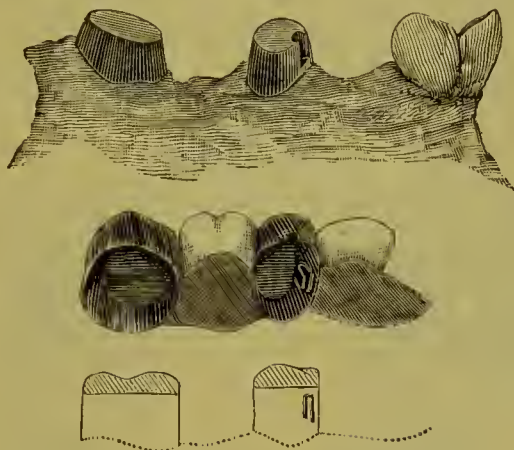
Dr. T. S. Waters explains the advantages of his removable plate bridge-work as follows: "In the system I present the denture is retained securely and steadily in the mouth, yet is readily removed and replaced at pleasure by the wearer. The pressure and strain are distributed properly over all the structures and tissues available for the purpose, and the roots and crowns to which the denture is attached are so prepared that there is no place for the lodgment and retention of food, and when the denture is removed, both it and the mouth can be thoroughly cleansed. Should the roots or other tissues be

<sup>1</sup> *Dental Cosmos*, March, 1889.

<sup>2</sup> *International Dental Journal*, April, 1889, p. 197.

attacked by disease, thus requiring treatment, or should repairs to the mechanism become necessary, the removable bridge-work offers facilities for those purposes not to be found in permanent dentures."

FIG. 489.



Dr. Waters thus describes the formation, combination, and application of his devices to cases of removable plate bridge-work:

"My devices are three in number, each of which may be used

FIG. 490.

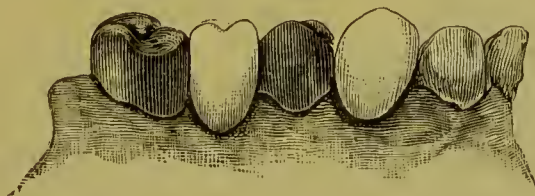


FIG. 491.



alone, or two of them or all three may be combined and applied in the same case, as the position, character, and relation of the teeth and roots remaining in the mouth may seem to indicate.

“The first is a gold crown fitted to and sliding on a cap attached permanently to the root or natural crown. This cap is made high and has on one side a longitudinal groove. The gold crown has soldered on the inside a spring catch, which works in the groove on the cap, and holds the crown firmly in its place. The character of the device is seen in application to the case represented in Fig. 489. Fig. 490 shows the denture in position.

FIG. 492.

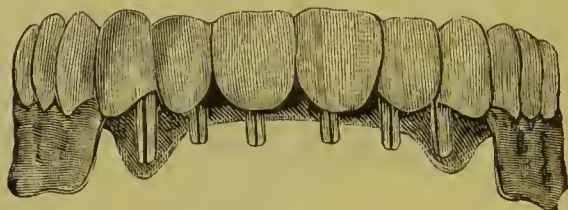


FIG. 493.




FIG. 494.

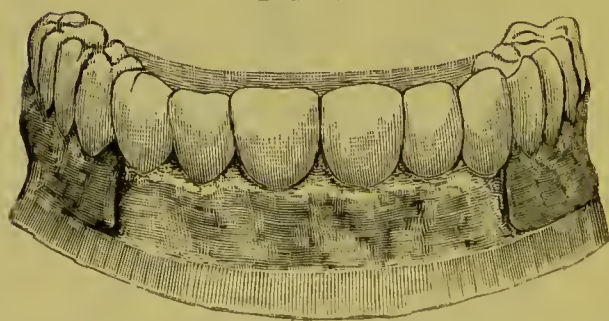


Fig. 491 gives the lingual aspect. It will be readily seen that under proper circumstances two or more roots or teeth may be fitted with this device, the gold crown may be soldered to and made a part of the denture, making the whole a piece of bridge-work capable of being removed, cleaned, and replaced at will. The spring catch regulates the firmness of retention.<sup>1</sup>

<sup>1</sup>Dr. Waters has patented this invention and donated it to the profession.

“The next device is the box cap and split post; the box cap being fitted permanently to the root, and the split post being soldered to the plate bearing the teeth. The box cap is the usual cap, with a box or tube soldered to it and extending into the root, the cap end of the tube being open. The split post is so secured to the denture as to slide snugly into this tube, the firm-

FIG. 495.

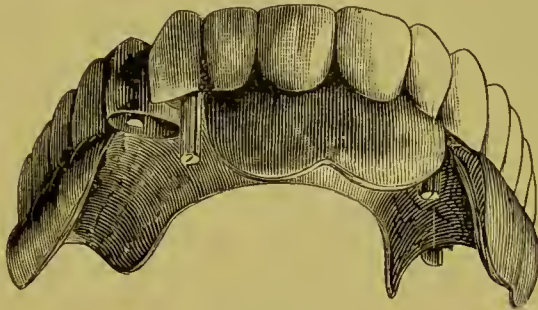


FIG. 496.

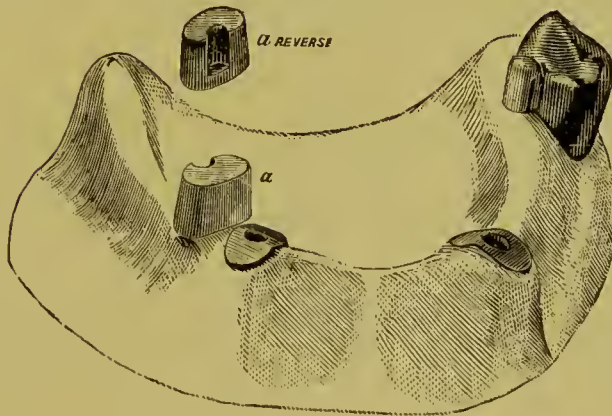
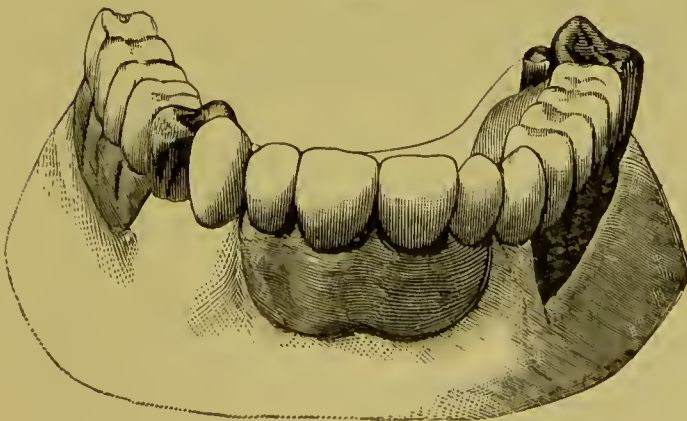


FIG. 497.



ness of retention being regulated by pressing the split slightly open when necessary. This device, like the first, may, under proper circumstances, be used by itself in any case, as shown in application in Figs. 492, 493, and 494, in which the whole denture is supported by box caps and split posts adjusted to the roots of the six anterior teeth.

“The third device consists in soldering to the side of the gold crown covering the natural tooth a split pin or post, which is inserted into the open tube attached to the denture.

“As before remarked, these devices may be used singly or in combination in any one case. In one of the dentures illustrated the box cap and split post alone are used; in another, the cap, gold crown, and spring catch are used; in the case illustrated in Figs. 495, 496, and 497 the three are applied, in which the entire denture is attached to and retained by two cuspids, a bicuspid, and a molar. In all this, great care must of course be taken in the preparation of the roots and natural crowns, to protect them against the action of destructive agents.”

#### DR. BONWILL'S METHOD.<sup>1</sup>

The special feature of this method is, the advocacy of connecting the clasp attachment to the plate with a piece of stout gold and platinum wire on the side of the tooth offering the least resistance to the insertion and removal of the clasp. This, for instance, should be on the buccal side of a lower molar if it tipped inward or forward. The clasp is thus left free to spring over any portion of the crown out of line.

The clasp is surmounted with a flange or spur placed at a point free of the occluding teeth, and the plate is made of heavy gold plate or of two thin plates soldered together. A description of the following practical cases will explain the method:

Fig. 498 is a cast for the first upper bicuspid, right side. A filling of gold was placed in the distal surface of the natural cuspid, with a hole, *c*, drilled into the filling for the pin *c*, Fig. 499. The second bicuspid had also a large amalgam filling, around which the clasp was placed, so that it would not show

---

<sup>1</sup> *International Dental Journal*, vol. xiv, page 94.



from the mouth. Fig. 499 shows the plate with a tube-tooth or porcelain crown thereon, with pin soldered to the plate. The clasp has a flange attached to it at *h*. *i* is a heavy platinized gold bar, showing how it forms a free attachment between plate and clasp. *c* is a pin, soldered directly to the plate, which enters the hole in the gold filling shown at *c*, in Fig. 498.

Fig. 500 is a skeleton plate with the attachments without the tooth made for the case—left side, lower jaw—shown in Fig. 502. *e* and *e*, Fig. 500, are flanges to prevent the plate pressing too hard on the gum. One rests on the molar independent of the

FIG. 498.

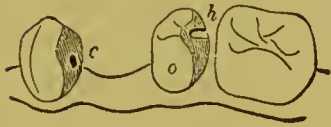

FIG. 499.

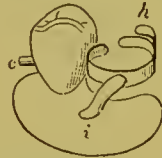

FIG. 500.

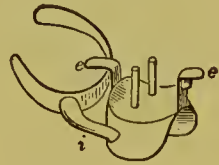


FIG. 501.

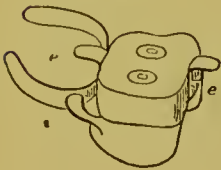


FIG. 502.

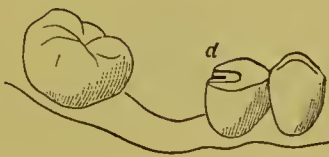
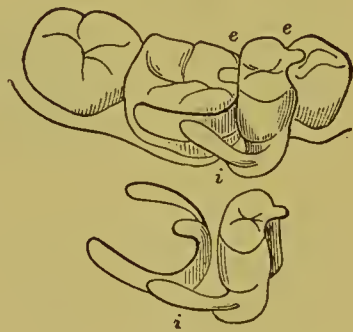


FIG. 503.



clasp, and the other on the bicuspid. A small spur is placed under the flange that is to rest on the bicuspid to fit in a groove in an amalgam filling shown at *d*, Fig. 502, to keep the anterior portion of the plate in position. The clasp is connected to the plate at the lingual side by the bar marked *i*. Fig. 501 shows the finished case with the artificial crown cemented over the pins or vulcanized on.

Fig. 503 shows the replacement of a second bicuspid, right side, lower jaw. The bar *i* is soldered to the plate and clasp on the buccal side of the first molar. The artificial tooth is made entirely of gold, and the flange resting on the first bicuspid

is soldered directly to it. The anterior surface of the gold tooth is made concave to fit the distal surface of the first bicuspid, and so prevent lateral movement.

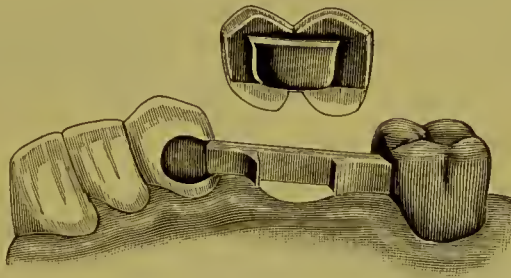
In this case a gold crown is used as the artificial tooth, as it facilitates the soldering, adds to the strength, is easy to repair, and is not seen. The rear flange, which rests on the molar, might have been soldered to the gold tooth also, and less strain would thus come on the clasp.

## CHAPTER XIII.

### REMOVABLE BAR-BRIDGES.

IN removable bar bridge-work the bar is permanently attached to the abutments, and spans the space between them independent of the bridge. The bridge portion proper of the denture, consisting of the artificial teeth (dummies), is formed with a slot, or a countersunk base, into which the bar slides as the bridge is placed in position.

FIG. 504.



In the case represented in Fig. 504, one end of the bar is attached to the gold molar crown and the other end anchored in the cuspid with a gold filling. The bridge section fits over the bar as illustrated. The process of construction as given by Dr. J. G. Morey is as follows :

The molar is capped with gold. A flat bar of iridio-platinum, about No. 12 gauge and one-eighth of an inch wide,—the width being regulated by the needs of the case in hand,—is fitted to the space. One end of the bar is fitted in the anchorage cavity in the cuspid, and the other end to the gold molar crown. A slot is then cut in the bar, beveled slightly toward the gum (Fig. 504).

A piece of gold clasp plate, about No. 28 gauge, the width of the slot, is cut and shaped in the form of a clamp to fit over both sides of the bar and in the slot. The end of the bar is then soldered to the gold crown. The bar must be placed far enough

toward the palatal side to leave space for the artificial teeth. Porcelain teeth are next fitted in place, backed with thin platinum, cemented with wax to the clamp-shaped piece of gold, and removed from the bar. Teeth and gold clamp are then invested and soldered together. In investing, one end of a narrow strip of sheet iron is inserted in the slot of the gold clamp, and the other end extended into the body of the investment, to hold and steady the gold clamp in position, while the gold solder is flowed between it and the porcelain tooth after the wax is removed. When finished, the point of the gold clamp is to be bent a little inward to secure and fasten the bridge section when slid into position on the bar. Firmness is also obtained by the slightly beveled form given to the slot in the bar. Fig. 505



gives a sectional side view of the bridge-tooth and bar. Fig. 506 represents the bar and bridge section in position.<sup>1</sup>

Dr. Morey's method of constructing a double bar-bridge with a removable molar or dummy is as follows:

The bar is formed as seen in Fig. 507. "A countersunk molar is ground and shaped as seen at A and B, Fig. 508. To the base of the molar and up in the slot is shaped and fitted the shell C, made of a very thin piece of gold and platinum crown-metal by

<sup>1</sup> A description of a removable bar-bridge, as given by Dr. J. G. Morey, was presented in the first and second editions of this work. A more extended description of bridge-work on this principle is given in the later editions, as many members of the profession seem to favor the various methods it involves. In England the method is designated the "Gartrell Bridge," having been introduced there by Dr. Gartrell, an American dentist, formerly of New York, now practicing at Penzance, England.

The models of a case similar to the one illustrated in Figs. 504 and 506 were exhibited at the Ninth International Medical Congress at Washington and presented by Dr. Morey to the author in 1887, and are still in his possession; but as the method did not favorably impress him at the time, further description of it than has heretofore been given was withheld.—G. E.

first stamping it on a fusible metal die of the base and then adapting it to the part. A thin piece of clasp-metal (D) is then formed to fit over the bar and in proper position into the slot of the shell (C, Fig. 507), to which it is fastened by investing and soldering on the inside of the shell. The shell is then cemented with oxyphosphate onto the base of the molar as seen at A and B, Fig. 507, and is secured to the bar by springing together the edges of the metal at D, Fig. 508. Fig. 509 illustrates the tooth in position.

FIG. 507.

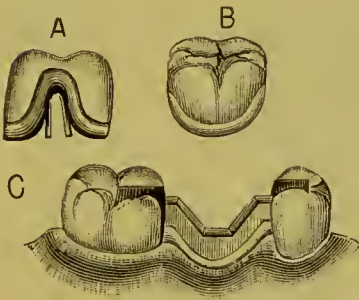


FIG. 508.

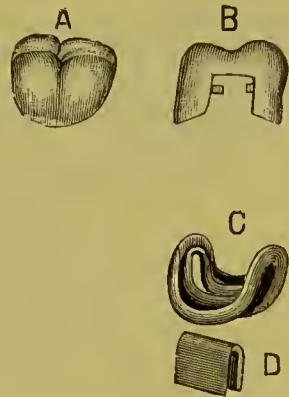
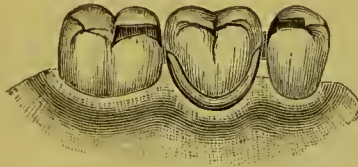


FIG. 509.



A variation in the method of construction of removable bar-bridges involving the principle above demonstrated is given by Dr. G. L. Curtis in the following case, illustrated in Fig. 510. The bicuspid and molar are capped with gold, and models made. In the construction of the dummies, the caps and backing at first are merely joined together with solder just sufficient to prevent movement of the caps. The sockets, like A, Fig. 511, which are made of thin gold, are then placed in position and held by means of *fluxed* wax, and the entire piece again encased as before, so that the ends of the sockets project beyond the cusp-surface of the bridge and are imbedded in the plaster, which holds them in position. The wax is melted out and the sockets soldered

into place. After cooling, the projecting parts of the sockets are cut away until the bridge fits perfectly between the crowns, and the soldered surface is ground away to the proper fullness, and the whole piece rendered quite smooth or ready for polishing (C, Fig. 510). Arms like B, Fig. 511, are now placed into the sockets and cut off until a perfect adjustment with the crown is

FIG. 510.

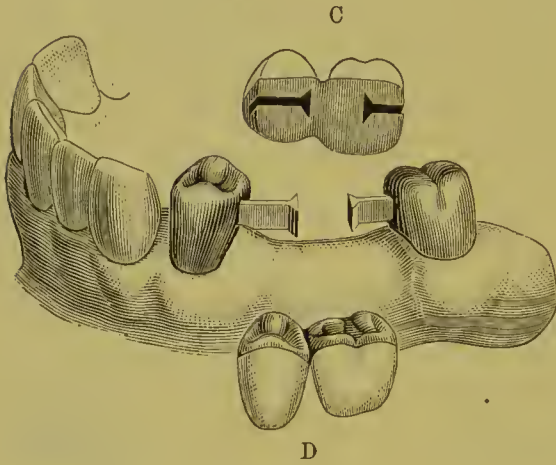


FIG. 511.

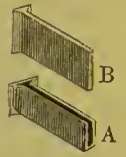


FIG. 512.

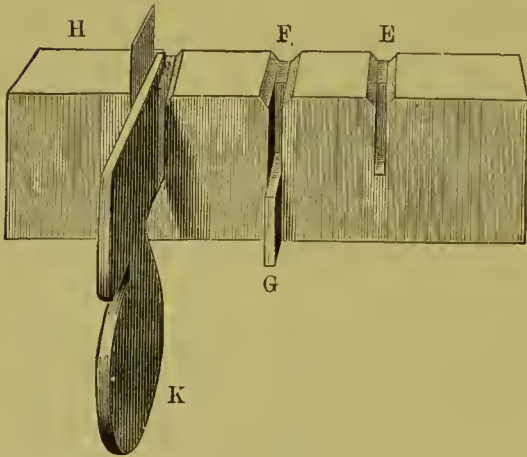


FIG. 513.



obtained. It will be found that the arms are considerably wider than the sockets are deep, allowing them to project one-sixteenth of an inch or more. Secure the bridge in position by a drop of wax at the junction of the porcelain surface and the cast, then varnish the palatal surface of the cast and pour soft plaster and marble-dust over the surface until it is on a level with the

masticating surface, and allow it to harden. Then carefully remove the bridge and replace the arms in position as marked in the plaster, and retain them by means of additional plaster, or by steel springs, and solder them to the crowns, first placing in the joint sufficient fluxed wax so that in the process of soldering the arms will be perfectly united to the crown, which requires a very small quantity of solder. The case is now ready to finish.

FIG. 514.

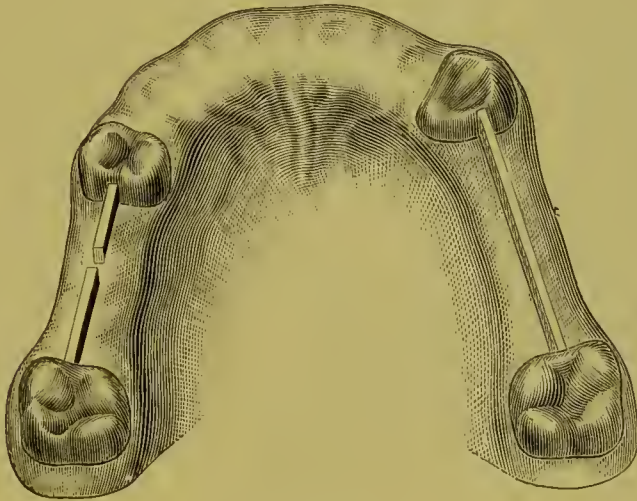
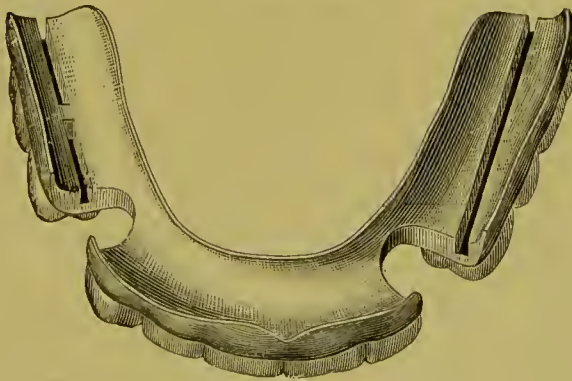


FIG. 515.



If the adjustment of arm and socket is perfect, the structure will be found to fit so snugly that it is only with considerable effort that the bridge can be removed. With everything in readiness for cementing, the crowns are quickly forced into position, the bridge carried to place, and the cement allowed to harden.

Should any alteration be necessary in the articulation that cannot be made by grinding off the cusps of the antagonizing teeth, the bridge can readily be removed without disturbing the crowns.

The arm B, Fig. 511, is made of a strip of clasp-metal, No. 16 gauge in thickness, and of any desired width or length. The strip is placed in a slot like E, Fig. 512, and the projecting end hammered to form a solid head as shown. A longer or shorter arm may be formed in the slot F, wherein the adjustable limit, G, may be set to mark the length of the arm while the hammered head is being formed. A piece of 20-carat gold plate, or preferably clasp-metal No. 33 gauge, is cut to the size and shape of Fig. 513, and by means of a former, K, Fig. 512, is forced into a suitable slot. The place of the former K is then taken by the arm B, Fig. 511, and the part H, Fig. 512, bent and delicately hammered over the head of the arm. The socket so formed is then removed, soldered from the outside, and finished as at A, to exactly fit the arm B, Fig. 511.

Figs. 514 and 515 illustrate a case by Dr. Parr, in which a removable bar-bridge plate was applied.



## CHAPTER XIV.

### DR. KNAPP'S METHODS.

DR. J. ROLLO KNAPP has introduced some novel methods in crown- and bridge-work, for effecting artistic results and continuity of structure.

In crown-work, Dr. Knapp invests for soldering so that the parts to be united and filled form a miniature mold. Into this mold, at a high heat, with a pointed flame from his blow-pipe, he flows solder, which fills the interstices, joins the parts, and assumes the form of the mold. The following is a brief description of his methods :

FIG. 516.



FIG. 517.



In constructing a gold collar crown with porcelain front, for an incisor or cuspid, 22-carat collar gold (The S. S. White Dental Mfg. Co.'s), No. 28 standard gauge, is used for the collar, which is formed by adapting the gold to the root by the aid of pliers. The cap to the band is then made of pure gold, No. 34 gauge, and a gold pin soldered in position for the root-canal. A plate tooth is then ground in proper position, backed with pure gold, and fastened to the cap with wax. On being removed from the mouth after proper adjustment, the side and incisive portions of the wax, including the edges of the backing and contiguous portions of the cap, are completely enveloped with pieces of pure gold No. 34 gauge (Figs. 516 and 517). The crown is then invested so that when the wax is removed the backing on the tooth with the

gold on the sides shall form a small mold or pocket (Figs. 518 and 519). When the investment is heated, the flame of his blow-pipe is played over its surface until the mass is aglow, when the point of the flame is thrown into the mold by rapid thrusts until the solder melts like wax and fills every part of the mold with liquid gold. This gives an excess of gold which affords ample facilities for contouring in the process of finishing (Figs. 520 and 521).

FIG. 518.



FIG. 519.

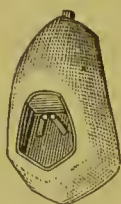

FIG. 520.



FIG. 521.



In constructing a bicuspid crown with porcelain face, the natural tooth is ground down to the gingival edge and capped similar to a cuspid. A bicuspid porcelain front is then ground and fitted in position (Fig. 522), and the remaining portion of the crown is shaped in wax to the form required. A die of the grinding-surface is then made in metal, a cap stamped in pure

FIG. 522.



FIG. 523.



FIG. 524.



FIG. 525.



FIG. 526.



FIG. 527.



gold, No. 34 U. S. standard gauge (Fig. 523), and the cusps filled with 20-carat gold solder. This cap is next trimmed (Fig. 524) so as to fit when placed in proper position against the end of the porcelain cusp, for which purpose sufficient wax must be removed. The approximal surfaces are enveloped and the palatal portion of the collar protected with pieces of pure gold, No. 34 standard gauge, which are slit to facilitate their adjust-

ment (Fig. 525). This leaves the palatal portion open when the crown is invested and the wax removed, which last should be done with hot water. Fig. 526 shows the invested crown ready for soldering, in which operation the parts are filled in and joined with 20-carat gold solder. The result when finished is a solid gold crown with a porcelain front (Fig. 527).

Dr. Knapp's method of constructing bridge-work is similar to that in general use except in the investing and the soldering together of the parts, the latter being done with the blow-pipe in a manner similar to that above described.

Figs. 528 and 529 illustrate specimens.

FIG. 528.

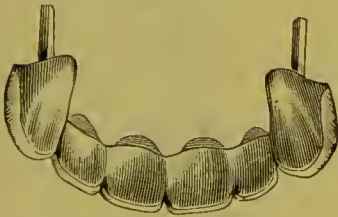
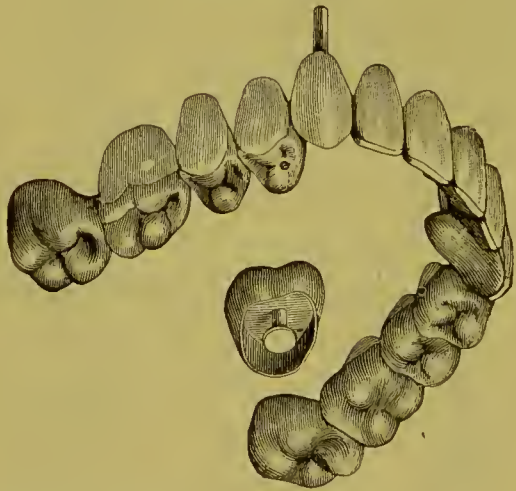
FIG. 529.



Dr. Knapp's compound blow-pipe (Fig. 530) consists of a miniature blow-pipe in which the ordinary illuminating gas (carburetted hydrogen or coal gas) flame is combined with a current of nitrous oxid from a cylinder of the condensed gas. The combination of these gases in combustion forms essentially a carbo-oxyhydrogen flame.<sup>1</sup> By means of a yoke and set-

<sup>1</sup> The ordinary compound oxyhydrogen blow-pipe flame is produced by  
2 volumes of hydrogen ; 1 volume of oxygen.

Carburetted hydrogen consists of

2 volumes of hydrogen ; 1 volume of carbon.


And nitrous oxid of

2 volumes of hydrogen ; 1 volume of oxygen.

Consequently Knapp's blow-pipe flame is produced by a mechanical mixture of  
2 volumes of hydrogen ; 1 volume of oxygen ; 1 volume of carbon.

screw, the valve of the cylinder is connected with the tubes and valves of the blow-pipe, so that the proportions of the mixture of nitrous oxid and the illuminating gases are under perfect control. The flame-jet can be diminished to half an inch in length, and at that size will melt a small piece of gold plate.

FIG. 530.



Where illuminating gas is not available, an apparatus termed a carburetter can be used, which supplies the deficiency in a simple manner by vaporizing naphtha.

This blow-pipe is useful for many purposes in the laboratory of the present time, especially in forming solid gold backings to dummies for bridge-work, strengthening seamless gold crowns, and forming solid gold crowns.

Dr. Knapp has exhibited to the profession some very fine specimens of crown- and bridge-work, and presented much that is novel and interesting, as well as encouraging to the artistic element of prosthetic dentistry. His special methods, however, while admitting of the highest artistic results, embrace some processes which, on account of their intricacy, have not been very generally adopted in practice.

## CHAPTER XV.

### THE MANDREL SYSTEM.

IN all styles of collar crowns the shaping and adapting of the collar is usually found by many dentists to be the most difficult part in their construction. To facilitate its performance the "Mandrel System" was introduced by The S. S. White Dental Manufacturing Co.<sup>1</sup>

"The configuration of the necks of all the teeth having been determined, a set of mandrels for shaping collars to fit them was devised. The set (Fig. 531) consists of seven tapering mandrels, six of which are double end, representing the average shapes of the necks of all the teeth. The illustrations are about two-thirds actual size, the longest instruments being nine inches in length. The cross-sections show the shapes and proportionate sizes at the greatest and least diameters.

"No. 1 is a double-end mandrel, for superior molars, right and left; No. 2 is a single mandrel, for superior bicuspid, right and left; No. 3 is double-end, for superior cuspids, right and left; No. 4, double-end, for superior centrals, right and left; No. 5, double-end, for inferior molars, right and left; No. 6, double-end, for the inferior centrals, laterals, cuspids, and first bicuspid, right and left; No. 7, double-end, one end for the superior lateral incisors, the other for those bicuspid in which a bifurcation of the roots, or a tendency in that direction, extends across the neck to the crown in the form of a depression on one or both approximal surfaces. The foregoing scheme comprehends all the teeth of the permanent set except the second inferior bicuspid. The necks of these approximate those of the superior central incisors so closely in shape that it was deemed inexpedient to make a separate mandrel, as the No. 4 mandrel will serve for both.

---

<sup>1</sup> *Dental Cosmos*, vol. xxviii, No. 8.

FIG. 531.


# MANDRELS

FOR SHAPING SEAMLESS TOOTH-ROOT COLLARS.



“The collars or bands are made seamless, of No. 30 (American gauge) gold plate, 22 carats fine. Fifteen sizes, each of three widths ( $\frac{1}{10}$ ,  $\frac{2}{10}$ , and  $\frac{3}{10}$  inch) are made (Fig. 533), which it is believed will cover all requirements. These collars, although devised as a part of the system, can be used in all methods of crown- and bridge-work which require bands. They are so constructed that Nos. 1, 16, and 31 exactly fit into or telescope with Nos. 2, 17, and 32, and so on through the entire set, each collar fits into the series next higher; so that a root may be banded with one size and the size next larger used to form the

FIG. 532.



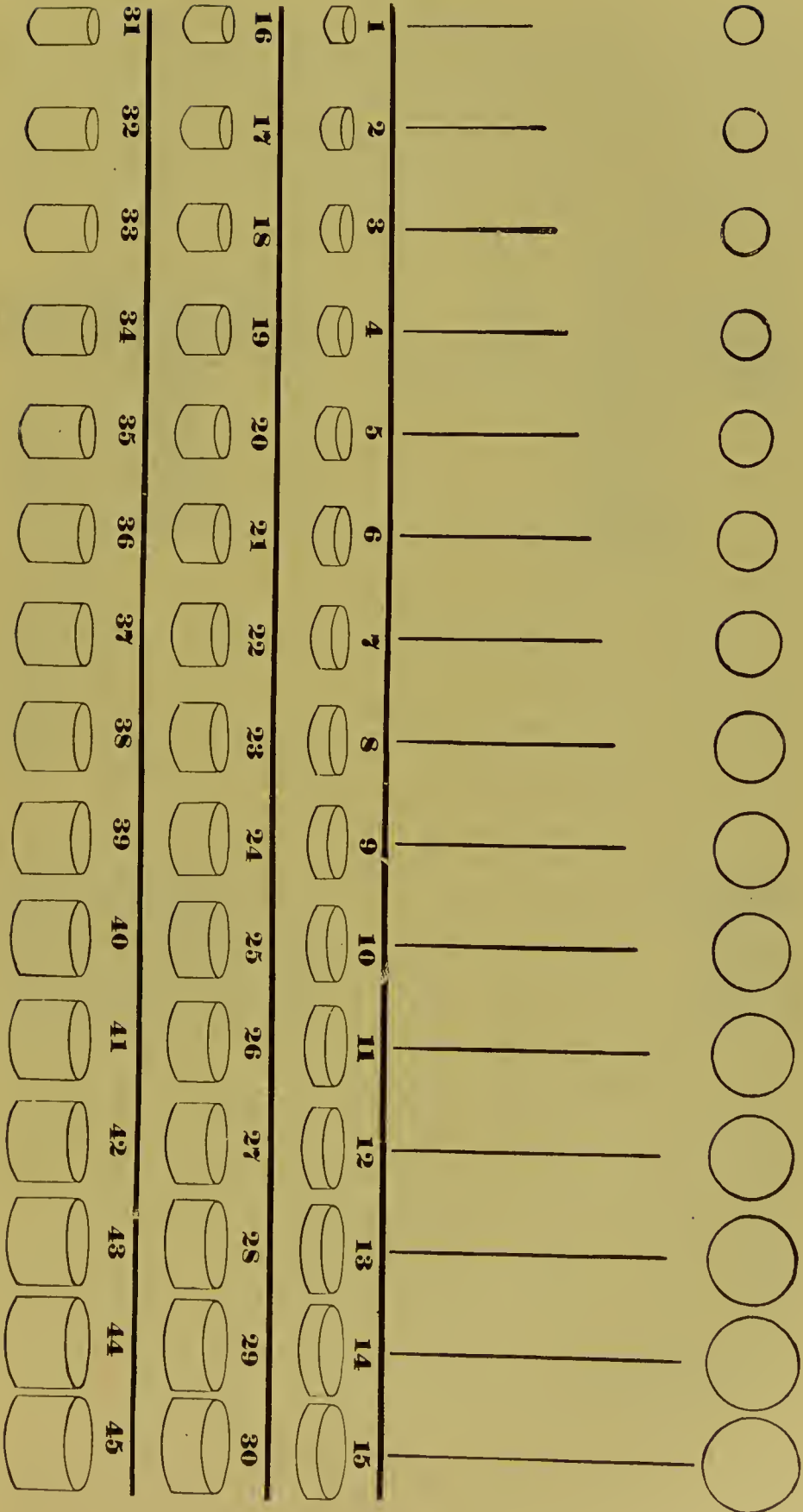
tube for the telescoping crown. When desirable, the ‘seamless’ collar can be strengthened, after being adapted to the conformation of the crown, by investing and flowing solder over the outer surface; or by fitting the next larger size of collar around the first, investing and soldering the two together.

“The other appliances devised for this system are, a reducing-plate or contractor, a pair of collar pliers, and a hammer.

“The contractor (Fig. 532) contains holes which are complementary in shape to the mandrels. The mandrels being applied to the inner circumferences of the collars, while the contractor must admit the collars themselves, the short taper of the holes in the contractor necessarily covers a somewhat greater range of size than is shown in the mandrels. With this appliance collars



FIG. 533.



can be evenly and accurately reduced in size at the edges, without burring or buckling. The illustration is actual size.

“The collar pliers (Fig. 534) are for contouring the collars to shape, one beak being made convex and the other concave to correspond. Fig. 535 is a mallet or hammer, with steel face and horn peen.

FIG. 534.

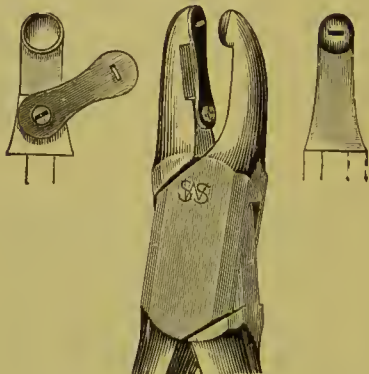



FIG. 535.



“To select and adjust a suitable collar for a crown or root, take a piece of binding-wire (No. 28, American gauge), two and one-half inches long, pass it around the neck of the molar stump, cross the free ends, and, holding the wire in place with one finger, twist the ends with a pair of flat-nose pliers until the wire clasps the neck closely at every point (Fig. 536). Where

FIG. 536.

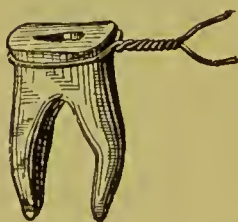
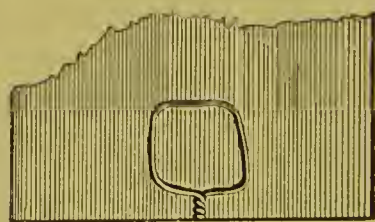


FIG. 537.



there are irregularities in the contour of the tooth, it is necessary to press the wire into them with a burnisher. The ring thus formed will show the exact size and shape of the neck of the tooth. Remove the ring carefully, lay it on the lead anvil, put over it a piece of flat metal, and with a smart blow from a hammer drive the wire into the lead (Fig. 537). Upon removing the wire, an exact impression of the ring will be left in the anvil.

“Next, cut the wire ring at the lap, straighten out the wire,

and select a suitable collar by comparing the length of the wire with the straight lines in the diagram (Fig. 533), which show the inside diameters of the various sizes. Should none of these correspond exactly, take preferably the next size smaller. Having selected the collar, fit to mandrel with the peen of the hammer, holding it upon the lead, and using a slight pushing force to help in stretching and forming it (Fig. 538). Having

FIG. 538.

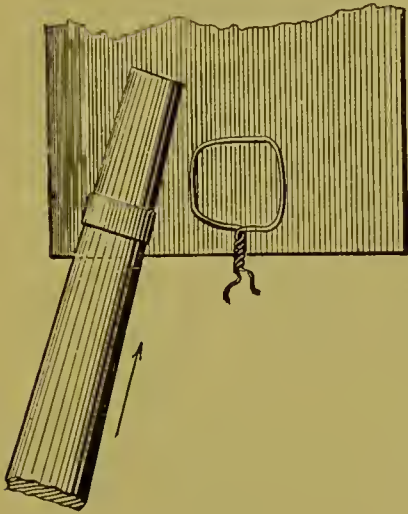


FIG. 539.



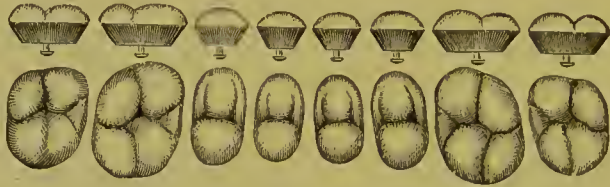driven the collar to form, remove it from the mandrel and try in the lead impression. If it does not fit exactly, return it to the mandrel and stretch it a little, when it will usually fit perfectly.

“If the collar or band has been accidentally stretched too much, or if for any reason it is too large, its root-end can easily be reduced to the proper size by the use of the contractor. Place the edge of the collar which is to fit the root in the proper hole; hold it level with a piece of file as in taking the lead impression of the ring, and tapping lightly on the file drive the collar into the plate (Fig. 539) until the proper reduction is made.” The collar is next trimmed to correspond to the shape of the gum-margin. The cap section to represent the grinding-surface is then added by one of the methods described on pages 81 and 86.

The grinding section, in cases of pulpless roots, may be constructed of porcelain by the use of porcelain cusp-crowns, such as are shown in Fig. 540. Where porcelain is to be used, place the collar in position, and having ascertained how far it should go down on the root, remove it, and with the small spring punch in the collar pliers form projections on the inside of the collar at proper points to serve as stops, which, by resting on

the top of the root, will prevent the collar from being forced farther down on it than is desirable (Fig. 541). Next fit and cement screw-posts in the root-canals, leaving the ends projecting in the space inside the collar, and cement the collar on the root,

FIG. 540.



filling about two-thirds of the depth of the collar. Select a suitable cusp-crown, of the form illustrated in Fig. 540, and fit to inside of end of collar. If too long, shorten the cusps or reduce

FIG. 541.

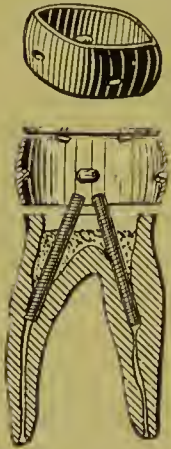
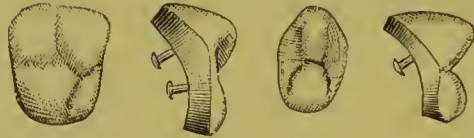

FIG. 542.



the length of the collar. When articulated, form a small square shoulder around the line of the edge of the porcelain with a corundum disk. Fill the remainder of the inside of the collar with cement, mixed to a cream-like consistence, and set the porcelain in position. If there are antagonizing teeth, the mere closing of the patient's jaws will force the cusp to position in posterior teeth. In the front, or where there are no occluding surfaces, force to position with the mallet or a piece of wood as a driver.

FIG. 543.



Porcelain cusp-crowns of the form shown in Fig. 542 are intended for use where the labial side of the collar is cut away, and that section is to be represented by the porcelain as shown in Fig. 543.

## CHAPTER XVI.


### THE HOLLINGSWORTH SYSTEM.

THE object of the "Hollingsworth System" is to systematize and simplify the process of construction of that style of crown- and bridge-work in most general use. To this end the form of procedure is concisely outlined and some special methods and appliances introduced. The last mentioned consists of a set of two hundred and four forms of solid metallic grinding-surfaces of bicuspid and molars, termed in the description "cusp-buttons," for use in forming grinding-surfaces for crowns or dummies; thirty-six facings for shaping the labial surfaces of all-gold bicuspid and molar dummies, and forty for labial and palatal surfaces of all-gold incisors and cuspid crowns. These collectively are to be seen in the case illustrated in Fig. 544; likewise (Fig. 544 A) some other appliances contained in the set. A brief description of the principal methods in connection with the use of the appliances is here given.

#### TO MAKE A GOLD CROWN (BICUSPID OR MOLAR).

Make a band to fit the root in the ordinary way. Place the band in the mouth (see Fig. 545), and cut off on a line where the adjoining teeth begin to turn to form the cusp (see *c*, Fig. 545). Place a small piece of wax inside the band to assist in holding the cusp-button, which should be selected to fit the circumference of the band, to articulate properly, and to correspond in shape with the other teeth (see *b*, Fig. 545). Remove the button, and place it on the molding-plate with the grinding-surface up (see Fig. 546). Place the small rubber ring around it, pour in a sufficient quantity of Melotte's metal to nearly fill the ring (Fig. 547). As soon as the metal sets, chill the surface by dipping in water for a moment, and then remove the rubber ring. When the heat begins to

FIG. 544.



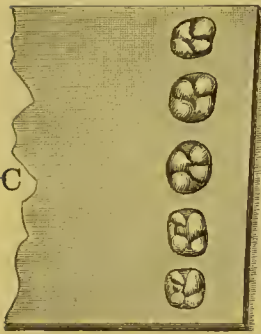
Set consists of the following: 204 Cusps, 36 Facings, 40 Forms for Incisors and Cuspids, in folding case, 1 Casting Plate (A), 3 Rubber Rings (E, F), 1 Carbon Rod (B), 1 Sheet Asbestos 10 x 7 in. (C), Box of Annealed Copper Strips (D).

return to the surface, a quick rap of the die on the bench will cause the cusp-button to drop out and leave the mold ready to form the gold cusp. Now take a piece of lead, for instance a

FIG. 544 A.



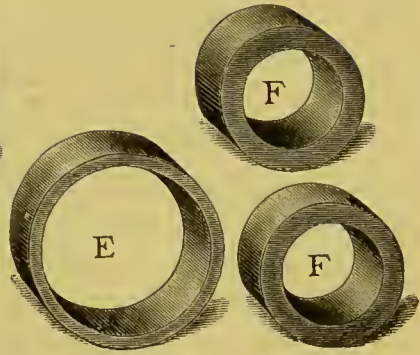
B



C



D



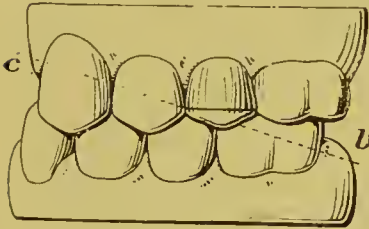
E

F

F

FIG. 545.

FIG. 547.



c

l

FIG. 546.

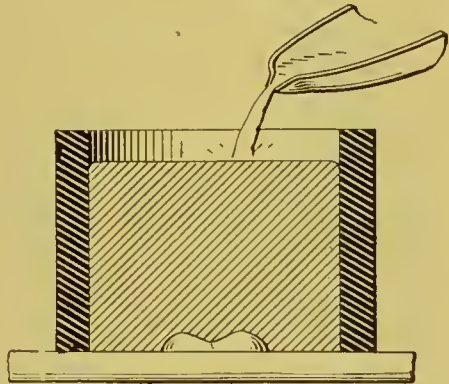


FIG. 548.

FIG. 549.

FIG. 550.

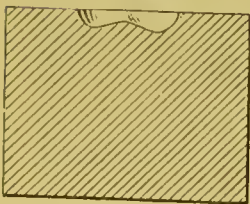

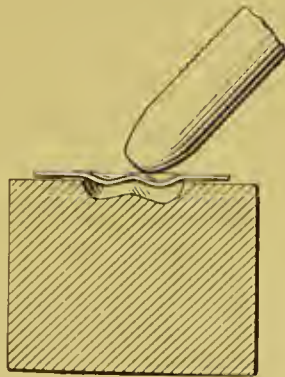



FIG. 551.



lead hub, and with a hammer drive into the Melotte-metal die (Fig. 548) to form the counter-die (Fig. 548, *d*).

Anneal the gold plate, and start the swaging process by coaxing the plate into the die by hand-pressure (Fig. 549), using a piece of wood which makes a depression for the lead counter-die to rest in. Then place the counter-die on the gold plate (Fig. 550), and drive to a fit. Cut the surplus metal from the hollow cusp with shears (Fig. 551), filing up the edges when necessary, and rub down the under surface on a smooth file until it fits the band made for it (Fig. 545). Wire the cusp and crown together (Fig. 552), place flux and solder in the cap, and hold over a lamp until soldered. Then finish in the usual way.

*Note.*—If the forms of cusp-buttons do not afford one which articulates perfectly, the difficulty is easily remedied by taking the button

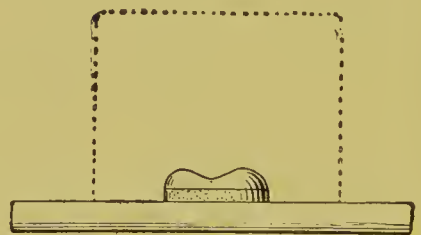
FIG. 552.

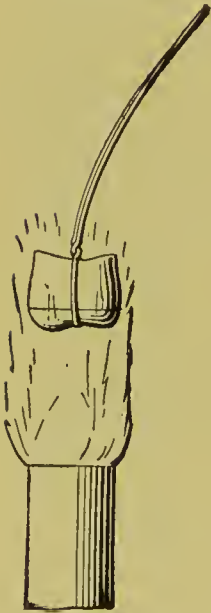

FIG. 553.

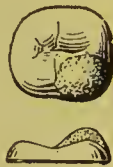

FIG. 554.



which most nearly answers, and building up the cusps with Melotte's moldine (Fig. 553). If a band is accidentally cut too short, it can still be utilized. Place moldine upon the molding-plate, put the cusp-button upon it, press down and adjust to make up the deficiency of the band, cutting away the surplus moldine. This will of course throw the soldering line a little farther upon the crown (Fig. 554).

#### TO MAKE SOLID GOLD CUSPS.

Scrap gold can be utilized for making a solid gold cusp by casting in asbestos by the following method :

After selecting the desired cusp-button, instead of making a mold in Melotte's metal, as before described, take a piece of



asbestos board about one inch square and one-fourth inch thick, moisten it, and with a hammer drive the cusp-button into it, flush with the surface of the button. (See Fig. 555, *a*.) Remove the button, and dry the asbestos in a flame (Fig. 555). When perfectly dry, place a sufficient quantity of gold scraps in the die made in the asbestos, and direct the blow-pipe flame upon it until melted, inclining the carbon stick, as shown, against the die for the double purpose of confining the heat and warming up the carbon stick. When the gold is fused into a button, press it into the die with the carbon stick (Fig. 556). *Avoid the use of flux when working with asbestos.*

FIG. 555.

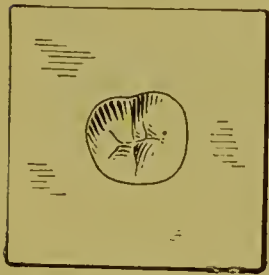
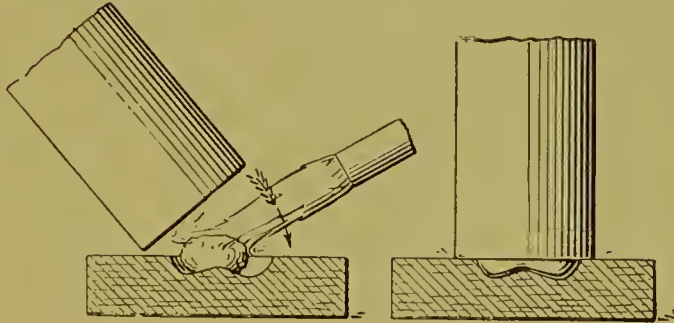
FIG. 555, *a*.

FIG. 556.

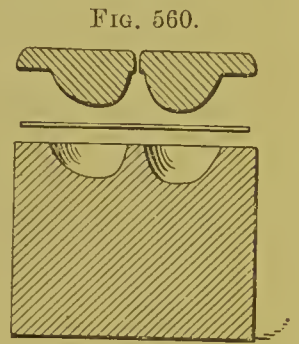

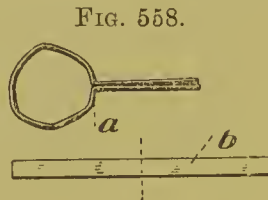
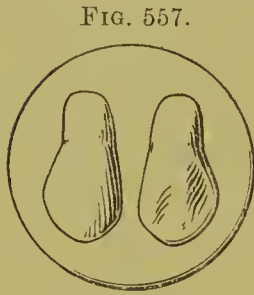


To build up a cusp to make a perfect articulation, in this method, sealing-wax must be used instead of moldine, as in the method of swaging the cusp. Warm the button before applying the wax, and with a warm instrument shape the cusp as desired.

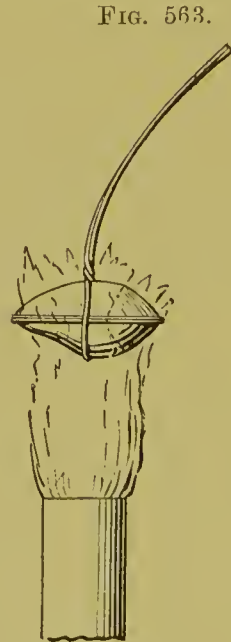
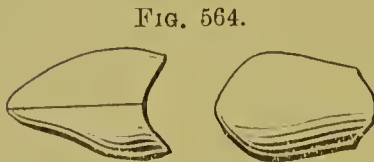
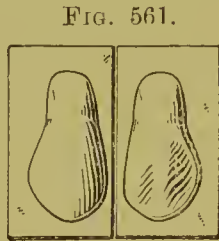
#### TO MAKE GOLD CROWNS (CENTRALS, LATERALS, AND CUSPIDS).

Select from the forty different forms in the set that which is most suitable to the case in hand (Fig. 557). (The forms are in pairs, showing labial and lingual surfaces.) Take the measurement of the root to be crowned with one of the annealed copper strips, binding the strip around the tooth with pliers (Fig. 558, *a*). Take this measurement and cut it through the center (Fig. 558, *b*), then bend the respective halves over the lingual and labial forms selected, at the necks, with the cut

ends of the strips resting on the flat of the plate (Fig. 559). If the measurement is larger than the form selected, build the latter up with moldine until the space between the form and strip is filled (Fig. 559, *b*). Avoid getting moldine on the approximal surface. Remove the strips, dry out the moldine,



by passing through a flame a few times, then place the form on the molding plate with a rubber ring around it. Pour Melotte's metal into the ring as in forming the molar or bicuspid cusp, which makes a die of the two sections, lingual and labial.

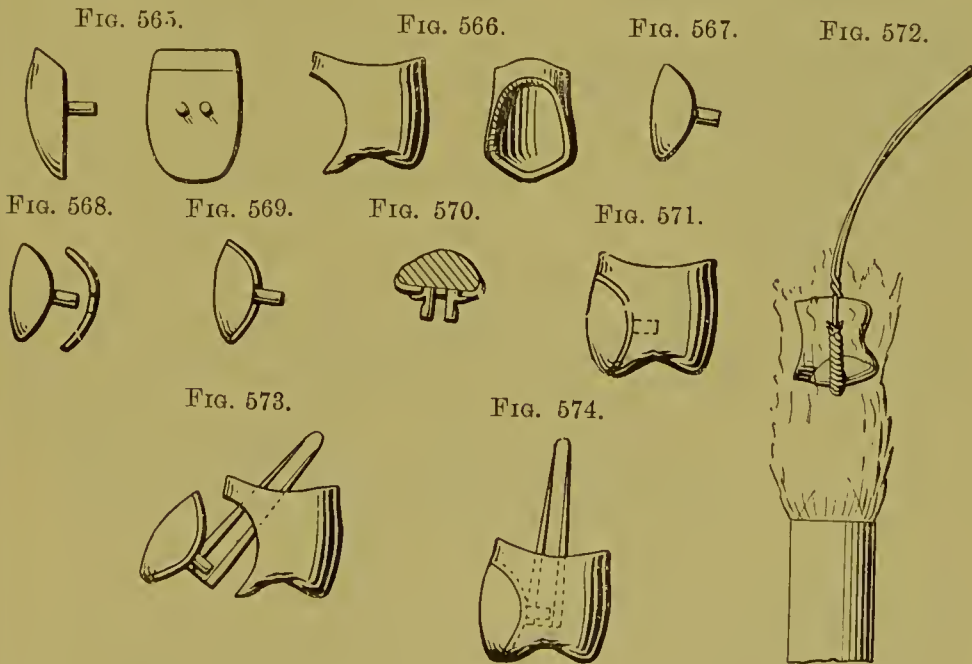


Make a lead counter-die and proceed as directed in the making of a molar cusp, swaging both sections (Fig. 560). Trim off the surplus plate (Fig. 561), and square the opposing edges

of the two sections by rubbing them over a dead smooth file. Bind the two sections together with wire with sufficient solder and flux inside (Figs. 562 and 563), and proceed as in soldering an ordinary band. With a small mechanical saw cut off the upper portion where the tooth begins to slope back (about the dotted lines in Fig. 563). This leaves the crown as shown in Fig. 564, approximal and labial views. Drive on the root. If too small, place on the horn of an anvil and enlarge by hammering; if too large, band the root in the same manner as for a Richmond crown, grinding the tooth to fit.

TO INSERT A PORCELAIN FACING.

Make the gold crown as described. Select a porcelain facing suitable for the case (Fig. 565). Place the crown on the root in the mouth, and with an excavator mark on the face where



the porcelain is to appear. Remove the crown and saw out, so that the facing will fit loosely. With a knife bevel the inner edge or seat for the facing (Fig. 566). Grind the facing to fit (Fig. 567). Back up the facing with No. 34 or 36 gauge pure gold, punching holes in the backing for pins, annealing as required to readily conform it to the tooth (Figs. 568 and 569).

With a sharp knife cut a barb on each side of the pins in the facing, and press the barbs against the backing (Fig. 570), which keeps the backing in place. Burnish down the edges well, being careful not to let the backing overlap the facing.

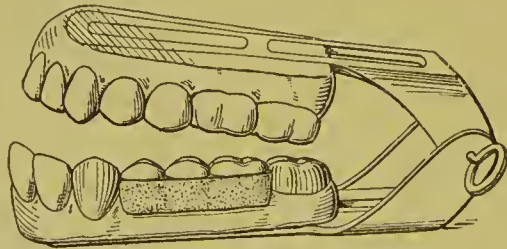
Place the facing in the space prepared for it in the crown (Fig. 571), and bind the two together (not too tight) with wire, wrapping the wire directly over the facing with asbestos to prevent discoloration of the porcelain. Flux and solder by holding over a lamp as in a case of a band (Fig. 572). Then finish in the usual way.

If it is desired to use a platinum pin for anchorage, as, for instance, a Logan pin, bend the pins in the facing sufficiently to clamp the anchorage pin, and insert the pin through the gold crown (Fig. 573), finishing as before described. Fig. 574 shows a finished crown so made.

#### TO MAKE THE GRINDING-SURFACE OF A BRIDGE IN ONE CONTINUOUS PIECE.

After having crowned the teeth for the attachment of the bridge, take a bite in modelling compound, remove the compound, place the crowns in their impressions, make a cast of

FIG. 575.



sand and plaster, and place on an articulator; now put moldine between the abutments instead of wax, and get the articulation with cusp-buttons the same as you would for plate teeth (Fig. 575). Then, to remove the buttons without destroying the articulation, make a cup by pouring Melotte's metal, as cool as it will flow, on the face of the cusp-buttons. Heat the pouring lip of the ladle and use it to smooth out the half-congealed metal, much as you would a soldering iron (Fig. 576). Then place a thin coating of moldine upon the molding plate. Re-

move the cup from the articulator with the cusp-buttons in place (Fig. 576, *a*). Transfer the cusps by inverting the molding plate (Fig. 577), and turn the cusp-buttons out upon the moldline on the plate with the grinding-surface up (Fig. 577, *a*), and they will occupy the same relative positions as when on the articulator.

Now place the large rubber ring around the buttons on the plate, and proceed to make a die with Melotte's metal, as before described (Fig. 578). When cool, remove the buttons and coat

FIG. 576.



FIG. 577.

FIG. 578.


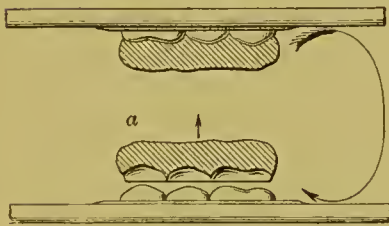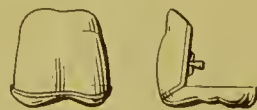
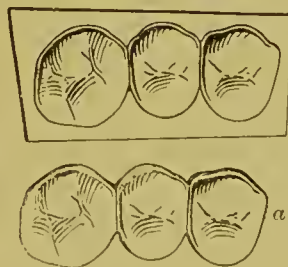
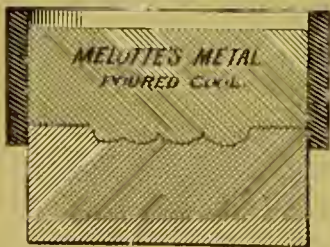

FIG. 579.

FIG. 580.

FIG. 581.



the face of the die with whiting. Invert the die and raise the rubber ring sufficiently high on it, and make a counter-die with the same metal by pouring as cool as possible (Fig. 579). This gives the male and female dies with which to swage the continuous grinding-surfaces. Then proceed to swage the gold plate in one piece (Fig. 580), annealing as often as necessary. Trim off the surplus plate (Fig. 580, *a*), and place in position on the articulator. Cut the cusps out on the buccal face to avoid showing the gold (Fig. 581), grind the porcelain facings

to fit the cusps, and back with gold, No. 34 or 36, letting the gold come to the cutting-edge, the same as in a single crown, as before described.

If there is a space between the cutting-edge and the porcelain, place a little wax in the joint to keep out the plaster investment, invest, remove the wax from between the joints, flux, and solder.

#### FACINGS FOR MAKING ALL-GOLD BRIDGE.

If it is desired to make an all-gold bridge, select the proper facings from the set, make a die of Melotte's metal, and swage up, the same as in the continuous bridge before described, and mount gold facings in place of porcelain.

## CHAPTER XVII.

### PORCELAIN BRIDGE-WORK.

PORCELAIN bridge-work consists of a base or framework of platinum covered with porcelain.

Porcelain bridge-work, owing to the unalterable character and continuity of its surface and the incorruptibility of the materials, has advantages as a denture when permanently inserted. In comparison with gold-work, its construction is less laborious, but its insertion and attachment to the abutments a more complex operation.

In practical application the scope of porcelain bridge-work is limited. This is owing to the fact that the occluding surfaces of the teeth forming the bridge are not—neither can they very well be—formed of or protected with metal. In close bites and where great force is exercised in the act of occlusion, unprotected porcelain is generally unequal to the strain.

#### DR. E. PARMLY BROWN'S METHOD.

*Construction.*—The bridge is formed by spanning intervening spaces between certain natural teeth or roots with artificial porcelain substitutes baked onto an iridio-platinum bar, or bar and plate; either or both ends of the bar being anchored in or to a crown, or in a filling inserted in the approximal portion of the adjoining tooth. The roots to be crowned and used as foundations for the bridge are prepared as for single crowns. If the end of the bar is to be fixed in a natural tooth, the cavity that is to receive and anchor it is opened up to properly admit it, as described on pages 174 and 177. A square bar of iridio-platinum wire, from No. 13 to No. 15, U. S. standard gauge in thickness, is fitted either to the cavities of the teeth in which it is to be anchored, or bent and fitted in any devitalized tooth or root

which is to act as an abutment. The end of the wire that forms the post is pointed and introduced well up the root-canal, and the end forming the bar is slightly flattened or squared. Any intervening root-posts are fitted and riveted to the bar as it passes above them. Caps of platinum are next formed for the ends of the roots (Fig. 582). This is done by adapting thin platinum plate to the ends of the roots in the mouth, then slitting the edges and bending them over the sides; or by fitting a collar around the root, slitting the edge, and binding it over the end of the root. The electric mallet can be used to aid the operation. The caps are perforated for the posts, cemented to them with wax, removed, and then soldered in correct position with pure gold. When the base of the bridge resting on the gums is formed entirely of porcelain, ordinary plate teeth<sup>1</sup>

FIG. 582.

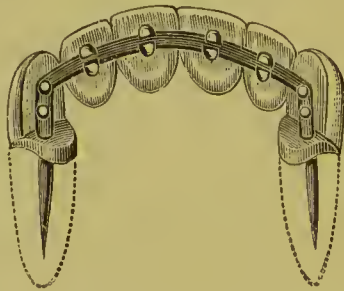
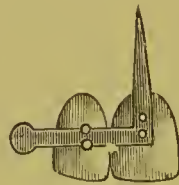


FIG. 583.



are to be used and fastened to the bar by slightly flattening the bar and riveting the pins firmly, or, when straight-pin teeth are used by bending the pins over the bar (Fig. 583); bicuspid and molar teeth with straight pins, by grinding a slot with a disk between the pins and bending them over the bar, which is slightly barbed and set in the slot.

The proper position of every tooth having been determined by adjustment in the mouth, or to the articulating model, the rivets and bar to each one are carefully filled around and the cervico-palatal portion rounded off with porcelain body so as to present a smooth surface to the tongue. The shape of the end of the root is given to the crown by placing the porcelain body,

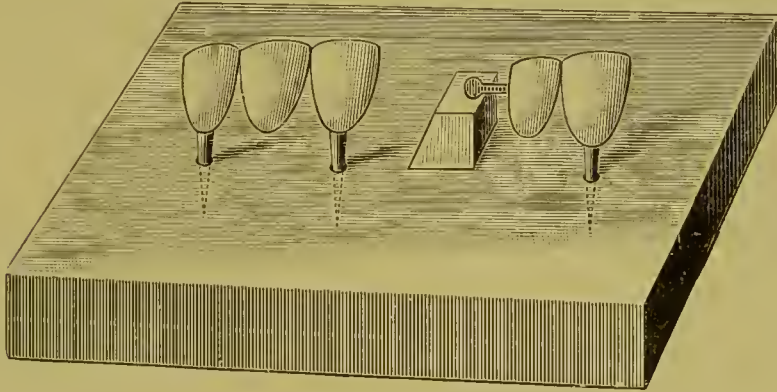
<sup>1</sup> Dr. Brown uses American teeth entirely for this work, as he has found them the most suitable, being the only kind that will retain their color in the intense heat to which they are subjected.



to which a small quantity of starch has been added, around the post as it is fixed in position on the model; the plaster having been previously varnished with eollodion to prevent cohesion. The spaces between the teeth on the line of the bar are to be substantially joined with the porcelain body; free spaces between the teeth at the cervical portion are to be preserved as much as possible without interfering with strength or producing places that will be uncleanly.

The bridge is then placed on a slide in the muffle of a continuous-gum furnace. It is sustained in position by inserting the pins in holes drilled in the slide (Fig. 584), or by suspending

FIG. 584.



it with platinum wire between two platinum posts inserted in the slab. The bridge is then baked the same as continuous-gum work. To assure density and strength the porcelain body should be thoroughly fused. It is next fitted to the mouth. If any alterations are required, they should be made; or if any imperfections in the body occur, the places should be filled in and the bridge again baked. It is then ready for insertion.

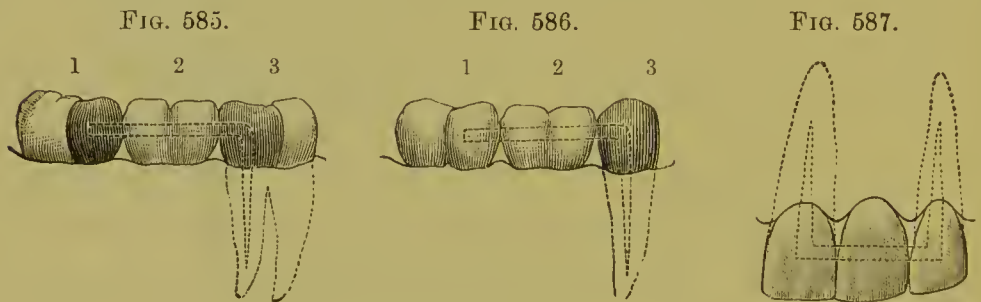
In porcelain bridge-work it is best to have the base of the bridge-teeth press firmly into the gum, instead of forming self-cleansing spaces. In cases of more than one bridge-tooth a preferable method of construction is to form the base of the bridge on a saddle or narrow plate of *iridio-platinum*. A space the size of the base of the teeth to be replaced is first marked on a plaster model of the case. The plaster is removed at the labial and palatal sides, gradually deepening to the edge of the

line of the space. This is to cause the margin of the plate to press in the gums. A metallic cast is then made, and an iridio-platinum plate Nos. 30 to 31 gauge struck up.

The teeth and bar are placed in position on the plate (in this case continuous-gum teeth are used); the pins of the teeth are bent over the bar on the plate and soldered to it with pure gold.

When one end of the bridge is supported by an all-gold crown on a tooth with a living pulp, the end of the bar is passed into the grinding-surface, or flattened and bent against the side of the gold crown and soldered to it. This is done by investing in asbestos and plaster and carefully heating up the porcelain before using the blow-pipe.

*Insertion.*—When the bridge is supported by crowns alone, the posts are barbed and the bridge is then cemented on, the same as



any other. If one end is supported by a porcelain crown and the other by a bar, the filling on the bar end is inserted up to the position the bar is to occupy before fastening the post of the crown end, which is then cemented and the filling of the bar end completed. (See "Bar-Bridges.")

In Fig. 585, No. 1 is a third molar, pulp alive, with large filling; No. 2 is a porcelain bridge; No. 3 is a first molar, pulp dead, with a metal bar entering the pulp-chamber.

In Fig. 586, No. 1 is a second molar, pulp alive, with a crown filling of gold or amalgam retaining the bar; No. 2 is a porcelain bridge; No. 3 is a gold crown with bar passing through one side of the crown into the root.

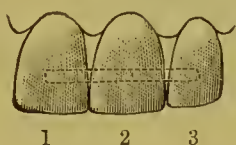
Fig. 587 is a view of a central incisor bridged onto two teeth whose pulps have been lost.

Fig. 588 is a view of an extension bridge consisting of a right

central and left lateral, supported by a left central tooth or crown as the case may be. The bar can be anchored in a filling in the natural crown or attached to the artificial one. Nos. 1 and 3 are teeth on a porcelain bridge; No. 2 the natural tooth or artificial crown on which the bridge is saddled.

Fig. 589 represents a bicuspid bar-bridge anchored in the molar and first bicuspid. The side cut shows the construction. Success in this and similar cases requires the absence of the occluding tooth, or at least a most favorable articulation.

FIG. 588.



1 2 3

FIG. 589.

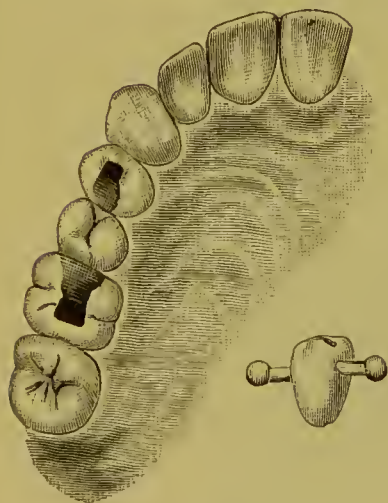


FIG. 590.

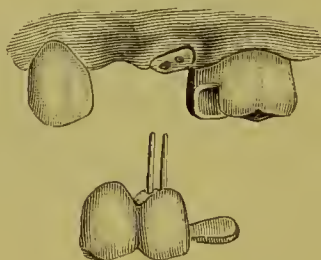


FIG. 591.

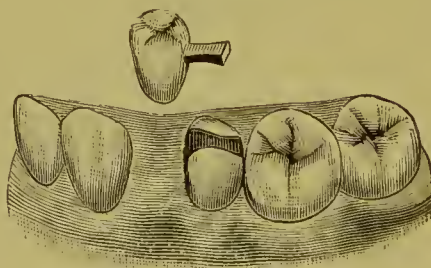


Fig. 590<sup>1</sup> represents an extension bridge in which the support consists of a crown and bar combined.

Fig. 591 represents an extension bar-bridge. The filling in the second bicuspid, which extended from the mesial to the distal side, had been inserted some time previously. Enough of the gold was removed from the mesial section of the filling to admit the bar, which was then securely anchored and the filling restored to its original form. The operation was per-

<sup>1</sup>Case of Dr F. P. Hamlet.

formed by Dr. Brown for Dr. F. P. Hamlet. The antagonizing teeth in the act of occlusion favored the bridge-tooth.

In porcelain bridge-work, should a case require it, artificial gum in a moderate amount can be formed above the teeth of

FIG. 592.

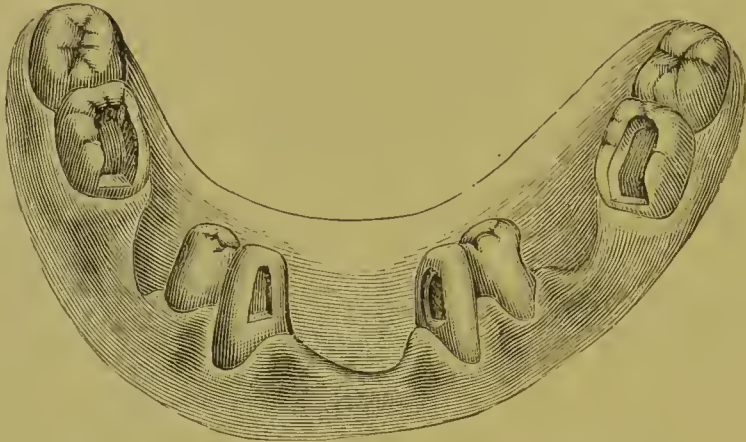


FIG. 593.

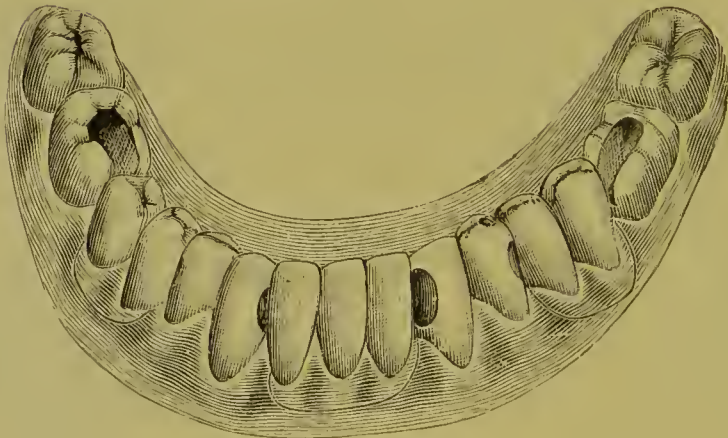


FIG. 594.



the bridge, to restore the contour of the parts. Figs. 592 and 593 illustrate a case of this character. A, Fig. 594, shows the labial and B the lingual aspect of the incisor bridge before insertion.

Figs. 595 and 596 represent a bridge of eleven teeth supported by a platinum collar porcelain crown on one cuspid root and three gold molar crowns. The bridge section is constructed on a narrow iridio-platinum plate which rests firmly on the gum.

The case in Fig. 597 is one of four incisors. The iridio-platinum bar was anchored in the palatal sides of the two

FIG. 595.

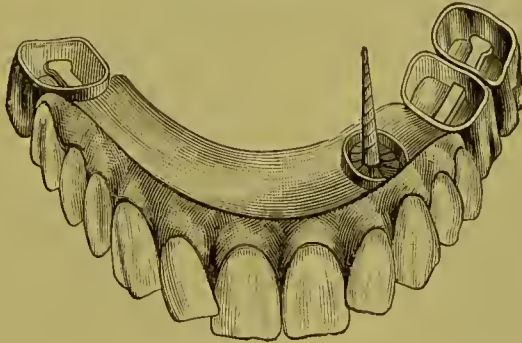
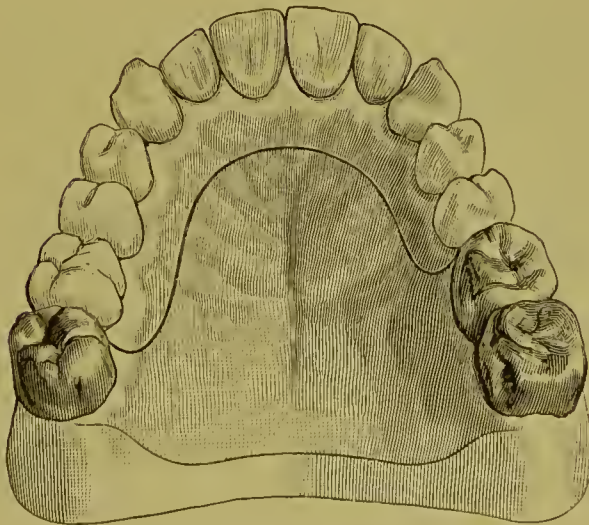


FIG. 596.



cuspid, the pulps of which were preserved. The first bridge—made on a bar without a plate—was temporarily worn nearly three years. A new bridge was then inserted, the temporary bridge being removed by cutting the gold of each filling only sufficiently to detach the ends of the bars. The new bridge, as illustrated, was made on an iridio-platinum plate with porcelain gum above the teeth to replace the portion of the natural gum

which was absorbed. When inserted, the ends of the bar were more deeply anchored than before, and then secured with additional gold, the pulps being still preserved.

FIG. 597.

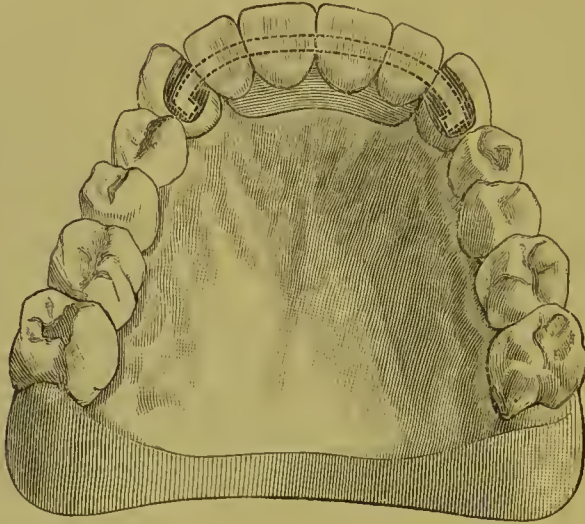
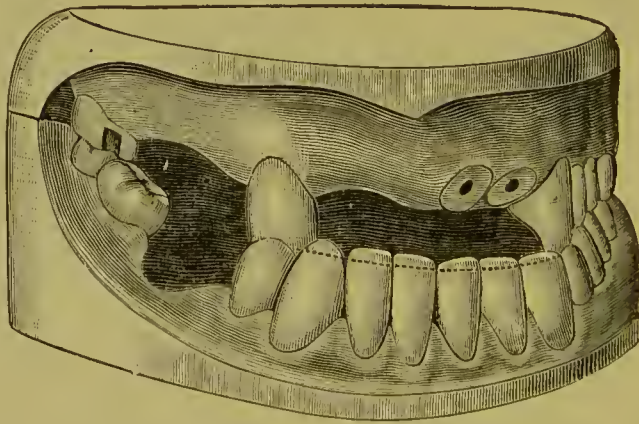


Fig. 598 represents a case by Dr. M. L. Rhein. To remedy the abnormal character of the occlusion, the lower anterior teeth

FIG. 598.



and the right upper cuspid were trimmed to the dotted line seen in the figure. To replace the missing teeth porcelain bridge-work was then constructed. The lateral and central roots, and the right cuspid and the molar, constituted the abutments. On the central and lateral roots were mounted caps with collars. A platinum crown was then made for the cuspid (Fig. 599),

and to this crown was attached the bar, which was extended to its anchorages in the molar crown and the lateral and central roots, the caps on the ends of which the posts pierced. Owing to the large quantity of porcelain body to be used in forming the artificial gum, a strip of platinum plate was extended above the bar to stiffen its projecting ends and prevent warpage in baking. The artificial teeth were then articulated to meet the incisive edges of the inferior natural teeth, and thus in a measure overcome the deformity caused by the abnormal occlusion. In doing this the labial aspect of the cuspid was covered by the

FIG. 599.

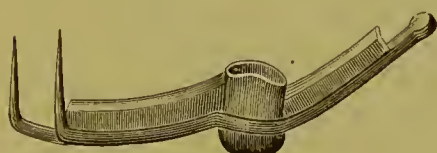


FIG. 600.

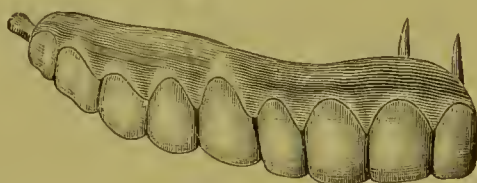
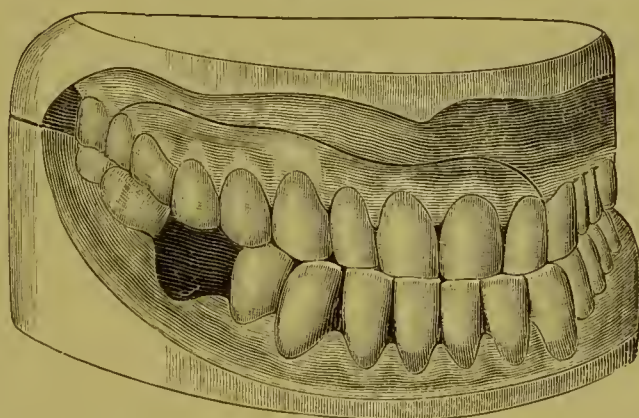


FIG. 601.



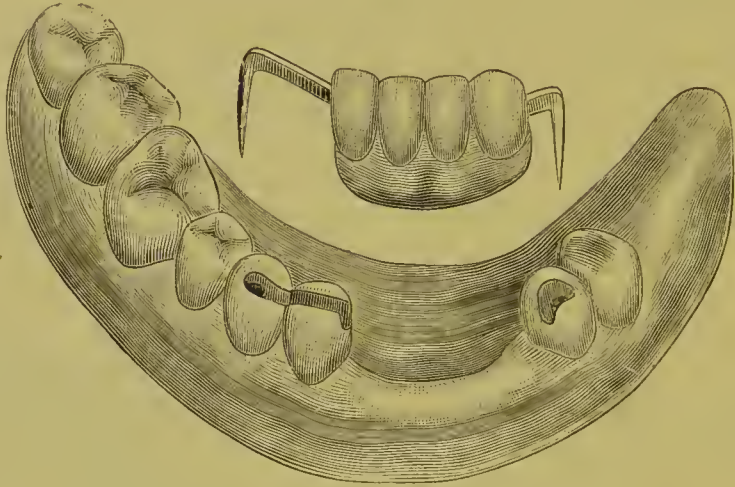
artificial teeth. Porcelain gum was then formed above the teeth in sufficient quantity to restore the contour of the parts. It was brought to a feather edge and pressed hard against all the tissues to insure a hygienic condition. Fig. 600 shows the finished bridge. In Fig. 601 the bridge is seen in position. The artistic result and improved appearance effected are at once apparent. The mechanical construction of the piece was intrusted to Dr. C. L. Andrews.

Fig. 602<sup>1</sup> is a lower bridge firmly supported on the right side

<sup>1</sup> Case of Dr. William Crenshaw.

by passing the bar through the cuspid and inserting the end in the pulpless bicuspid as illustrated. The pulpless bicuspid on the left constitutes the other abutment.

FIG. 602.



Porcelain bridge-work compares with other forms of bridge-work as continuous-gum work to gold-plate work. Its advocacy as a method though should be confined to such cases as properly suggest its practicability, respecting occlusion and other conditions, as previously mentioned. There is no other form of bridge-work in which success so much depends on proper application and skillful and expert construction as that of porcelain bridge-work.



## CHAPTER XVIII.

### CROWN- AND BRIDGE-WORK COMBINED WITH OPERATIVE DENTISTRY IN DENTAL PROSTHESIS.

IN crown- and bridge-work, artistic skill on the part of the operator can frequently be most advantageously displayed in the conduct of operations. An appearance of symmetry should as much as possible be imparted to the upper front teeth. The contour of the arch, the labial aspect and length of the teeth, singly and collectively, on one side of the mouth in comparison to those on the other, should be observed and studied. That most appreciable results are thus possible of attainment is demonstrated in the following two cases:

In the case presented in Fig. 603, that of a gentleman of about sixty-two years of age, is to be seen the irregularity of the teeth present and the unevenness of their incisive edges and occluding surfaces, the condition having arisen from the combined effects of decay, erosion, mechanical abrasion, and malocclusion. The operations performed were as follows: On the right side the second molar was restored by filling; the first molar and the bicuspid crowned with gold; the cuspid and central were lengthened with solid gold tips, each tip being anchored with three pins; and the lateral was crowned—at the request of the patient—with gold. On the left side the central was crowned with a gold crown with porcelain front, the cuspid shortened and filled on the palatal side, and the bicuspid crowned with gold and the spaces bridged.

Guided by a line at right angles to the median line (Figs. 603 and 604), the teeth and crowns on one side were formed to correspond as much as possible in length, shape, and appearance to those on the other. Those teeth affected with pyorrhea were treated. The results of these combined operations, conducted with a view to the artistic as well as the restorative effect, are plainly to be seen in the finished case illustrated in Fig. 604.

FIG. 603.

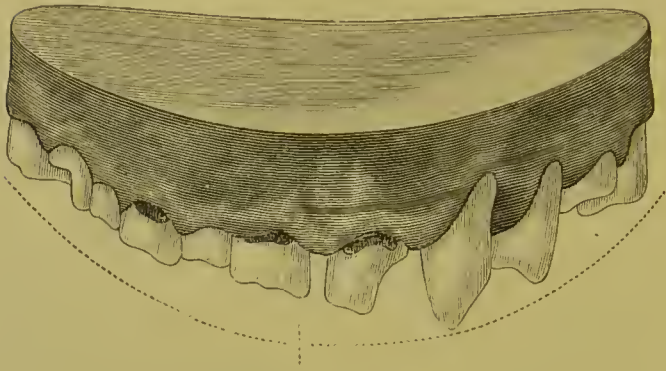


FIG. 604.

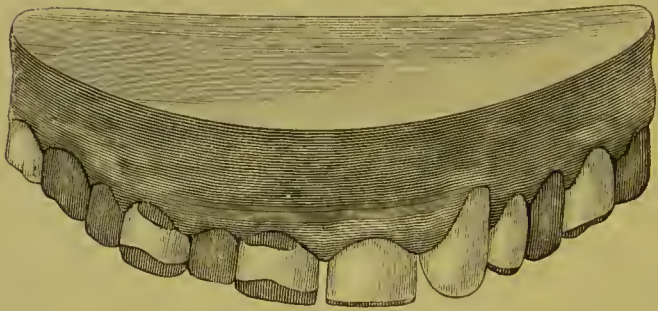


FIG. 605.

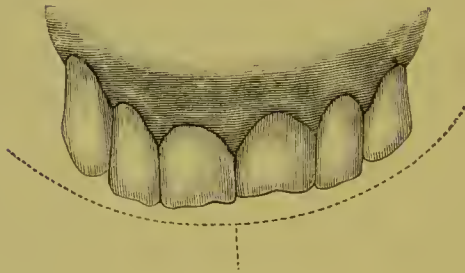
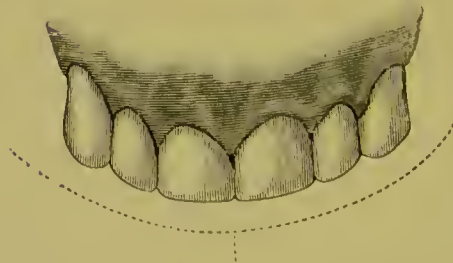


FIG. 606.



What can be quickly accomplished by judicious trimming and shaping of the teeth, in combination with other operations, is well illustrated in the following case. The patient's upper front teeth presented the appearance shown in Fig. 605. The right central and left lateral were pulpless. The central was badly discolored and the lateral slightly so. The central had been bleached, but in a few years gradually resumed its former appearance. The other teeth with living pulps and light in color contrasted most unfavorably. The incisive edges of the centrals were affected with atrophy. The laterals, especially the right one, were elongated from pyorrhea. The length of the incisors contrasted unfavorably with the cuspids. The patient, a lady, was so annoyed at the appearance of the teeth, which she considered a permanent disfigurement, that she had positively decided to have all the incisors crowned or extracted and artificially replaced. A most satisfactory compromise was effected, enabling the patient to avoid either of these extreme measures by the performance of the following operations: The pyorrhea was treated, the left lateral was bleached and refilled, the right central natural crown excised and an artificial one (style described on page 114) inserted, and the atrophied incisive edge of the left central removed and all the incisive ends of the other teeth trimmed to properly correspond in length and shape. The improvement effected is apparent in the illustration of the finished case, Fig. 606.

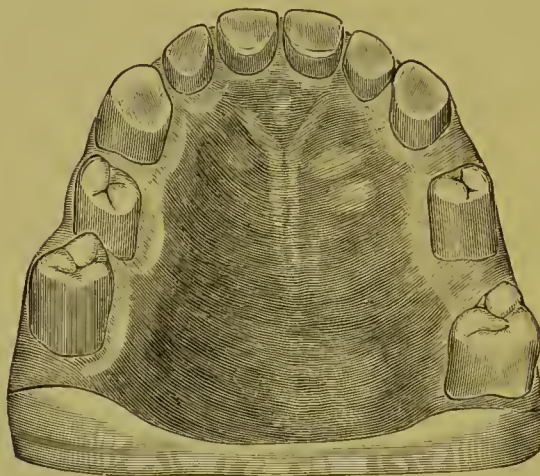The results in dental prosthesis which can be accomplished by a combination of operations on the natural teeth with crown- and bridge-work commend the plan strongly to the experienced practitioner. A few more cases are adduced in illustration.

A case which was interesting, owing to the conditions presented and the various operations connected with it, is illustrated in Fig. 607. Fig. 608 shows the methods and operations practiced, and Fig. 609 the case completed.

The upper front teeth show the effects of abrasion on the incisive edges and occluding surfaces. The bicuspid and molars were affected with pyorrhea alveolaris. The four incisors and the left cuspid were pulpless, and alveolar abscess existed at the

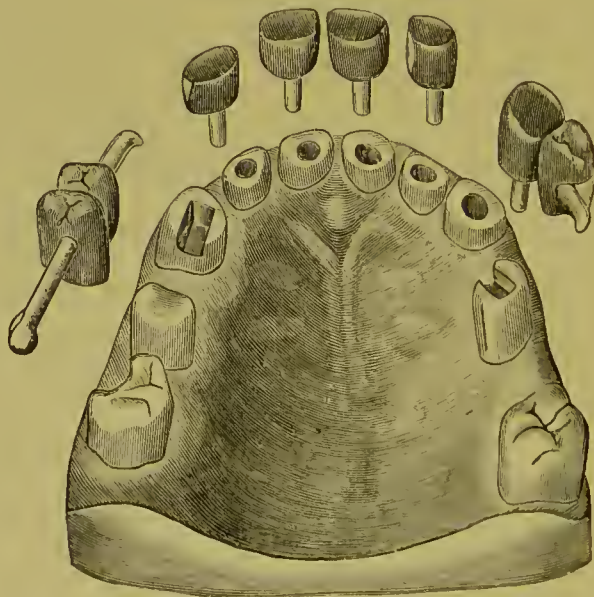
roots of three of the incisors. The abscesses and root-canals were properly treated. Gold collar crowns with porcelain fronts,

FIG. 607.



having flat incisive edges which perfectly protected the porcelain fronts and slightly opened the bite, were made for the incisors and

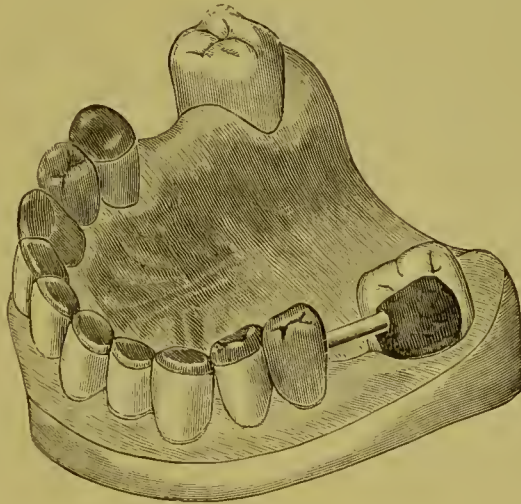
FIG. 608.



left cuspid (Fig. 608). The bicuspids and molars were placed in as hygienic a condition as possible by treatment. On the left side a dummy bicuspid with a bar which fitted in a slot formed

to receive it in the occluding surface of the second bicuspid was attached to the cuspid crown. When the cuspid crown with the dummy bicuspid was cemented in position, the bar was anchored in the slot in the second bicuspid with amalgam. The cuspid root being very firm, stability was thus imparted to the natural bicuspid, which was quite loose because of absorption of its socket. On the right side the second bicuspid was entirely capped with a gold seamless crown. On the anterior side of this gold crown an artificial tooth was attached as a dummy first bicuspid, with a bar extending from its anterior side and fitted into a slot formed in the incisive surface of the natural cuspid

FIG. 609.



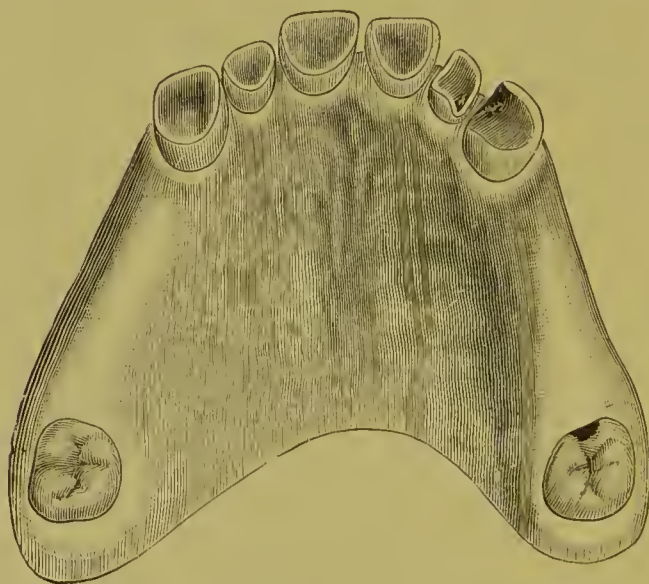
crown. From the posterior side of the second bicuspid gold crown a bar was extended backward into the side of the molar. When the gold crown was cemented in position on the second bicuspid, the anterior bar was firmly anchored in the cuspid with a gold filling, which also lengthened the incisive edge, and the posterior bar was fixed in the molar with amalgam. The reasons for this form of construction were : The second bicuspid was very loose in its socket, and the molar, though comparatively more stable, was also similarly affected. The attachment of the bar in the cuspid supported the dummy bicuspid and steadied the second bicuspid, and the extension of the posterior bar into the molar likewise afforded additional support to the bicuspid. The

pulp of the molar being exposed, was devitalized, removed, and the canal properly filled. Fig. 609 shows the completed case.<sup>1</sup>

The lower teeth, in comparison with the upper, were but slightly abraded. The cuspids and one of the incisors were tipped with gold. The molars on the left side were absent, so that bridge-work on the upper jaw on that side between the bicuspid and molar would have been to no purpose.

In the case presented in Fig. 610 the operative procedures were confined to the upper jaw, the lower teeth of the patient being in good condition. The bicuspids and the first and second molars of both sides of the upper jaw had been lost many years

FIG. 610.



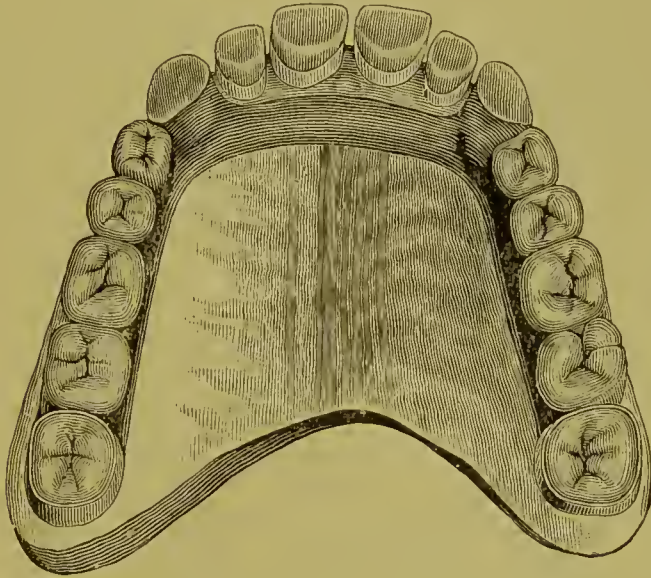before, and the incisors and cuspids showed the effects of extensive abrasion. The occlusion was sustained and the principal part of mastication performed by the incisors, as the third molars had been forced backward and antagonized only very slightly on one side.

---

<sup>1</sup> During the presence of the patient in the writer's office, four years after the work was completed, the operations were examined by members of the profession, and pronounced apparently in as perfect condition as when first completed. The treatment of the teeth affected with pyorrhea and the support imparted to them by their attachment to the other firm teeth and to one another had apparently checked the disease, and the affected teeth appeared to be more secure in their sockets than before the insertion of the bridge-work and crowns.

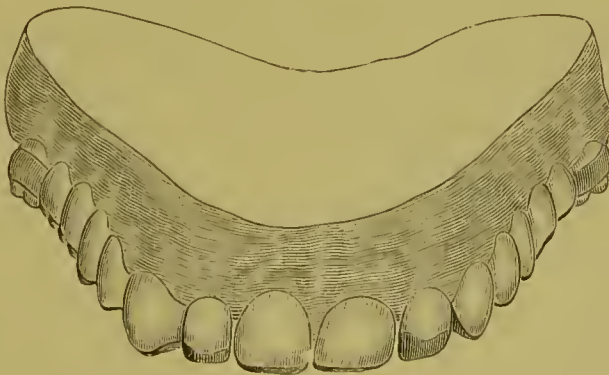
The patient, a gentleman, had had a plate inserted, to the presence of which he had vainly endeavored to accustom his mouth. The abrasion of the incisors and cuspids was of the rapidly progressive character. These teeth were contoured with gold foil to

FIG. 611.



the form shown in Fig. 612, and a wire post was inserted in the right lateral, which was pulpless. At the occluding section of each

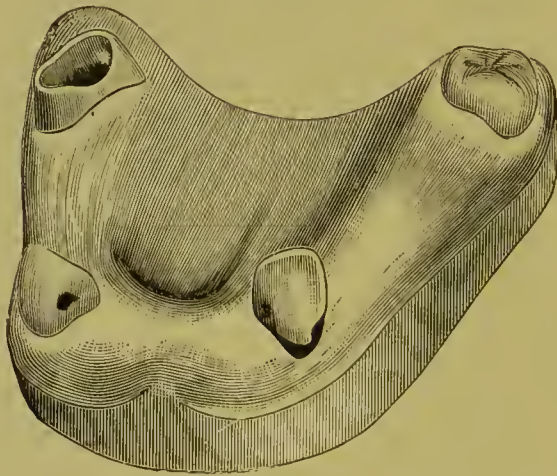
FIG. 612.



filling, the layer of gold, after being packed with the plugger, was additionally condensed and hardened with a Herbst agate-point burnisher to enable it to better resist the aggressive force

of the lower teeth. The third molars were capped and lengthened with gold crowns, the lines of their sides being made parallel, to admit of a proper adjustment of the supporting collars for a removable plate bridge, by adding gold on their external surfaces. The plate bridge was employed because of the space between the abutments, which suggested the idea of utilizing the alveolus to assist in supporting it. A narrow shoulder was formed on each crown to support the collars. The attachments to the cuspids rested by means of a little shoulder on the occluding portions of the fillings inserted. Fig. 611 shows the completed denture, and Fig. 612 an anterior view of the same.<sup>1</sup>

FIG. 613.



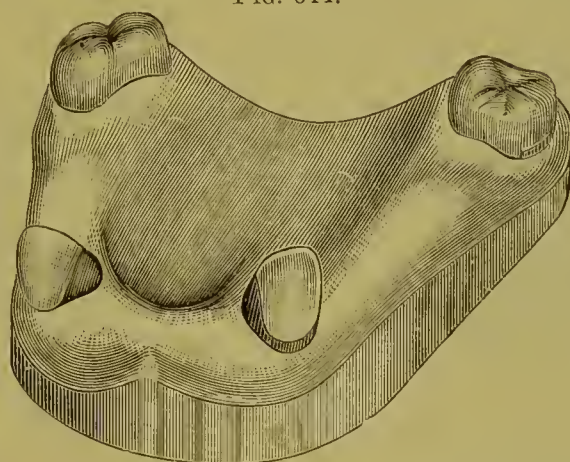
In the case illustrated in Fig. 613, the patient, a lady, had previously worn a plate, the clasp of which had entirely abraded the sides and cervix of the right cuspid of enamel, and caused recession of the margin of the investing gum. The decay which followed the abrasion extended in a circle around the tooth. As the patient objected to crowns of any kind being applied to either of the cuspids, the decay was removed and the edges of the cavity given a retaining form. A gold filling was then introduced in three sections, two of which embraced the approximal and palatal sides, while the third surrounded the labial wall, joining the other two sections at that point, the three thus completely encircling the tooth with gold. A portion of the filling was brought over the edges of the cavity to better shape the

<sup>1</sup> Case operated on in 1888.



tooth for the attachment to be applied, and also to protect the sides from future injury. When this operation was completed, the tooth presented very much the appearance of having had a close-fitting shell crown applied. Gold fillings were introduced

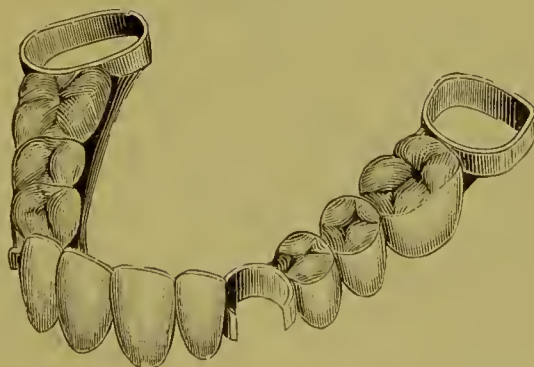
FIG. 614.



in the palatal and approximal surfaces of the left cuspid, to protect it from the attachment. Gold crowns were placed upon the molars, one of which, the left, was pulpless. The appearance of the teeth after these operations is shown in Fig. 614.

A plate bridge (Fig. 615) was then constructed, the attachments

FIG. 615.



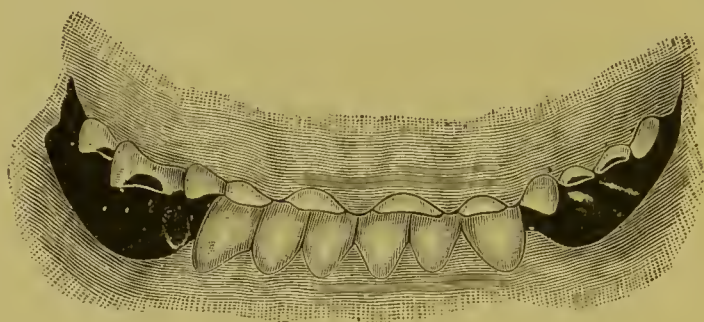
for which were collars on the molars, and half-collars or clasps on the euspids. The former rested on shoulders formed on the gold crowns, and the latter on the palatal curves of the euspids.<sup>1</sup>

Fig. 616 illustrates a case as presented for treatment to Dr.

<sup>1</sup> Case operated on in 1889; appliance still worn by the patient.

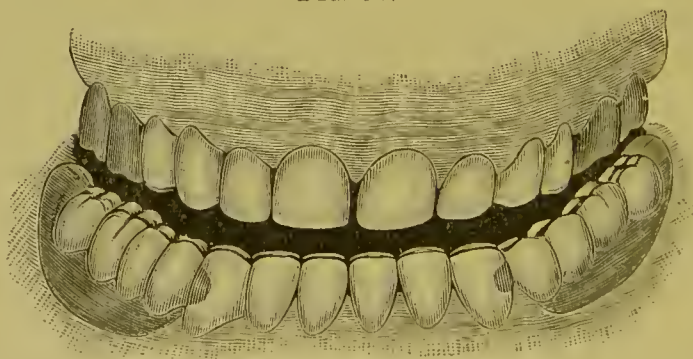
H. A. Parr. The loss of the posterior teeth of the lower jaw and the abrasion of the anterior teeth had resulted in the abnormal occlusion shown. The incisive edges of the lower teeth were lengthened with gold contour fillings. Gold collar crowns with porcelain fronts were placed on the upper anterior

FIG. 616.



teeth, to lengthen them sufficiently to restore the occlusion. The upper molars, which were all more or less decayed and broken down, were restored in form with gold crowns. The space representing the loss of the left bicuspid was filled with a bridge tooth having a porcelain front, attached to the approximal gold crown. In the lower jaw a partial set was inserted on each side to substitute the lost posterior teeth. Fig. 617 shows the appearance of the case when completed.

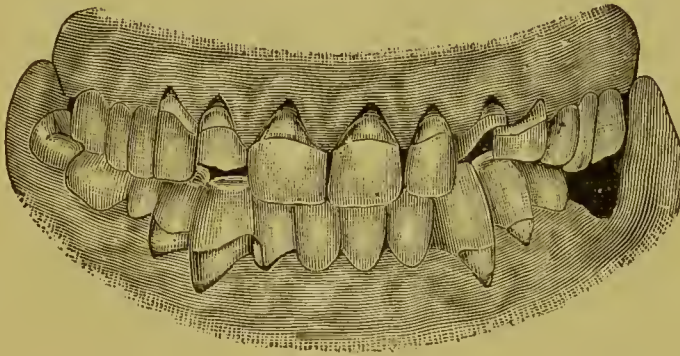
FIG. 617.



The following case is a marked illustration of extensive contour filling combined with gold and porcelain crown-work. The operations were performed by Dr. E. P. Brown, with the exception of the porcelain inlays, which were inserted by Dr. C. H.

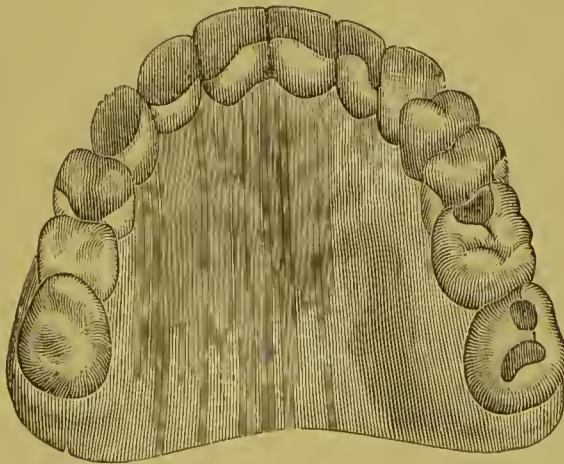
Land. Fig. 618 represents the case before treatment. The teeth show the effects of erosion, abrasion, and decay. The upper teeth at the incisive and palatal portion were contoured with rolled gold, No. 60, condensed with the Bonwill electric mallet.

FIG. 618.



A porcelain crown was placed on the root of the left cuspid, and a gold crown on the first left bicuspid. The eroded, decayed, and abraded portions of the other bicuspids were contoured with

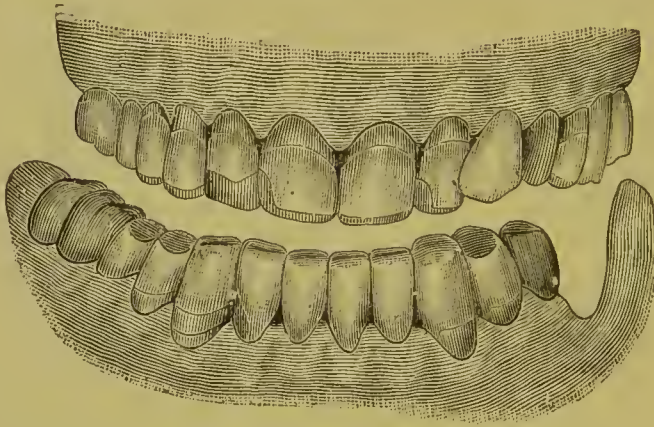
FIG. 619.



gold. The treatment of the lower teeth consisted in contouring with gold the abraded occluding surfaces of the right first and second bicuspids and left first bicuspid. The left second bicuspid and two right molars were crowned with gold. The cervical decay which affected the inferior right lateral, cuspid, and first

bicuspid and left cuspid was removed and inlaid with sections of porcelain colored with gum enamel at the line of the gum-margin by Dr. Land. Fig. 619 shows the superior arch from

FIG. 620.



the palatal aspect when completed. Fig. 620 is a labial or front view of the finished case.<sup>1</sup>

---

<sup>1</sup> The patient, Dr. W. I. Thayer, exhibited these operations, then nearly completed, at the clinic of the First District Dental Society of New York, February, 1889.

PART IV.

---

MATERIALS AND PROCESSES USED IN CROWN- AND  
BRIDGE-WORK.



## CHAPTER I.

### PLATES AND SOLDERS.

*Plates.*—In the construction of crown- and bridge-work, gold, platinum, or iridio-platinum is used in the following forms and grades in carat, as suits the requirements of the case and the preference of the dentist:

Gold plate, 24 carats, from No. 28 to No. 30 U. S. standard gauge,<sup>1</sup> for constructing the collars and caps to collars of crowns and seamless crowns, and for backing porcelain fronts.

Gold plate, slightly alloyed,—about 23 carats fine,—in crown-work, if less flexibility of the metal is required.

Gold plate, 22 carats, No. 28 to No. 30 standard gauge, in constructing collars for crowns with porcelain fronts and all-gold crowns made in sections.

Gold plate, 20 carats, in construction of bridge-work.

Gold for constructing collars should be of as high a carat as possible, to better resist the action of acids. A large proportion of copper as an alloy is objectionable, owing to its tendency to cause tarnishing of the collar where an acid condition of the saliva exists. For this reason, United States gold coin, containing 10 per cent. copper, so much used for collars, is not quite suitable. It is also too stiff, and collars made of it are not readily burnished to fit at the edges. Dr. J. J. R. Patrick's formula, which is equal parts of coin and pure gold, affords a plate which is decidedly preferable, inasmuch as the proportion of copper is reduced to 5 per cent.

Gold plate, 24 carats, with a very thin lining of platinum or iridio-platinum plate, can be used in any of the processes con-

---

<sup>1</sup>The United States standard is the only gauge referred to in the original descriptive matter of this treatise.

nected with crown- and bridge-work, and is especially recommended to the inexperienced, for the reason that the melting of a part of a crown in the soldering process is prevented by its use. It is formed by placing together an annealed gold plate and a platinum plate (the gold about No. 20 gauge and the platinum No. 30) and passing them through a rolling-mill, in which process the plates are welded and reduced to the desired thickness.

Platinum and iridio-platinum plate are used for forming crowns for use in connection with porcelain bridge-work. Platinum plate for forming collars need not be over No. 30 to 32 gauge. At this thickness it can be easily adapted to the cervix of the tooth.

Pure platinum rolled very thin is used for forming caps to collars, backing teeth, and for various purposes connected with this class of operations. Iridio-platinum wire is used for pivots, pins, or posts, being more rigid than pure platinum. A wire of gold and platinum alloy is used on account of its elasticity for split or spring pivots or posts in removable bridge-work.

*Solders.*—Gold solder, 18 and 20 carats fine, is used for crowns and bridges, but 18 is considered by some too low a carat.

14 carats for strengthening seamless crowns; used only in crowning operations.

Successive grades of solder from hard to easy flowing can be used in the regular soldering of crown- and bridge-work; gold plate or a hard-flowing solder for the first, a medium-flowing solder for the next, and an easy-flowing one for the finish. This avoids melting or flowing of the gold at any point previously soldered.

Any grade of solder can be made according to the following formula :

Zinc,  $1\frac{1}{2}$  grs.;  
 Pure gold,  
 Silver solder, in quantity sufficient to make up the  $22\frac{1}{2}$   
 remaining parts in weight.

The quantity of silver solder used will regulate the grade in carat of the solder. Thus :

Zinc,  $1\frac{1}{2}$  grs.;  
 Pure gold, 20 grs.;  
 Silver solder, 3 grs.,



will, by the burning out of a portion of the zinc in the process, make a solder about 20 carats fine.

By lessening the proportion of zinc from  $1\frac{1}{2}$  grains to 1 grain, the proportion of silver solder being kept the same, the solder will become harder-flowing and a little finer.

Dr. W. H. Dorrance recommends the following formula as an alloy for the formation of different grades of gold solders, the proportion of the alloy used determining the melting-point and fineness in carat of the solder :

1 part pure silver ;  
2 parts pure zinc ;  
3 parts pure copper.

The silver and copper are first melted together in a crucible lined with borax, and the zinc added quickly in small pieces, stirring the mass meantime with a pipe-clay stem. It is then, on the fumes of the zinc passing off, immediately poured into an ingot-mold or into a large wooden pail filled with water ; 4 grains of this alloy melted with 20 grains of pure gold will result in a solder fully 20 carats fine.

As a solder for crown- and bridge-work constructed of 22-carat gold plate, Dr. Litch's formula is as follows :

Gold coin (ten dollars), 258 grs. ;  
Spelter (or brazier's solder), 24 grs. ;  
Silver coin, 24 grs.

This is a proportion of about 26 grains of pure copper and 232 grains of pure gold to the remaining 48 grains of the alloy, and makes a good solder a little over 18 carats fine.

Dr. C. M. Richmond originally used American gold coin for forming gold crowns, rolling it out in the form of plate. The scraps he formed into solder by melting and adding one-fifth of their weight of fine brass wire cut in small pieces, using plenty of borax.

Dr. Low's formula for solder in bridge-work is :

1 dwt coin gold ;  
2 grs. copper ;  
4 grs. silver.

This makes a solder about 19 carats fine.

The following formula<sup>1</sup> gives a 20-carat solder which is specially recommended for crown- and bridge-work :

American gold coin (21.6 carats fine), \$10 piece, 258 grs. ;  
Spelter solder, 20.64 grs.

*Fluxed Solder Filings.*—Fluxed gold solder filings are made by filing with a clean, flat plate file a thick piece of solder held in a vise. The filings are allowed to fall in a box or on a sheet of paper placed to receive them. A magnet should be passed through the filings to remove any minute particles of steel. To five parts of the filings so made is added and well mixed with them one part of the prepared flux or finely pulverized vitrified borax. Solder prepared in this way is useful for strengthening crowns, and also in fine soldering operations, as the particles of the solder take the heat separately and fuse much more quickly than when the solder is cut in pieces. The flow of the solder is also more easily limited.

---

<sup>1</sup> American System of Dentistry, vol. iii, p. 849.

## CHAPTER II.

### PORCELAIN TEETH.

THE qualities specially requisite in the body of porcelain teeth for use in crown- and bridge-work are density, strength, and the ability to withstand unaltered in form or shade any degree of heat to which they may necessarily be subjected. In these respects the porcelain teeth of our best American manufacture seem to excel, besides affording the most artistic imitation of the natural teeth in form and shade. They are also distinguished by the practical location of the pins.

In some crowning operations, where to imitate the conformation of a natural crown considerable alteration of the labial surface of a porcelain front is required, teeth of English manufacture may be used, as the texture of the porcelain more easily permits a polish being given to a ground surface.


Teeth are sometimes fractured in the process of soldering, caused by the contraction of the backing when adapted over the edges of the porcelain in a curve instead of at a right or slightly obtuse angle, or by melting solder on some point of the porcelain which is unprotected by a backing of metal. The solder, or the borax, as it cools, contracting on the porcelain, or a very thin edge of the metal covering it, will usually cause a fracture. The porcelain tooth has yet to be made that will, as a rule, endure such extreme treatment without breaking.

## CHAPTER III.

### MOLDS AND DIES.

METALLIC models of fusible metal can be easily and quickly formed for use in crown- and bridge-work. The melted alloy can be poured into a plaster, moldine, or gutta-percha impression taken in a tube or impression-tray. A

FIG. 621.



piece of copper plate or of an old separating file, placed between teeth as shown in Fig. 621, and removed in position in the impression, will accurately outline the space between the teeth in the metallic model. When a tube is used, a strip of paper should be wound around it to lengthen the die.

The following fusible alloys of tin are suitable for the purpose :

PROPORTIONS OF METALS.			MELTING POINT OF THE ALLOY.
Tin.	Lead.	Bismuth.	Fabr.
1	2	2	236°
5	3	3	202°
3	5	8	197°

Dr. G. W. Melotte, of Ithaca, N. Y., to whom is accorded the credit of introducing the use of fusible metal and the compound called "moldine" into crown- and bridge-work, gives the proportions of his alloy in parts as—

Tin, 5 ; Lead, 3 ; Bismuth, 8.


Dr. Melotte's moldine, a preparation compounded of potter's clay and glycerin (to which, when needed to soften it, more glycerin can be added), is very useful in molding.

#### HOW TO QUICKLY MAKE A TUBE AND FUSIBLE METAL DIE.

Take a thin strip of copper plate, at least 35 gauge, anneal, and bend it around the tooth in the mouth or its form on the plaster

model. Both ends of the copper at the part lapped are next cut, as shown at A, Fig. 622, and turned over tight and close in the manner seen at B. This fastens both ends of the copper, which when trimmed off at C, forms a tube. In this tube, with a little impression compound, gutta-percha, or moldine, take an impression of the natural crown either in the mouth or from the plaster model by trimming around the tooth or by separating it from the rest of the model. Encircle the tube with a strip of paper. Hold the paper and tube with a clamp. Melt and pour the fusible metal moderately cool, and immerse tube and metal in water. This gives a die with a long narrow shank, which may require to be trimmed at the neck with a file. When impression compound or gutta-percha are used, cool and then dry the surface with an air syringe before pouring the fusible metal.

FIG. 622.

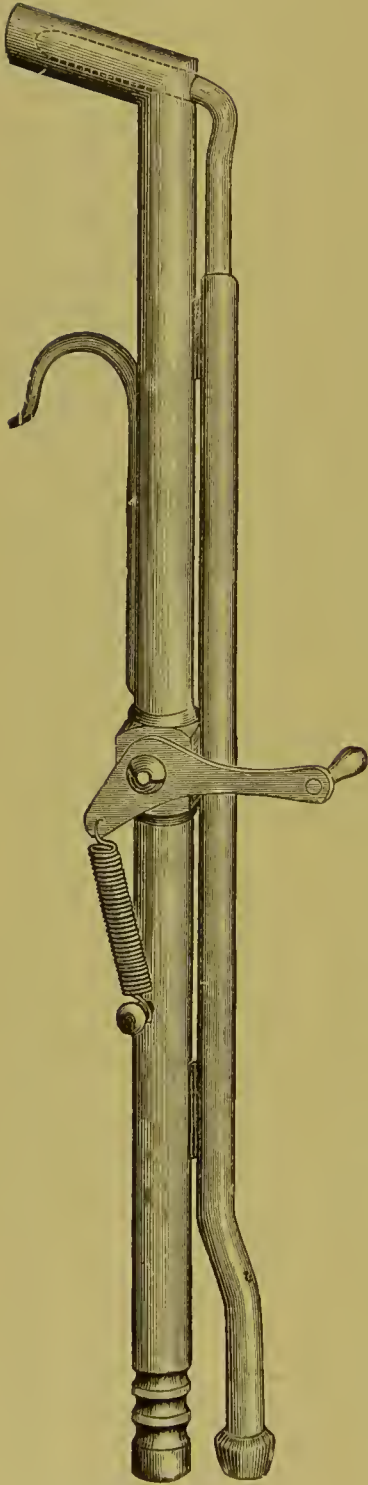


A counter-die to a small cast or die of fusible metal is made by indenting a block of lead with a punch, and then driving the cast or die into it. Its use in crown-work is described on pages 82, 90, and 94.

Dr. Melotte has introduced for special cases a novel method of forming a combination plaster and metal model, in which the parts representing the teeth are of fusible metal. The following is a description: The impression is taken in plaster. Iron pins to act as dowels are placed in the molds of the teeth. Pieces of a fusible metal which melts at a low point are then melted into each of the molds with a few puffs of the blow-pipe. Plaster is then poured in the remainder of the impression. The advantage afforded by a model of this kind, when gold attachments or clasps are to be shaped to teeth, is obvious. The method applied in the construction of bridge-work is given on page 151. Dr. Melotte's formula for the fusible metal used in the above method is:

Bismuth,	8 parts ;
Lead,	4 "
Zinc,	3 "
Cadmium,	2 "
Melts at about 150° F.	

FIG. 623.



## CHAPTER IV.

### SOLDERING.

*Models and Investments for Soldering.*—Models on which the soldering is to be done for bridge-work are made of calcined marble-dust and plaster, in the proportion of equal parts.

*For small investments*, such as single crowns, 2 parts calcined marble-dust and 1 of plaster.

*For large investments*, including pieces of bridge-work, 1 part calcined marble-dust, 1 part common white sand, and 1 part plaster. The reason for the use of the latter proportions is that the sand prevents the excessive contraction that is liable to take place in large masses of investing material entirely composed of plaster and marble-dust when subjected to great heat for a considerable time. The marble-dust in combination with sand renders the material more suitable to fill interstices and the insides of caps. In cases of bridge-work of any great size, a loop of iron wire should encircle the piece in the investment. Sulfate of potassium, used in place of common salt, but in smaller quantity, will cause the mixture to set quickly and hard.

*Soldering.*—When it is desired to remove the wax cement connecting sections of a crown or bridge in an investment before heating, it should be done

by pouring boiling water on the parts. It is not advisable to remove the wax with an instrument, as parts delicately held in position are liable to become displaced. Many prefer to leave the wax burn out of the investment as it is heated. This is always done when fluxed wax is used, and the benefit of the flux is to be obtained. The objection to burning out wax is that pits are more liable to be found afterward in the solder.

In soldering crown- and bridge-work or sections of it containing porcelain fronts, the investment should be first uniformly and thoroughly heated. A full flame should be directed against and under the investment, and the heat uniformly raised to a temperature that will melt the solder without pointing the flame. This is especially necessary in the soldering of gold crowns with porcelain fronts, also dummies, as the solder if the investment is properly placed flows by gravitation into the interstices between the porcelain and the caps, and gives continuity of structure to the crown. When the solder has filled the interstices, the flame may be pointed for a moment to guide it to some desired point.

A large piece of charcoal, concave on the side to be used, and the other side invested with a thin covering of plaster, furnishes a good soldering support, as it retains the heat. A hand gas blow-pipe, operated by a foot bellows, and so constructed that the flame is under perfect control, is the most suitable (Fig. 623).

*The Use of Borax.*—In soldering invested sections of crown- or bridge-work, borax which has been reduced to a vitreous state by heat and then finely pulverized is the preferred form for use. Prepared in this manner it should be sprinkled on the part previous to the commencement of the soldering, and a little added at any time it is needed during the continuance of the process.<sup>1</sup>

In small, fine soldering of invested or uninvested work, the lump borax ground with water on a slab to a cream-like consistency and applied with the point of a stick or brush only where it is desired to have the solder flow, is the most suitable.

---

<sup>1</sup> Dr. Parr's "prepared flux," a finely pulverized vitrified flux, can be used in this manner. It is also prepared in combination with wax cement. In the melting out of the wax when the case is invested and heated for soldering, the flux is carried into the interstices.


## CHAPTER V.

### INSTRUMENTS AND APPLIANCES.

THE dentist who intends to engage extensively in crown- and bridge-work, and who desires to practice it conveniently and successfully, should supply himself with all the necessary instruments, tools, and other appliances. These consist principally of:

Suitable drills and burs, including three or four sizes of the Gates-Glidden for root-canals; root-trimming and shaping in-

FIG. 624.



struments, Gem and corundum wheels and points, and rubber and corundum disks (see page 36).

Pliers for shaping collars (see page 68), and a pair of excising forceps.

Soldering clamps (see page 83) and hand-vise.

Small-pointed shears.



Round and half-round plate files, very finely cut.

A small anvil.

Bunsen gas-burner and spider attachment for heating investments for soldering.

A gas blow-pipe with bellows, and a mouth blow-pipe.

Charcoal soldering block.

Calcined marble-dust.

Sulfate of potassium.

Melotte's moldine and fusible metal.

Wax cement (resin two parts, wax one part), or Parr's fluxed wax.

FIG. 625.



Dies for forming gold caps for use in constructing crowns and capping dummies.

Copper plate Nos. 34 to 35 gauge, copper wire No. 30 gauge, fine coppered iron binding wire, and heavy iron wire to encircle investments.

Pure gold plates Nos. 28 to 30 gauge, 22-carat gold plate Nos. 28 and 30 gauge, and 18- and 20-carat gold solder.

Platinum plate Nos. 30 and 32 gauge for collars, both heavy and very light platinum foil for backings, and some iridio-platinum wire Nos. 15 and 17 gauge for posts, and fine platinum wire for pins in either gold tips or crowns.

A small assortment of cross-pin plate teeth of light, medium, and dark shades, consisting of incisors, euspids, and a few bi-euspid and molar fronts for dummies.

A small rolling-mill for plate will be quite an acquisition, as gold scraps can be remelted and formed into plate.

The bench on which the principal parts of the work are done should be specially designed and reserved for it. It should be in the same room, and conveniently situated a little behind the dental chair, out of view of the patient. Everything connected with this bench should be kept in order and ready for immediate use. Such a bench, made of black walnut, with a top that can be closed when not in use, making an unobjectionable piece of furniture, is represented in Figs. 624 and 625.

An office lathe should be kept next to the bench, or a small lathe-head can be mounted on the bench and operated by the aid of an electric motor.

# INDEX.

- ABRASION of incisive edges of teeth, 89.  
method of forming crown for, 88, 105, 203, 248, 305, 307, 311, 314.  
method of forming tip for, 127.
- Abscess, chronic alveolar, treatment of, 31.
- Acid, arsenious, its use and action in devitalizing pulps, 18.
- Acid secretions, platinum unaffected by, 92, 111.
- Adaptation of gold collars, 72, 100.  
of porcelain crowns, method of, 45, 56.
- Adjuster for use in cementation of crowns, 135.
- Adjustment of finished bridge-work in the mouth, 159.
- Adjustment of seamless crowns, 99.
- All-gold bridge-work, 164, 294.
- All-gold collar crowns, 81.
- Alloy for forming any grade of gold solder, 320.
- Alloys of tin, their use in crown-work, 324.
- Alveolar abscess, classification of, 31.  
treatment of, 31.
- Amalgam, use of in bridge-work, 176.  
in crown-work, 40, 48, 139.
- Ames's method of forming gold tips, 127.
- Amputation of the apex of a root, 34.
- Analysis of dentine, 12.
- Anatomical structure of dentine, 10.
- Anchorage bars in bridge-work, 150, 155, 164, 175, 184, 295, 308.  
manner of attaching to the abutments, 150, 159, 176, 178, 179, 184.  
manner of forming, 150, 176, 178, 267, 295, 309.
- Anchorage or abutments for bridge-work, preparation of, 148, 167, 170, 172, 173, 175, 178, 179, 180, 184, 188, 191, 193, 254, 295, 308.  
Dr. Litch's method, 246.  
Dr. Winder's, 243.  
shell, 167, 191.
- Ancient bridge-work, 143.
- Anesthesia in pulp-extraction, 16.
- Anesthetics, local, for application to gum, 33, 35, 73.  
use of in crown-work, 73.
- Antagonizing teeth, preparation of their cusps, 39.
- Antiseptic agents in treatment of alveolar abscess, 32, 34.  
in treatment of pulpless teeth, 25.
- Anvil, use of in crown-work, 72, 102.
- Aristol, use of in pulp-canal, 26.
- Arsenious acid, use of in devitalization of the pulp, 17, 18.
- Articulation for bridge-work, manner of taking, 150.
- Artificial crown-work, 5, 43.  
the gold system, 67.  
the porcelain system, 44.
- Artificial gum in porcelain bridge-work, 235, 300, 303.
- Attachments for removable bridge-work, 213, 230, 243, 264, 267, 313.
- BACKINGS for porcelain fronts in crown- or bridge-work, 75, 163, 165, 184, 320.
- Baldwin's method of mounting crowns, 63.
- Bar bridge-work, 150, 163, 164, 174, 175, 195, 247, 267, 296, 308.  
advantages of, 179.  
anchoring of the bar, 175, 176.  
cast filling to support, 176.  
extension, 170, 187.  
in bicuspid and molars, 171, 172, 173, 174.  
in incisors and cusplids, 170, 172, 187.
- Bars for bridges, 127, 155, 176, 260.
- Beers's crown, 67.
- Bing's bridge-work, 144.
- Blind abscess, treatment of, 32.
- Blow-pipes, Lcc's, 326.  
Knapp's carbo-oxyhydrogen, 276.
- Bonwill, Gates-, porcelain crowns, 45.
- Bonwill's removable plate bridges, 264.
- Borax, method of using in crown- and bridge-work, in constructing root-caps and tubes, 214, 327.
- Bridge-work, 143.

- Bridge-work, adjustment and insertion, 159, 169.  
 an impartial criticism of, 145, 173, 210.  
 as affecting hygienic condition of the mouth, 210.  
 cantilever, 174.  
 cases illustrating the application of, 187, 305.  
 cementation of, 133, 159, 169.  
 construction of, 148, 159, 187, 295.  
 detachable, 136, 138, 238.  
 extension, 170.  
 extensive application of, 197.  
 foundations for, 148.  
 general application of, 187.  
 how to cement any form so it is easily removed, 136, 138.  
 manner of taking impression and articulation for, 150, 155, 159, 171, 223, 224, 226, 325.  
 mechanical principles governing the process of construction, 148, 174, 175.  
 method versus to forming self-cleansing spaces, 154.  
 methods in pyorrhea, 188.  
 partial cap and pin, 172, 193.  
 plate, 230, 297, 311.  
 porcelain, 295.  
 removable, 219, 243.  
 removal of, 208.  
 selection of abutments, 148, 173.  
 Bryant's method of repairing fractured porcelain fronts, 207.
- CANTILEVER bridge-work, 181.  
 crown, 123.
- Cap for collar, to construct, 81, 82, 85, 288.
- Cap for porcelain crown, 59, 113, 119.
- Cap for porcelain fronts for bridge-work, 85, 154.
- Capping pulps, methods of, 13.
- Cast fillings, 127.  
 to support bridge-work, 127, 179.
- Cataphoresis, use of, 16, 73.
- Cement, 133.  
 to cause oxyphosphate to adhere to tooth-structure, 169.  
 to cause to set slowly, 135.
- Cementation of crown- or bridge-work, 135, 137, 159, 169.  
 to be easily removed, 136, 138.
- Chronic alveolar abscess, 31.
- Circulation in dentine, 10.
- Clamps, soldering, 70, 82, 84, 163.
- Cleansing of bridge-work when worn by patients, 210.
- Cocain, use of, 16, 18, 35, 73.
- Collar contractor, 72, 103, 280.
- Collar crowns, 67.  
 Collar crowns, bicuspid and molars, 77, 81, 93, 96.  
 hygienically considered, 58, 111.  
 incisors and cuspids, 59, 74, 88, 107, 289.  
 Collar expander, 72, 101.  
 Collar pliers, 68, 101.
- Collars, method of adaptation of seamless crowns, 99.  
 to solder, 70, 75, 82, 104.
- Collars for crowns, 68, 319.  
 construction and adaptation of, 59, 68.  
 Townsend's fusible die in forming, 59.
- Connecting bars in bridge-work, 165, 187, 188, 225, 258.
- Construction of bridge-work, 148, 159, 162, 187.  
 bar, 148, 159, 187.  
 detachable and removable, 212, 230, 243.  
 mechanical principles governing, 148, 173, 202.  
 plate, 230, 259.  
 saddles, 171, 173, 226.  
 small pieces of, 159, 187.  
 special processes and appliances in, 162.
- Corundum-wheels and points, 36.
- Criticism of crown and bridge operations, 58, 111, 172, 174, 175, 182, 197, 202, 203, 210, 295, 304.
- Crown- and bridge-work combined with operative dentistry in dental prosthesis, 305.  
 instruments and appliances, 328.
- Crowns, artificial:  
 Baldwin's method of mounting, 64.  
 Bonwill, Gates-, 45.  
 Bonwill cap, 64.  
 Brown, 57.  
 Evans gold, 96.  
 Evans's pin and disk method, 114.  
 Farrar's cantilever, 123.  
 Fillebrown's, 172.  
 Foster, 49.  
 Gates-Bonwill, 45.  
 Hollingsworth, 285.  
 Howland-Perry, 50.  
 Kirk's method of mounting, 62, 139.  
 Lecch, 118.  
 Logan, 51.  
 Parker's, 94.  
 Parr, 117.  
 Patrick, 87.  
 Perry, 119.  
 Perry-Howland, 50.  
 Richmond, 74.  
 Rynear, 88.  
 Simplicity, Stowell's, 64.

- Crowns, Stowell's method of mounting, 64, 79.  
 Van Woert, 113.  
 White's, 62.  
 all-gold, in sections, 81, 278, 285.  
 attachments for all-gold and seamless gold, 40, 105, 106.  
 cementation, process of, 133.  
 contouring of crowns and collars, 81, 97, 98.  
 contraction of, 72, 103, 280.  
 dies for use in construction of, 79, 82, 84, 87, 91, 93, 94, 98, 108, 324.  
 expanding, 72, 101.  
 finishing and polishing, 133.  
 for abraded teeth, 89, 107, 127.  
 for separate molar roots, 123.  
 gold and porcelain, for teeth with living pulps, 107.  
 gold and porcelain, without a collar, 112.  
 gold collar, 59, 67, 278.  
 gold seamless cap, 90, 96.  
 gold seamless contour, 96.  
 mandrel system, 278.  
 partial, 125.  
 porcelain, with collar attachment, 59, 80, 119.  
 porcelain, with rubber attachment, 66.  
 preparation of crown or root for, 9, 36.  
 process of adjustment of gold contour, seamless, 99.  
 remarks on the use of collar or porcelain crowns, 58, 111.  
 removal of, 208.  
 repair of, 205.  
 shell, 167, 169, 170, 172, 191, 194.  
 Curtis removable bridge, 270.  
 Cusps of antagonizing teeth, preparation of, 39.
- DAVENPORT removable plate bridge-work, 239.
- Decayed roots, special preparation of for crown-work, 39.
- Dentine, circulation in, 10.  
 chemical analysis of, 12.
- Detachable bridge-work, 136, 138, 212, 243.
- Detachable porcelain front, 183.
- Devitalization of pulps, 10, 16.  
 by cataphoresis, 16.  
 heroic or instantaneous, 16.  
 instant, 16.  
 use of arsenic for, 17, 18.  
 use of cocain in, 16.
- Die-plate, 85.
- Dies, 59, 78, 82, 84, 91, 94, 98, 108, 125, 324.
- Dies, Dr. Melotte's method for forming, 324, 325.  
 counter, 82, 90, 94, 325.  
 fusible metal, 324, 325.
- Diseased pulps, classification of, requiring extirpation, 12.
- Diseased teeth or roots, badly, 9.  
 with necrosis of alveoli, 9.
- Disinfection of root-canals and dentine, 23, 24, 25, 26.
- Disks, forms of, 37.
- Drills, Gates-Glidden, form of and method of using, 22.
- Dummies, definition of, 153, 155.  
 how to form, 153, 154, 162, 164.  
 how to form of solid gold, 104, 162, 164.  
 how to form hollow, of gold, 164.  
 how to form in one continuous piece, 292, 294.
- Dwinelle's crown, 67.
- ENAMELING gold crowns, method of, 110.
- English bridge-work, 144.
- Evans gold crowns, 96.  
 method of constructing dummies in bridge-work, 154, 164.  
 non-fusible crown, 96.
- Excision of natural crown, 16, 38.  
 and instantaneous extirpation of the pulp, 16.  
 when to avoid, 12.
- Expansion of a collar or crown, 72, 101.
- Extension bar-bridge, 178, 299.
- Extension bridges, 170.  
 leverage in, 173.
- Extirpation of pulps, 16, 17, 18.
- FACING, porcelain, for gold crowns, 108, 291.
- Farrar's cantilever crown, 123.
- Ferrules for root-crowns, 59, 67, 123.
- Files for trimming roots or crowns, 37.
- Fillebrown's crown, 172.
- Filling of root-canals, 28.
- Finishing and polishing bridge-work, 133, 157.  
 crown-work, 133.
- Flange to better support a porcelain-faced gold crown, 90, 113.  
 to better support bridge-work, 174.
- Forceps for excising crowns, 17.  
 for removing crowns, 208.  
 for repairing, 205.
- Formulas for fusible metals, 324, 325.  
 for gold solders, 320.
- Foster crown, 49.
- Foundations for bridge-work, 148, 187.

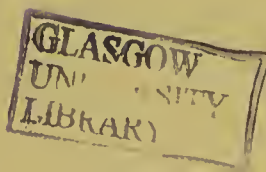
- Fracture of porcelain teeth in soldering, 323.
- Fractured teeth and roots, treatment of for crowning, 120.
- French bridge-work, 144.
- Fusible alloys of tin, 324, 325.  
Melotte's, 324, 325.
- GARTRELL bridge, 268.
- Gates-Bonwill crown, 45.
- Gold, all-, crowns for front teeth, 88, 108, 109.  
hollow dummies for bridges, 164.  
molar teeth, 81, 92, 96, 278, 285.  
solid, 104, 163.
- Gold cap-crown, to securely attach, 106.
- Gold collar crowns, 59, 67.  
preparing natural teeth for, 9, 36.
- Gold crown cutter, 208.
- Gold crown, repair of, 104, 209.
- Gold cusps for bridges in one continuous piece, 294.  
with porcelain front, 74, 77.
- Gold plate lined with platinum, 319.  
crown-metal, 68, 319.  
solder filings, 69, 103, 322.  
solders, formulas for, 320.  
standard of carat and gauge required, 68, 319.  
tips for natural crowns, method of constructing, 127.  
wire, 75, 320.
- Gold plates and solders, 319.
- Gold seamless contour crowns, 96.  
adjustment of, 99.
- Gutta-percha, 137.  
for forming molds of crowns or roots, 90, 324.  
in filling root-canals, 28.  
in preparation of roots, 40, 45.  
use of, for cementing crown- and bridge-work, 137, 159.
- HEAT, use of as a disinfectant, 13, 24.
- Hollingsworth's system of crown- and bridge-work, 285.
- Hollow all-gold dummies for bridges, 164.
- Hollow wire for posts, 75, 118.
- How screws, 47, 50.
- Howland-Perry crown, 50.
- Hub-mold, 86.
- Hygienic condition of the mouth as affected by bridge-work, 210.
- Hygienic consideration of collar crowns, 111.
- Hygienic preparation of the mouth, 6, 9.
- IMPRESSIONS of crowns or roots, 45, 56, 76, 81, 82, 90, 93, 324.  
cups for taking, 87, 158.  
for bridge-work, 150, 158, 160, 171, 187, 324.  
materials for taking, 90, 93, 150, 324.
- Impression and articulation combined, 150.
- Insertion and cementation of crown- and bridge-work, 135, 138, 159, 169.
- Instantaneous extirpation of the pulp, 16.  
knocking out of the pulp, 17.
- Instruments and appliances, 328.
- Investments for soldering, 326.  
in bridge-work, 152, 156, 326.  
in crown-work, 76, 116, 326.
- Iodoform, methods of using, 29.
- Iridio-platinum wire for posts, 320.
- Irregularities of the teeth, methods of crowning in, 124.
- Isinglass (mica), use of in crown- and bridge-work, 78, 154.
- KINGSLEY'S method of forming all-gold crowns, 83.
- Kirk's method, 62, 139.
- Knapp's methods in crown- and bridge-work, 273.
- LAND'S method in partial porcelain crown-work, 131.
- Lead counter-dies, method of forming, 84, 91, 94, 324.
- Leech's crown, 118.
- Leverage in bridge-work, 146, 148, 172, 174, 187, 197.  
in extensive bridge-work, 172, 197.
- Litch's method of crowning, 92.  
detachable bridge, 246.  
partial cap and pin bridge, 193.
- Logan crown, 51.  
method of mounting with band and cap, 60.  
Dr. Baldwin's method of mounting, 64.
- Low's replaceable porcelain fronts, 185.
- MANDREL system, 278.
- Mandrels for forming collars, 71, 279.
- Materials and processes used in crown- and bridge-work, 319.  
molds and dies, 324.  
porcelain teeth, 323.  
soldering, 326.
- Measuring the size of necks of crowns or roots for collars, 70, 282.  
natural crowns or roots for ready-made gold crowns, 99.

- Melotte's method, 151.  
 metal, 324, 325.  
 method of making model and articulation in constructing bridge-work, 151.  
 moldine, 324.
- Metal flange to support crown, 92, 113.
- Metallic dies and counter-dies, 324.
- Metallic dies for forming caps with cusps for crowns, 84.
- Models for bridge-work, 150.
- Molar roots decayed apart, method of crowning, 123.
- Moldine, 324.
- Molding, methods and materials used in, 82, 91, 94.
- Molds and dies, 324.
- Morrison's crown, 67.
- Mouth, preparation of, 6, 9.
- NECKS of teeth, average forms of, 20, 69.  
 methods of measuring, 70, 282.
- OBJECTIONS urged against bridge-work, 145.  
 against collar crowns, 111.  
 against porcelain crowns, 58.
- Obtundents, use of in alveolar abscess, 33, 35.  
 use of in crown-work, 73.  
 use of in extirpation of pulp, 16.
- Ottolengui root-reamers and facers, 53.
- Oxyphosphate cement, 133.  
 properties suitable for crown-work, 134.  
 to cause to set slow, 135.
- PARKER gold crown, 94.
- Parr's crown, 117.
- Parr's detachable and removable bridge-work, 254.
- Partial crowns, gold, 125.  
 Dr. Land's method, 131.  
 Dr. Littig's method, 252.  
 Dr. Parr's method, 127.  
 porcelain, 128, 131.
- Patrick's cap-stamping machine, 98.  
 crown-work, 87.  
 formula for gold for collars, 319.
- Perforation of side of root, treatment of, 122.
- Perry's crown, 119.
- Pin to attach gold crown, 40, 106.
- Pin-bridge, partial cap and, 180, 193.
- Plaster impression and articulation, method of taking, 150, 160, 171, 187, 325.
- Plate and solders, 319.
- Plate bridge, 230.  
 removable, 230, 259.
- Platinum plate, 320.  
 advantages in crown-work, 68, 75, 110, 113, 114, 153.  
 wire, 320.  
 with gold, 110, 319.
- Pliers for shaping collars, 68.
- Polishing and finishing crown- and bridge-work, 77, 133, 157.
- Porcelain crowns, 44.  
 Brown, 50.  
 Foster, 49.  
 Gates-Bonwill, 45.  
 Howland-Perry, 50.  
 Logan, 50.  
 method to facilitate the adaptation of to the root, 45, 56.  
 remarks on the use of, 58.
- Porcelain and gold crown without a collar, 112.
- Porcelain bridge-work, 295.  
 criticism of, 295, 304.
- Porcelain crown with gold collar attachment, 59, 80, 119.  
 with rubber or vulcanite attachment, 66.
- Porcelain faces for crowns, 75, 79, 107, 109, 110, 116, 291.
- Porcelain fronts, backing for, 75, 116, 153.
- Porcelain teeth, selection of, 323.  
 some causes of fracture in soldering, 323.
- Porcelain tips to natural crowns, 129.
- Posts for retaining crowns, 40, 47, 49, 50, 76, 105, 106, 113, 114, 118, 320.
- Pouring fusible alloy or metal, manner of, 82, 91, 325.
- Preparation of natural crowns or roots for gold crown-work, 38.  
 for Logan crown, 51.  
 for porcelain crowns, 38, 45.
- Preparation, special, of badly decayed teeth and roots, 39.
- Preparatory treatment of the mouth, 6, 9.
- Pulp, capping of, 13.  
 diseases of requiring extirpation, 12.  
 instantaneous devitalization, with excision of crown, 16.  
 lesions of, 12.  
 preservation or devitalization, 10.  
 use of arsenic in devitalization of, 17, 18.
- Pulpless teeth, their treatment and disinfection, 21.
- Punch forceps for riveting, for use in repairing bridge-work, 205.
- Pyorrhoea alveolaris, bridge-work in cases of, 188.  
 collar crowns in cases of, 111.

- READY-MADE crowns, the Evans, 96.  
the Rynear, 88.
- Reaming of root-canals, 22.
- Removable and replaceable porcelain  
fronts, 183.
- Removable bar-bridges, 267.
- Removable or detachable bridge-work,  
212.  
Dr. Curtis's method, 270.  
Dr. Litch's, 247.  
Dr. Morey's, 267.  
Dr. Parr's, 254.  
Dr. A. S. Richmond's, 225.  
Dr. Starr's, 248.  
Dr. Waters's, 260.  
Dr. Winder's, 243.  
connecting bars for, 221, 258.  
methods of forming attachments  
for, 213.
- Removable crowns and attachments  
for bridge-work, 212, 213, 231, 238, 243,  
267, 311, 313.
- Removable plate bridges, 230.  
Dr. Bonwill, 264.  
Dr. J. L. Davenport, 241.  
Dr. Parr's methods, 259.  
Dr. Waters's methods, 261.
- Removal of crown- and bridge-work,  
208.
- Repair of crown- or bridge-work, 205.  
Dr. Bryant's method, 207.  
Dr. Starr's method, 206.  
Dr. Williamson's method, 206.
- Repair of gold crowns, 104, 209.
- Retaining-pin for all-gold crown, 40,  
106.
- Richmond crown, the original form of,  
introduced, 74.
- Root, method of filling, 28.  
method of treatment, 21.
- Root-canal, antiseptic agents for  
treatment of, 25.
- Root-drier, 25.
- Root-reamers and facers, Ottolengui's,  
53.
- Root-trimmers, 37.  
Starr's, 252.
- Roots intervening between abutments,  
167.  
special preparation of badly de-  
cayed, 46.
- Rubber or vulcanite attachment for  
crown, 66.
- Rules governing the insertion of  
bridge-work, 148, 172, 174, 187.
- Rynear's crown, 88.
- SCREWS to support crowns, 40, 47, 49,  
50, 65, 105.
- Seamless gold collars, 281.
- Seamless gold crowns, 88, 93, 96.  
method of contouring, 96.  
method of forming from an impres-  
sion, 93.  
process of adjustment and insertion,  
99.
- Self-cleansing spaces, 153, 154.
- Sensitive dentine, treatment of, 13, 38.
- Shapes of necks of teeth, 69.
- Shaping teeth and roots for crowning,  
process of, 36.
- Shell anchorage or crown, 167.  
seamless, 168.  
how to cement, 169.
- Shoulders on the anterior teeth, 89, 162,  
308.
- Slots for anchorage bars, 150, 163, 164,  
174, 176, 178, 181, 195, 300, 304, 308.
- Solder, gold, formulas for, 320.  
Dr. Dorrance's, 321.  
Dr. Litch's, 321.  
Dr. Low's, 321.  
Dr. Richmond's, 321.
- Soldering, manner of, 76, 78, 80, 82, 84,  
88, 103, 116, 326.  
investments for, 335.
- Solid gold crowns, 104, 163.
- Special forms and methods in crown-  
and bridge-work, 112, 162, 184, 243,  
267, 279.  
Dr. Alexander's, 184.  
Dr. Bonwill's, 264.  
Dr. Curtis's, 270.  
Dr. Knapp's, 273.  
Dr. Litch's, 246.  
Dr. Morey's, 260.  
Dr. Parr's, 254.  
Dr. Spencer's, 245.  
Dr. Starr's, 248.  
Dr. Waters's, 260.  
Dr. Winder's, 243.  
mandrel system, 278.
- Special preparation of badly decayed  
teeth or roots, 46.
- Spencer's method of removable bridge-  
work, 245.
- Spur support in bridge-work, 174.
- Stamping press for caps, 98.
- Starr's method of detachable bridge-  
work, 248.  
root-trimmers, 252.
- Sterilization of root-canals, 23.
- Stowell's porcelain gold collar crowns,  
80.  
Simplicity crown, 64.
- Strengthening gold seamless crowns,  
103.
- Sulfuric acid, care in the use of, 34.
- Syringes, hot-air, 24.  
abscess, 32.



- TABLE of fusible alloys, 324, 325.  
 Teeth, porcelain, 323.  
 Temporary attachment of bridge-work, 138, 159.  
 Thickness of plate suitable in crown-work, 68, 319.  
 Tin, alloys of, 324, 325.  
 Tips, porcelain or gold, for natural crowns, 127, 129.  
 Townsend's fusible die for forming collars for porcelain crowns, 59.  
 Treatment of chronic alveolar abscess, 31.  
     preparatory, of the mouth, 9.  
 Trimmers, root-, 37, 252.  
     Starr's, 252.  
 Trying in bridge-work, 159.
- VAN WOERT'S crown, 113.
- WARPING of bridge-work in soldering, 158.  
 Waters's removable bridge-work, 260.  
 Wheels for shaping natural crowns and roots for crown- and bridge-work, 36.  
 White's method in crown-work, 62.  
 Winder's detachable bridge-work, 243.  
     Dr. Spencer's method in, 245.  
 Wire for posts or pivots, 40, 46, 50, 105, 106.
- ZINC oxychlorid, use of, 40.  
 oxyphosphate of, 133.













GLASGOW  
UNIVERSITY  
LIBRARY

